

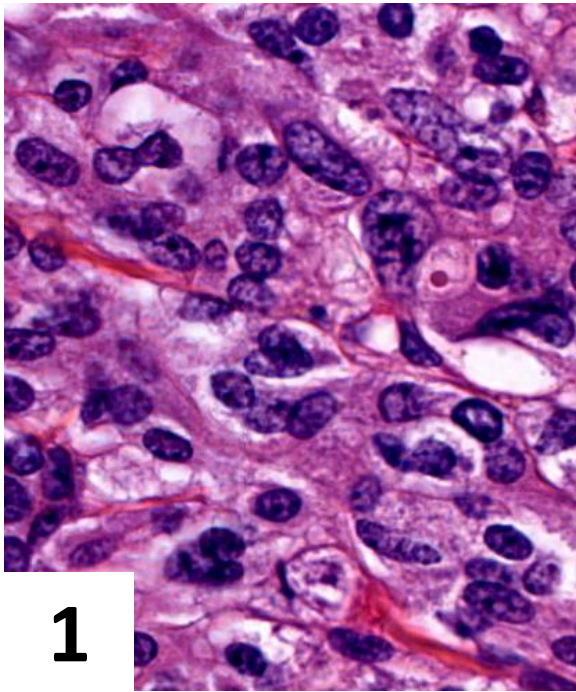
Carrefour Pathologie 2019

Symposium – Pathologie thyroïdienne Pièges diagnostiques

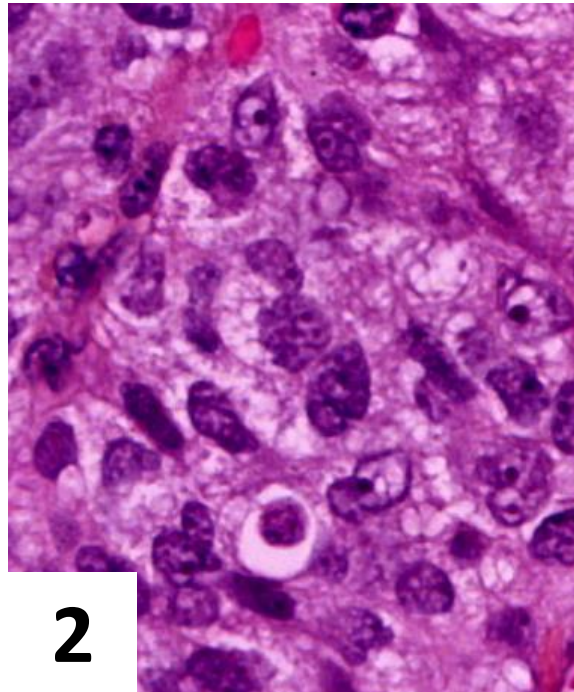
Emmanuelle Leteurtre, Lille



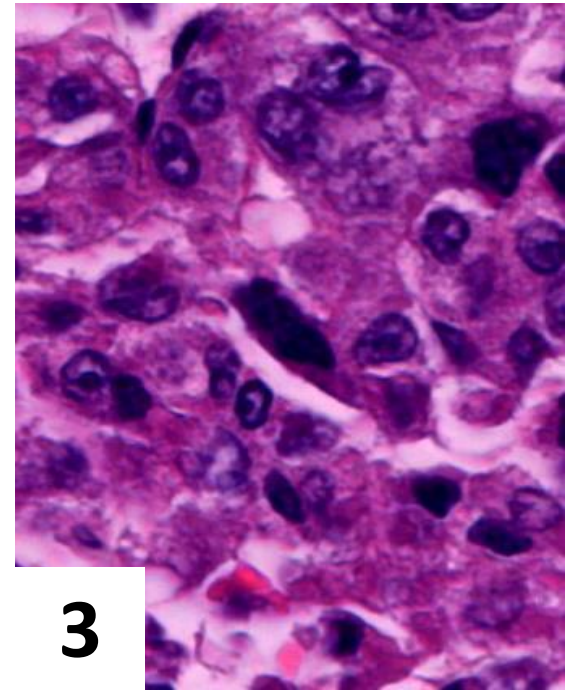
Pas de liens/ conflits d'intérêt



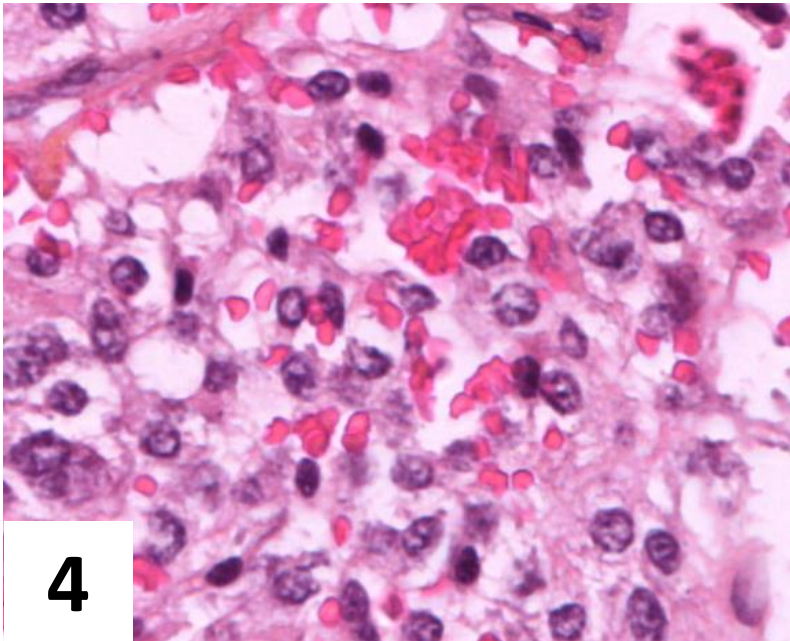
1



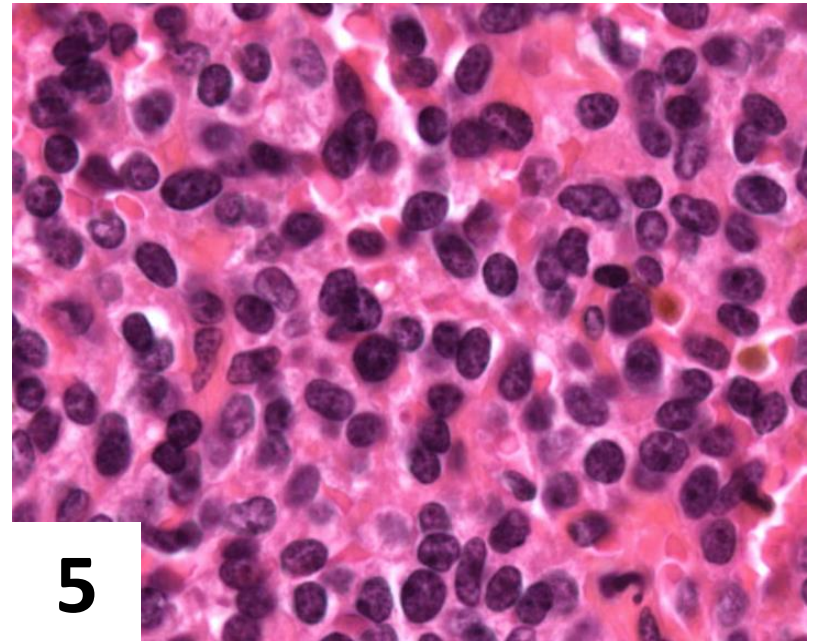
2



3



4

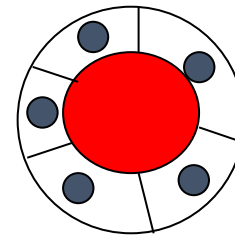


5

La majorité des tumeurs thyroïdiennes sont des tumeurs de souche folliculaire (95%)

Question : s'agit il d'une tumeur de souche folliculaire ?

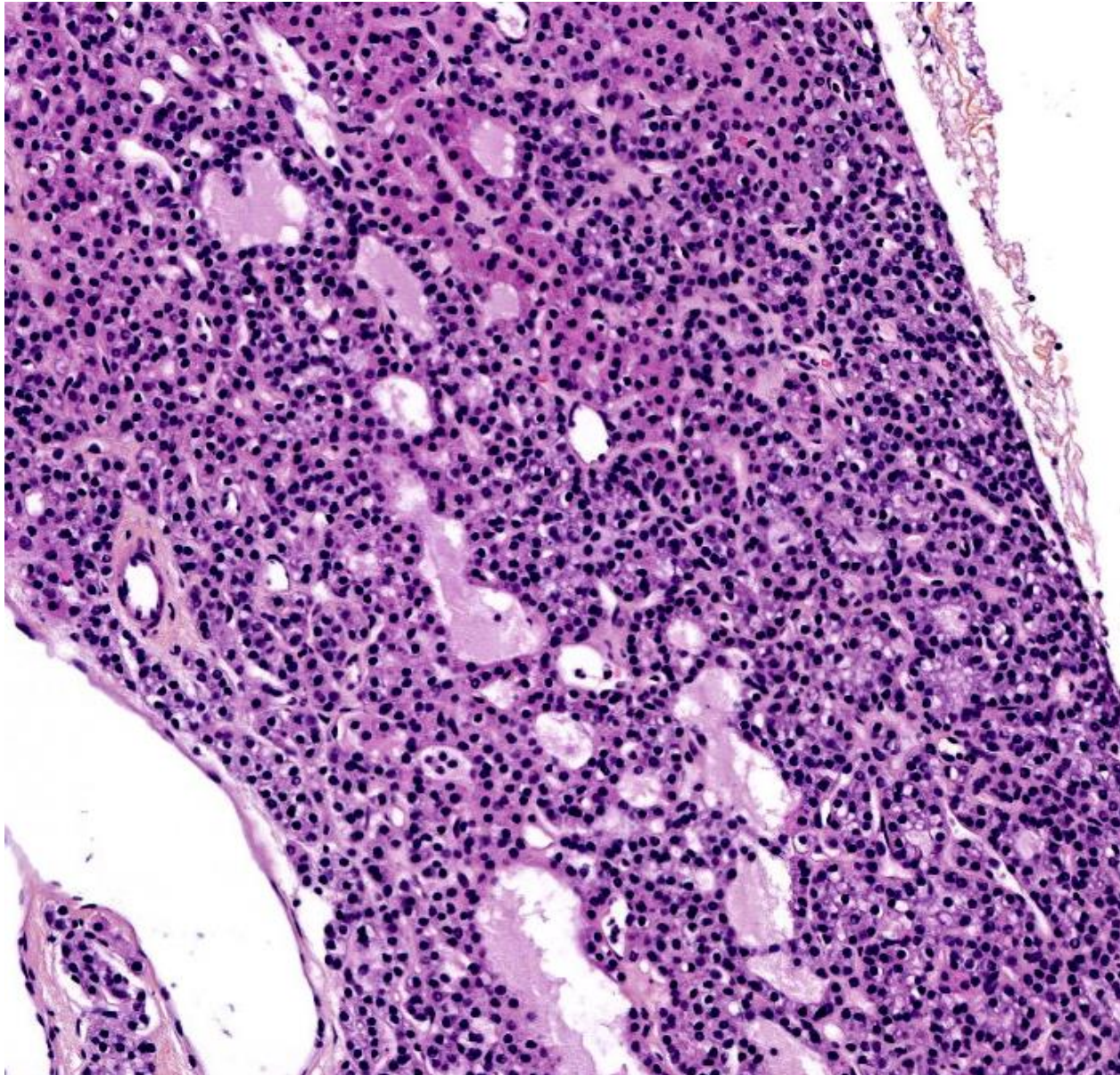
HES :architecture folliculaire avec production de colloïde

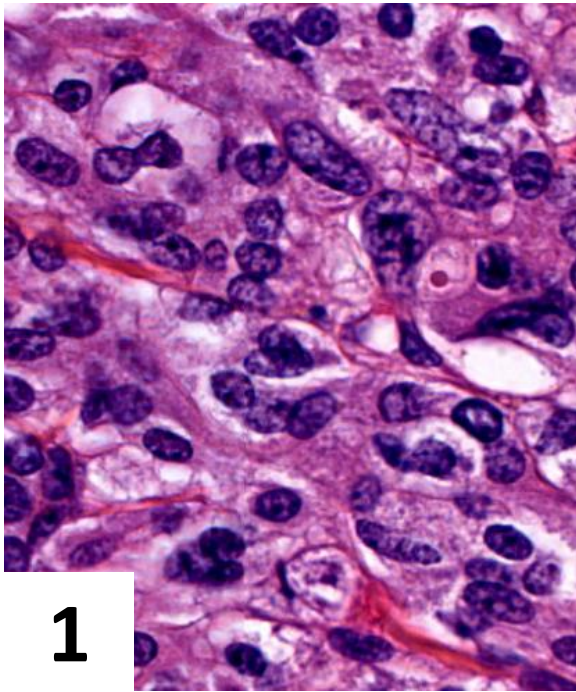


Immunohistochimie:

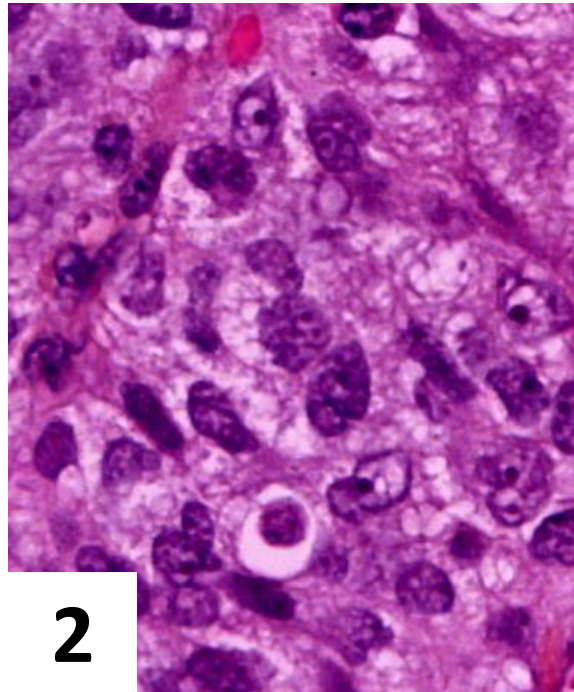
Trois anticorps clés: thyroglobuline, TTF1 et PAX8

Tissu parathyroïdien avec aspect pseudo-colloïde

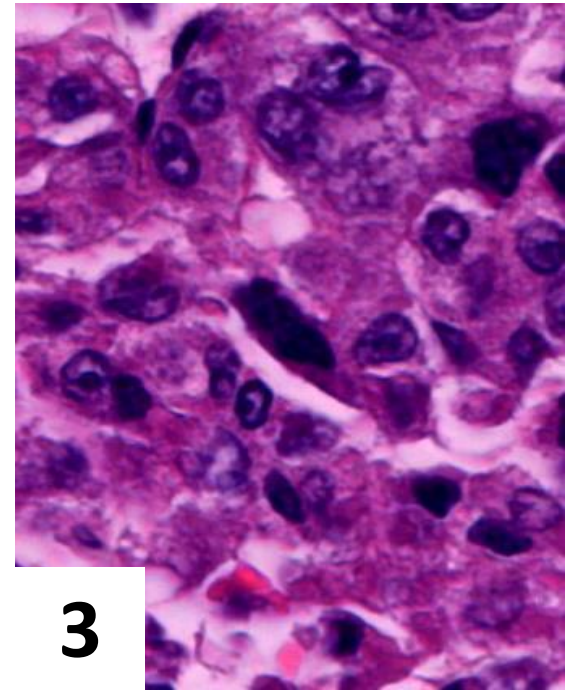




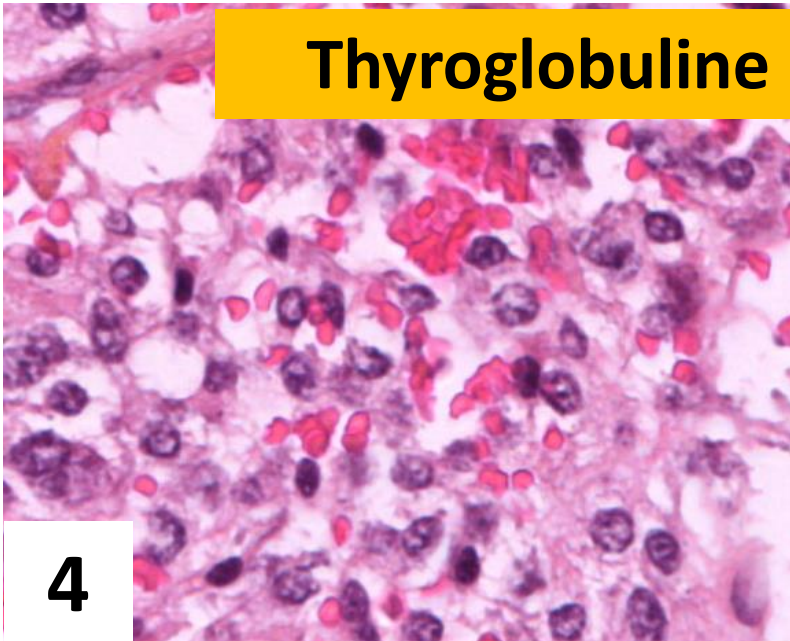
1



2

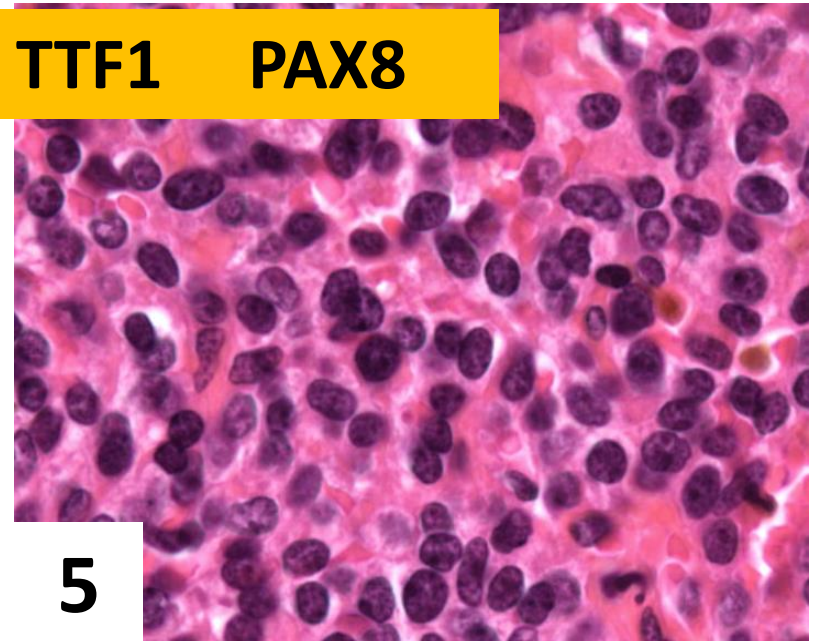


3



4

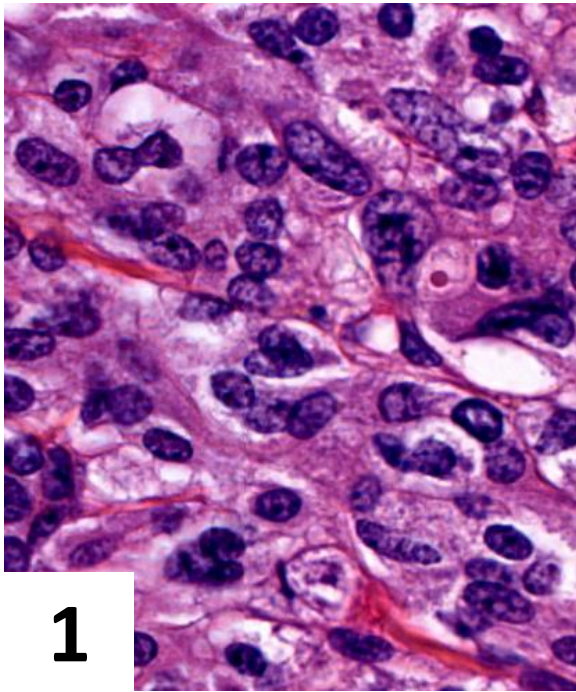
Thyroglobuline



5

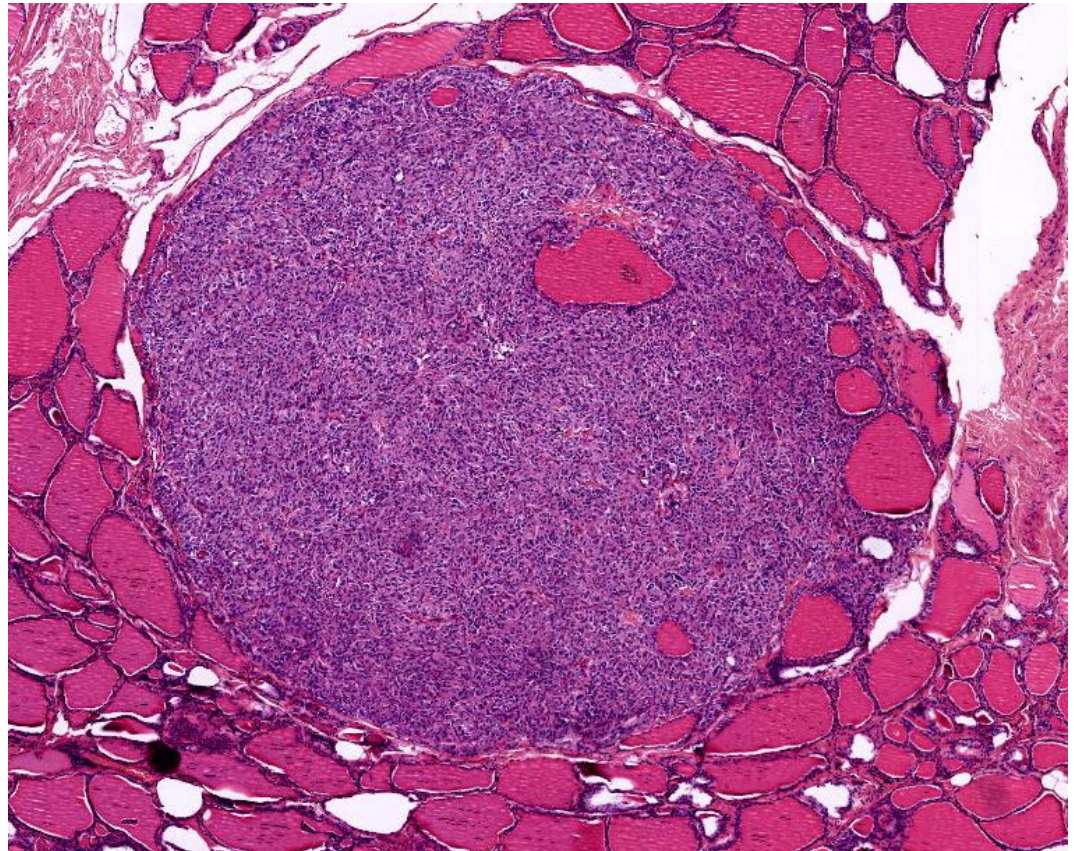
TTF1

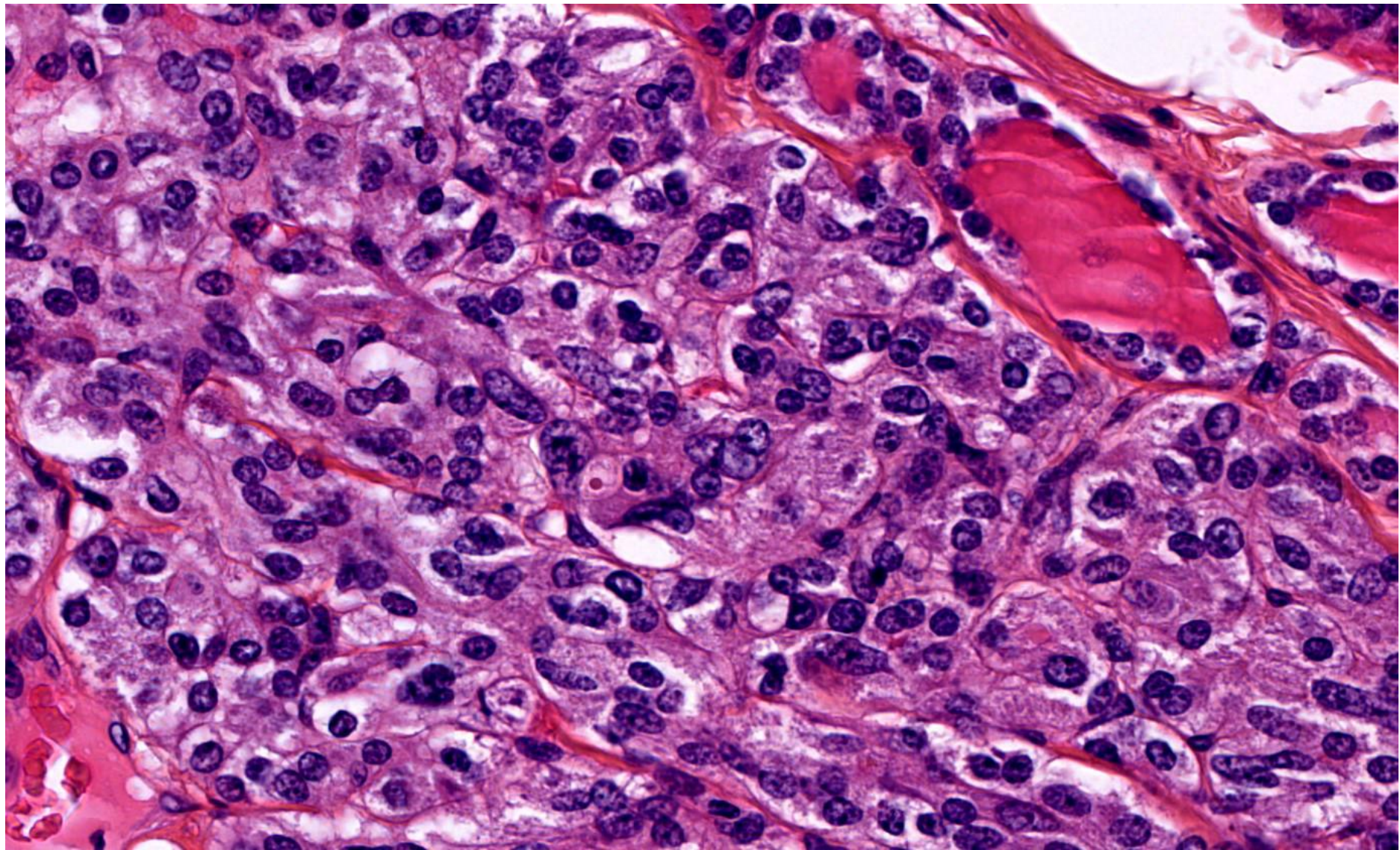
PAX8



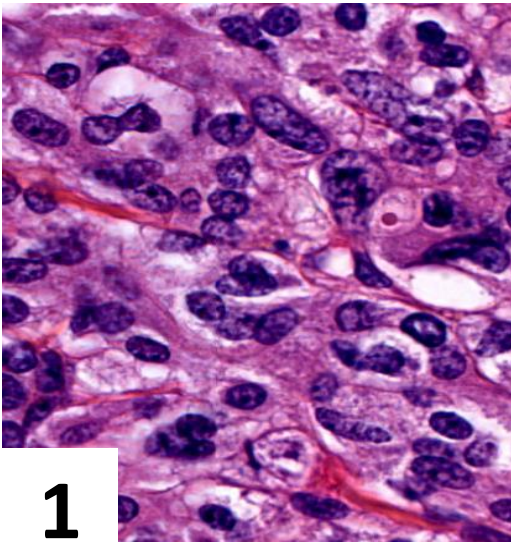
1

Patiente de 50 ans
Un micronodule de 2,5 mm à droite
Un autre nodule de 1,5 cm à gauche





Anticorps	Chromo	Synapto	Calcito	MIB1
Résultat	+	+	+	1%



1

Carcinome médullaire de la thyroïde

< 2-3% des cancers de la thyroïde

Taille variable: de 0,1 cm à plusieurs cm

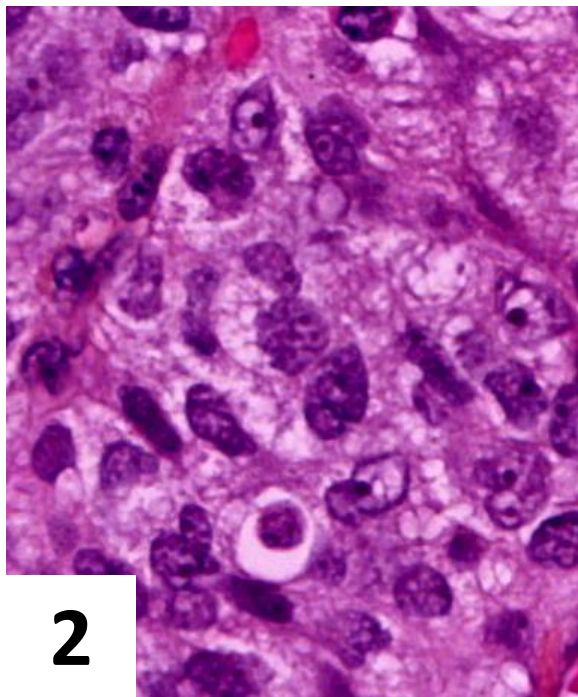
Localisation habituelle: jonction tiers moyen et tiers supérieur du lobe thyroïdien

Découverte fortuite

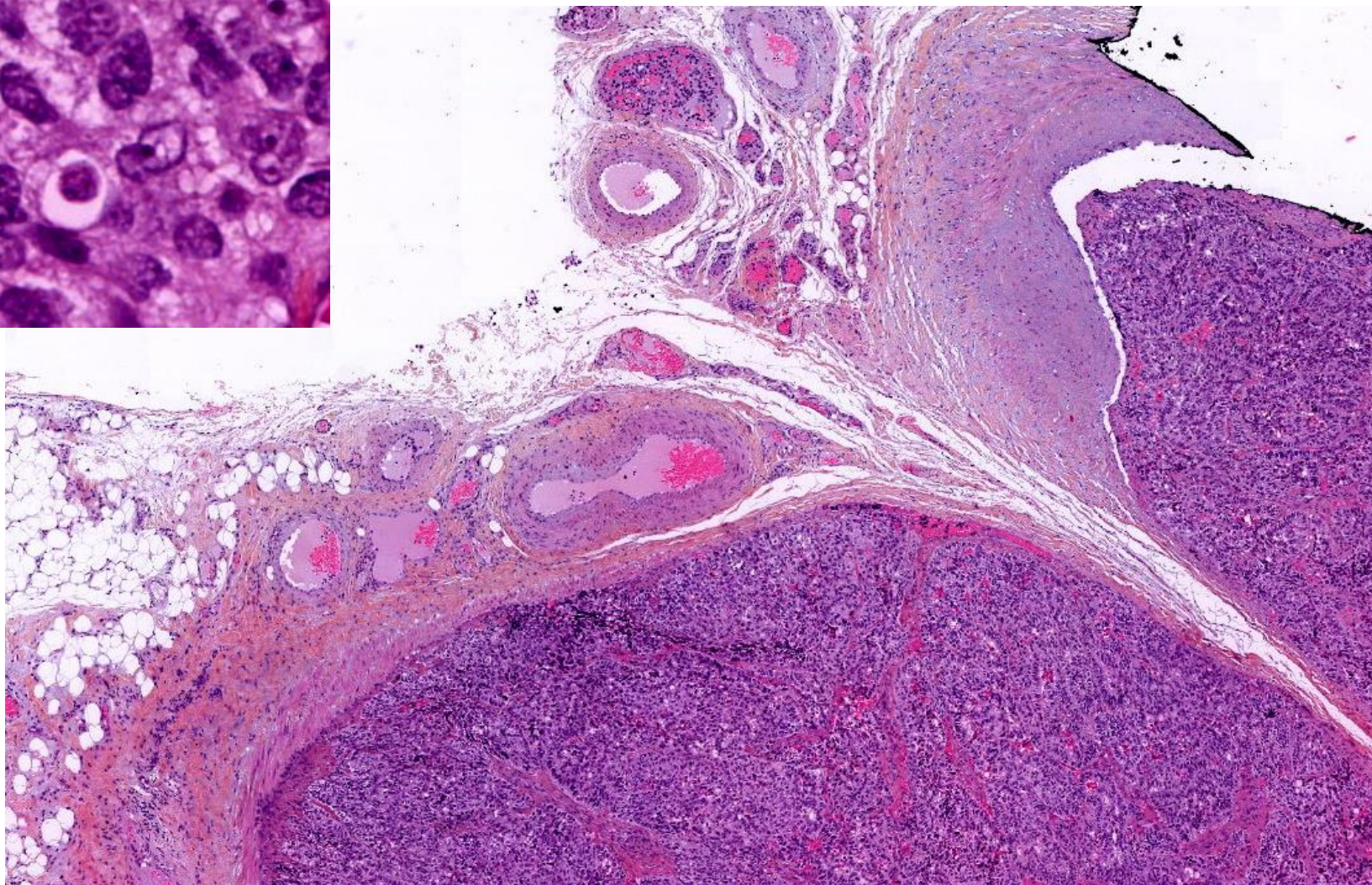
Profil IHC classique :

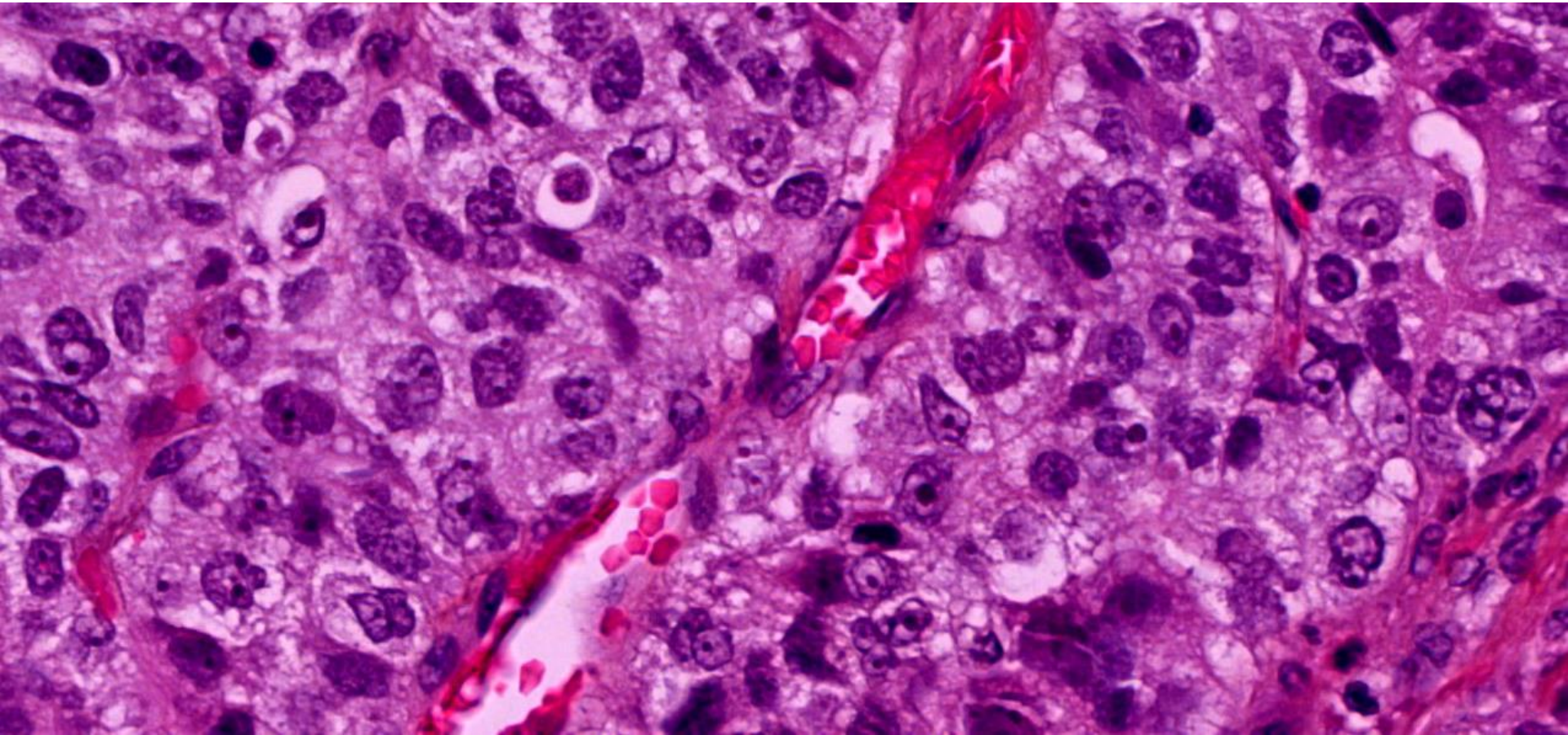
- chromo + synapto+ calcitonine + CK+**
- TTF1 + PAX8+/- TG-**

Patient de 54 ans



2



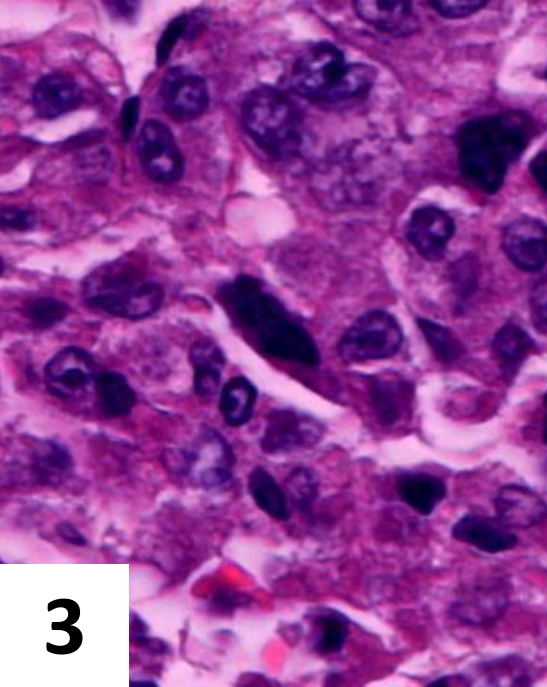


Anticorps	TG	TTF1	PAX8	Chromo	Synapto	Calcito	MIB1	CKAE1
Résultat	-	-	-	+	+	-	50%	+

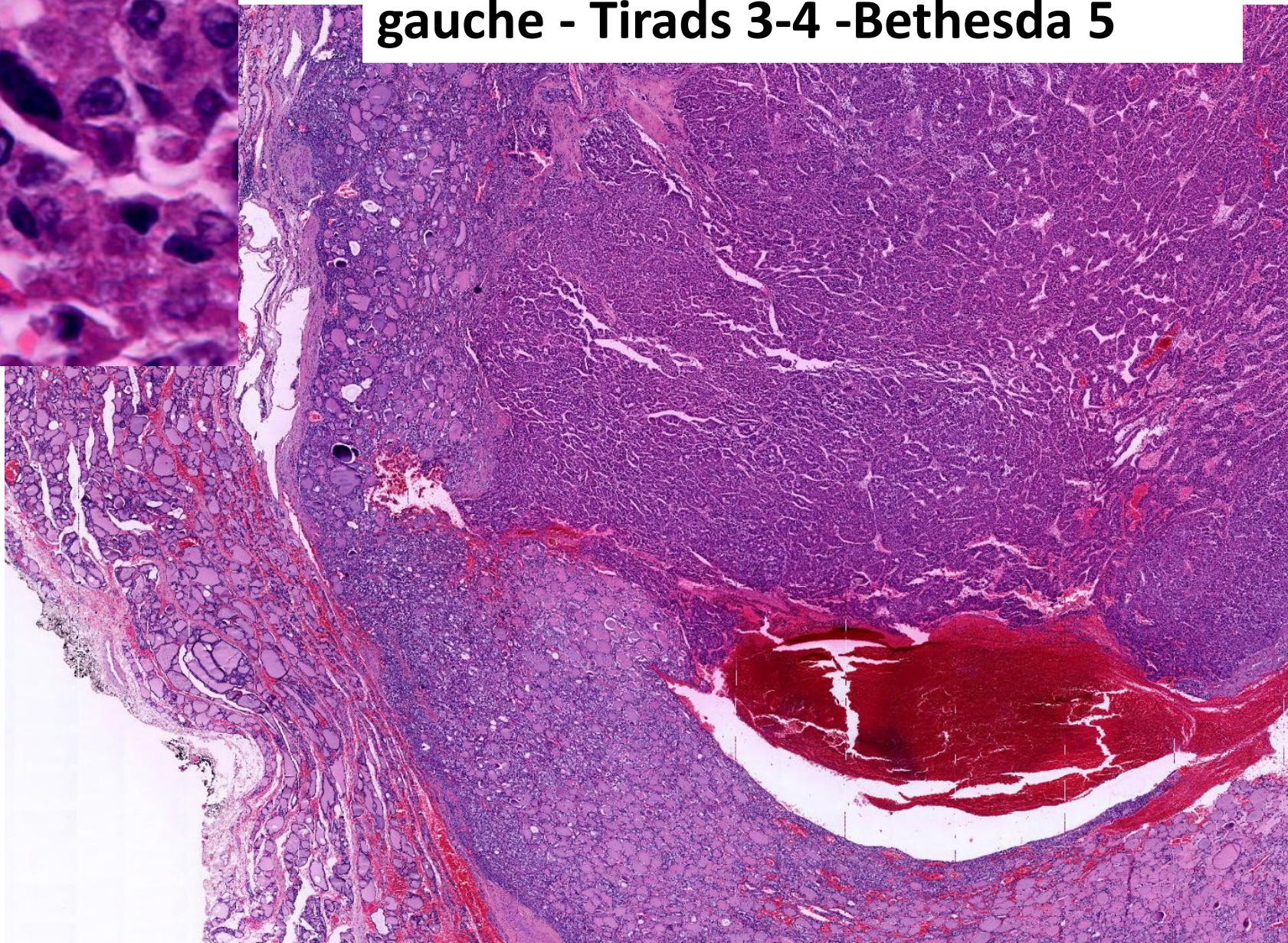
Patient de 54 ans

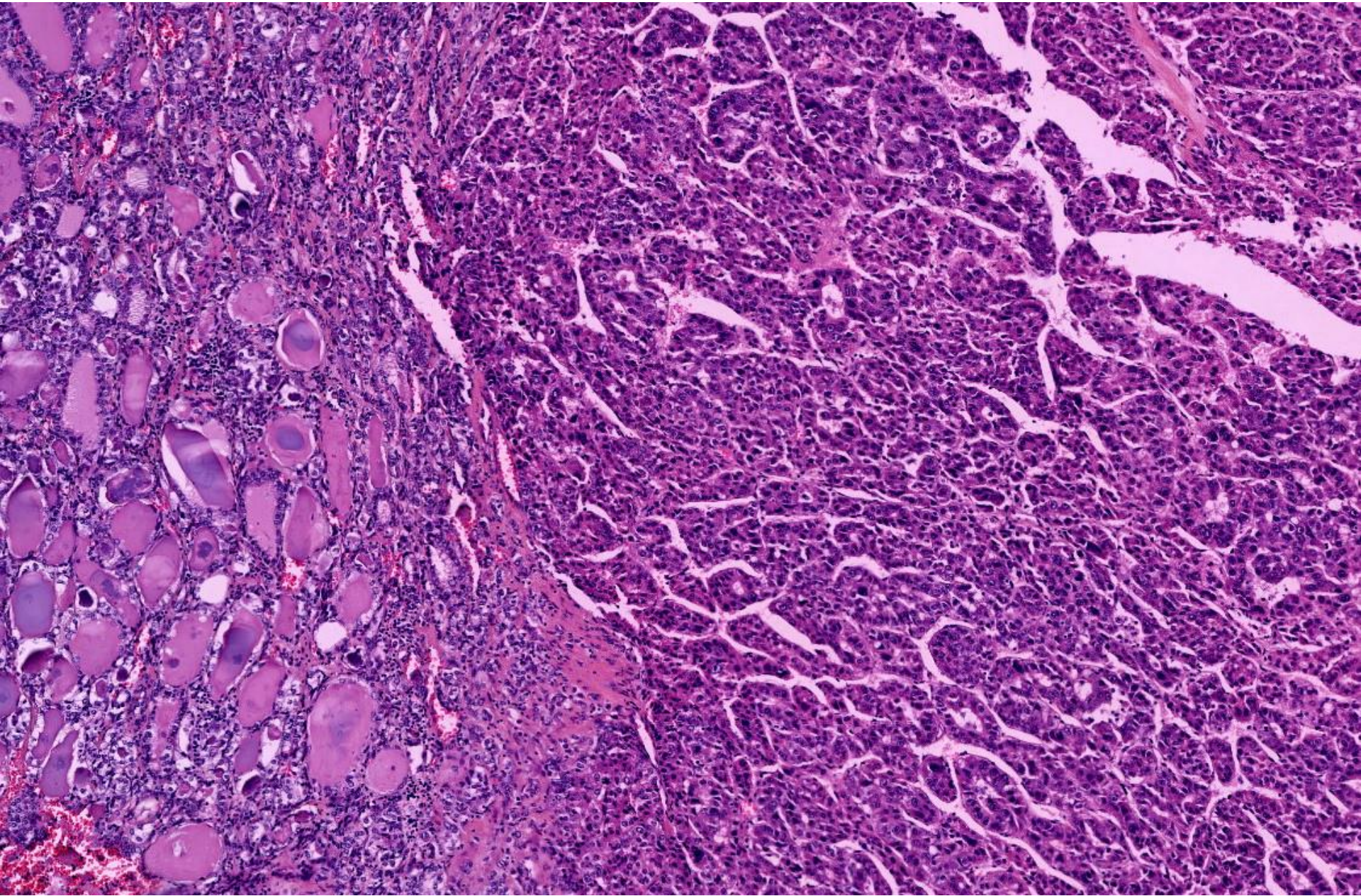
ATCD de néoplasie pulmonaire traitée par chimiothérapie

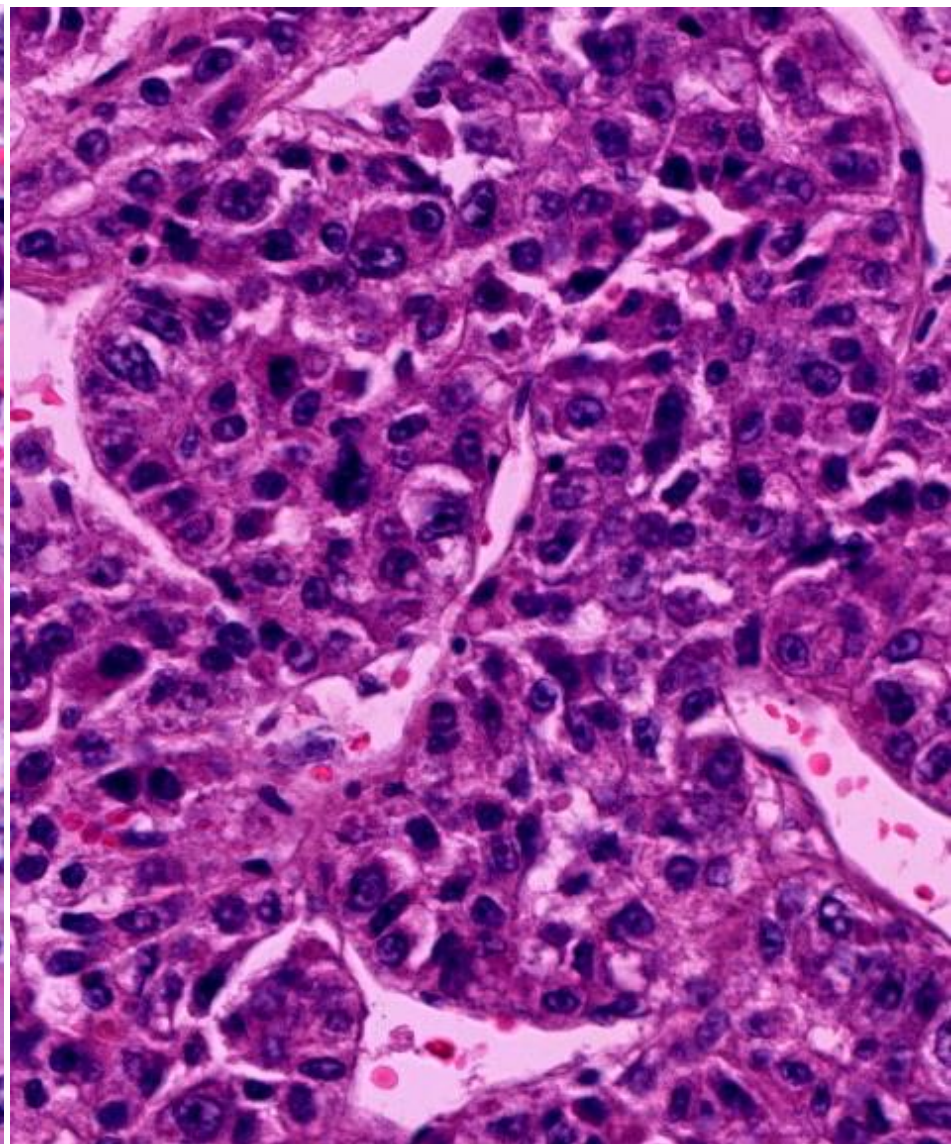
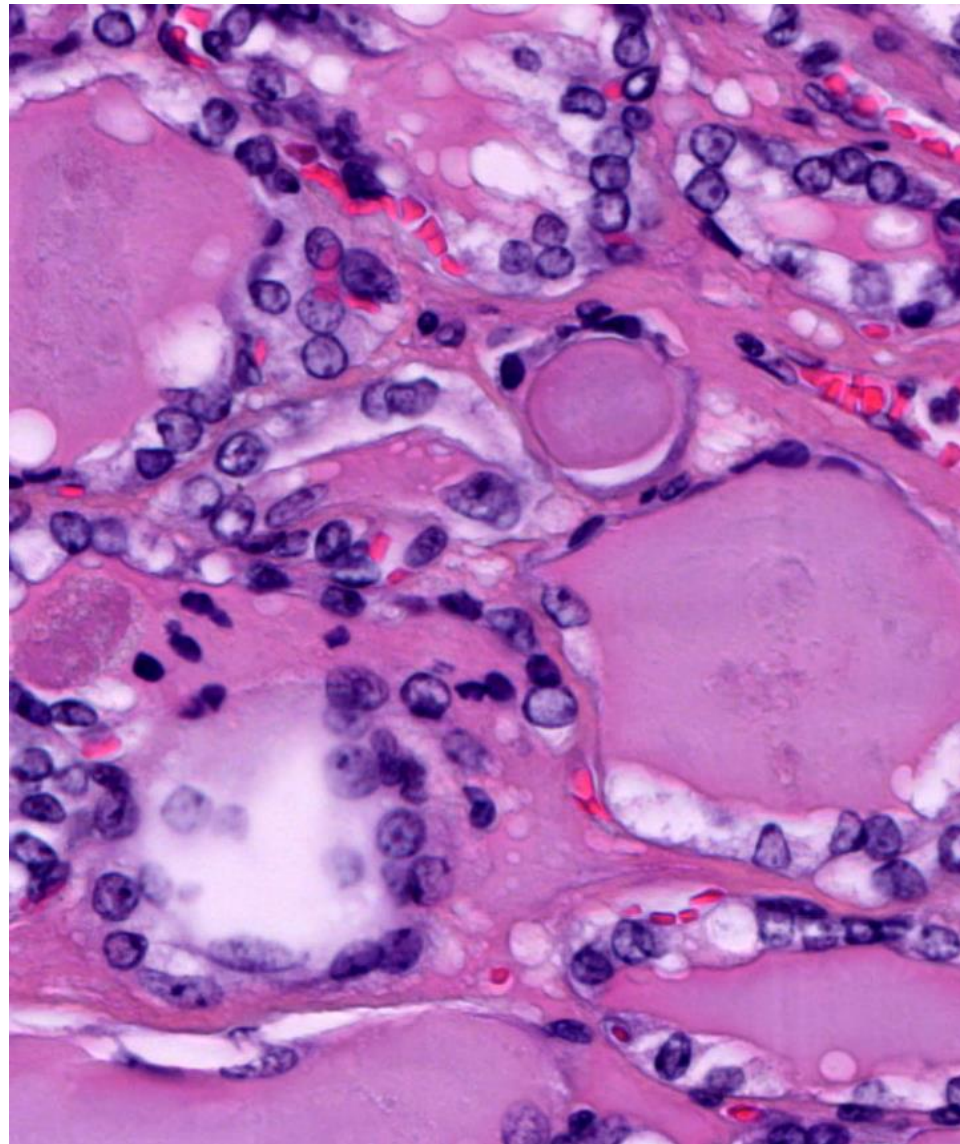
Patiente de 57 ans
Nodule thyroïdien totolobaire
gauche - Tirads 3-4 -Bethesda 5

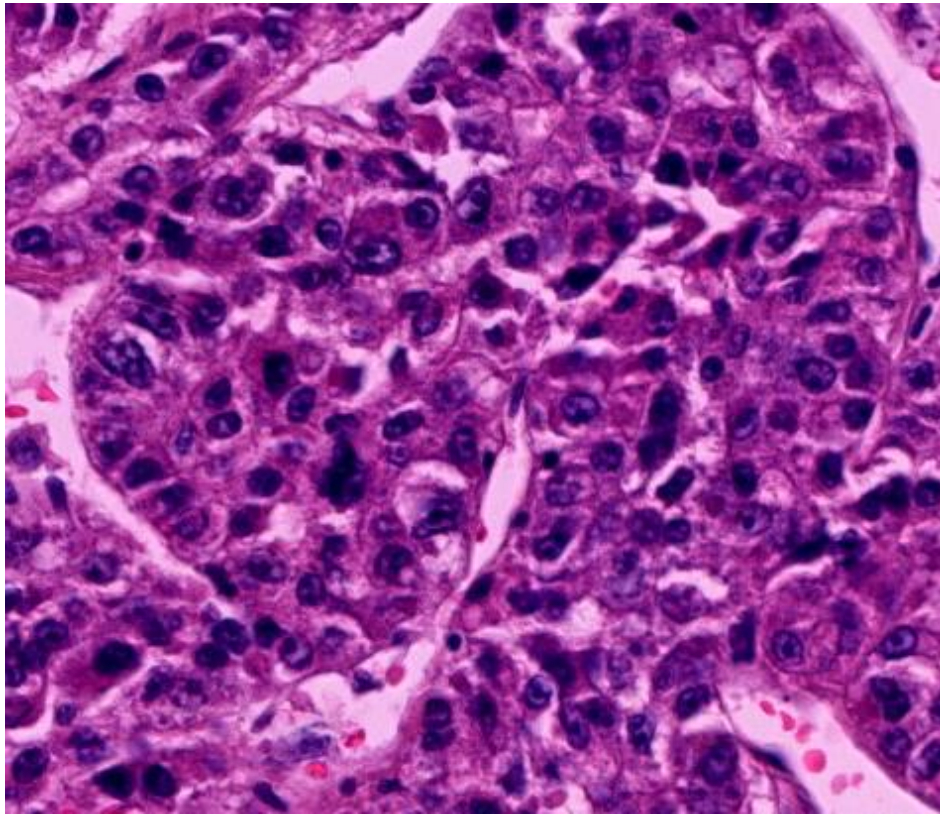


3







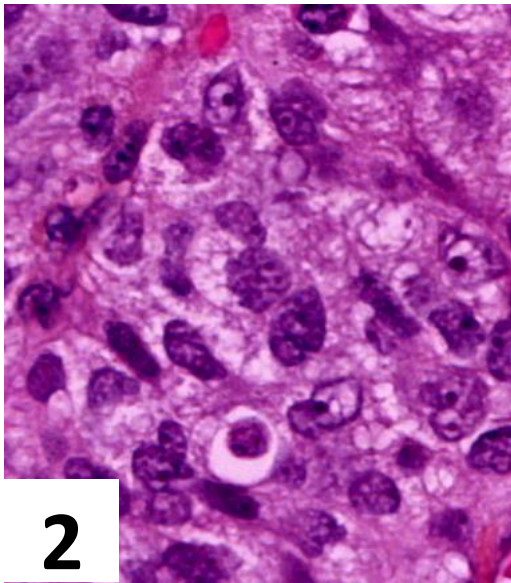


**Patiente de 57 ans
En attente de transplantation
hépatique**

**Carcinome hépatocellulaire
plurifocal sur cirrhose**

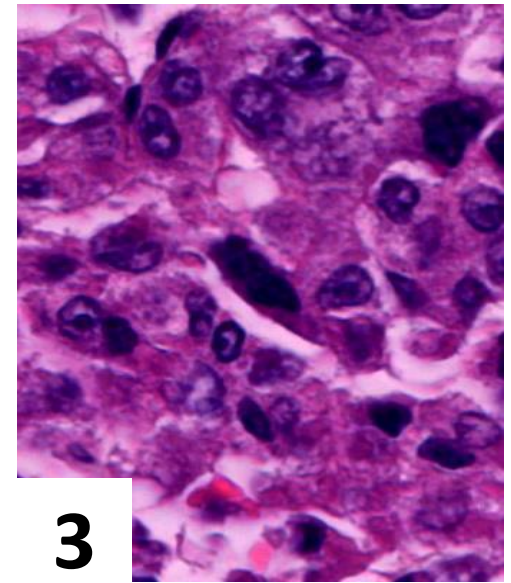
Anticorps	TG	TTF1	Chromo	Glypican	Hépto	ACE	MIB1	CKAE1
Résultat	-	-	-	+	+	+	20%	-

**Métastase thyroïdienne de carcinome hépatocellulaire
au sein d'un carcinome papillaire angioinvasif**



2

Métastases thyroïdiennes



3

Fréquence: <0,2% - 1,4% des cancers de la thyroïde
Survie prolongée des patients cancéreux. TEP +
Délai de survenue parfois long (20 ans)
Parfois « nodule dans un nodule »

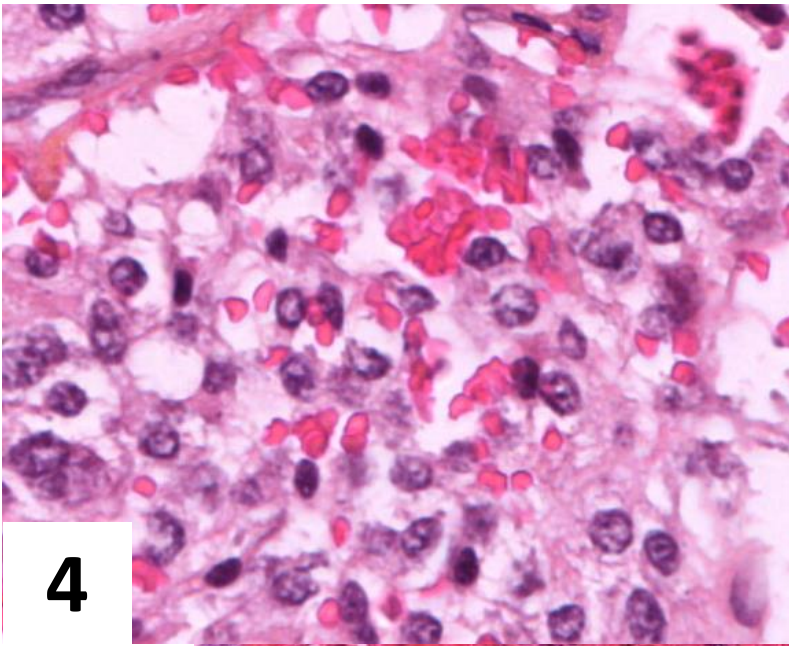
- **Carcinome à cellules claires du rein**
- **Adénocarcinome du poumon**
- **Adénocarcinome du sein**
- **Adénocarcinome du colon etc....**

Head Neck Pathol. 2019 Oct 17

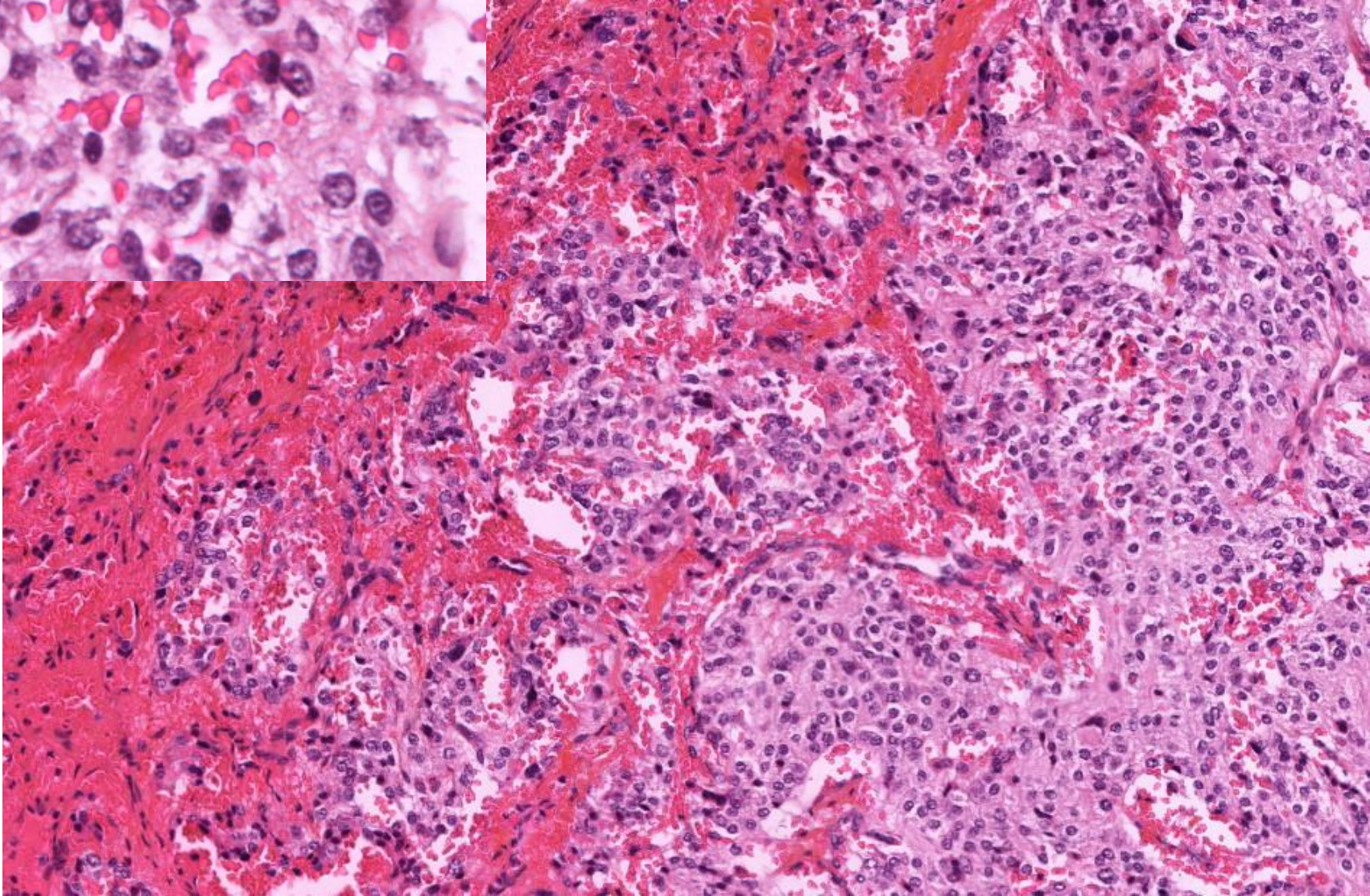
Colon Cancer Metastasis Within a NIFTP: A Case Report and Review of the Literature.

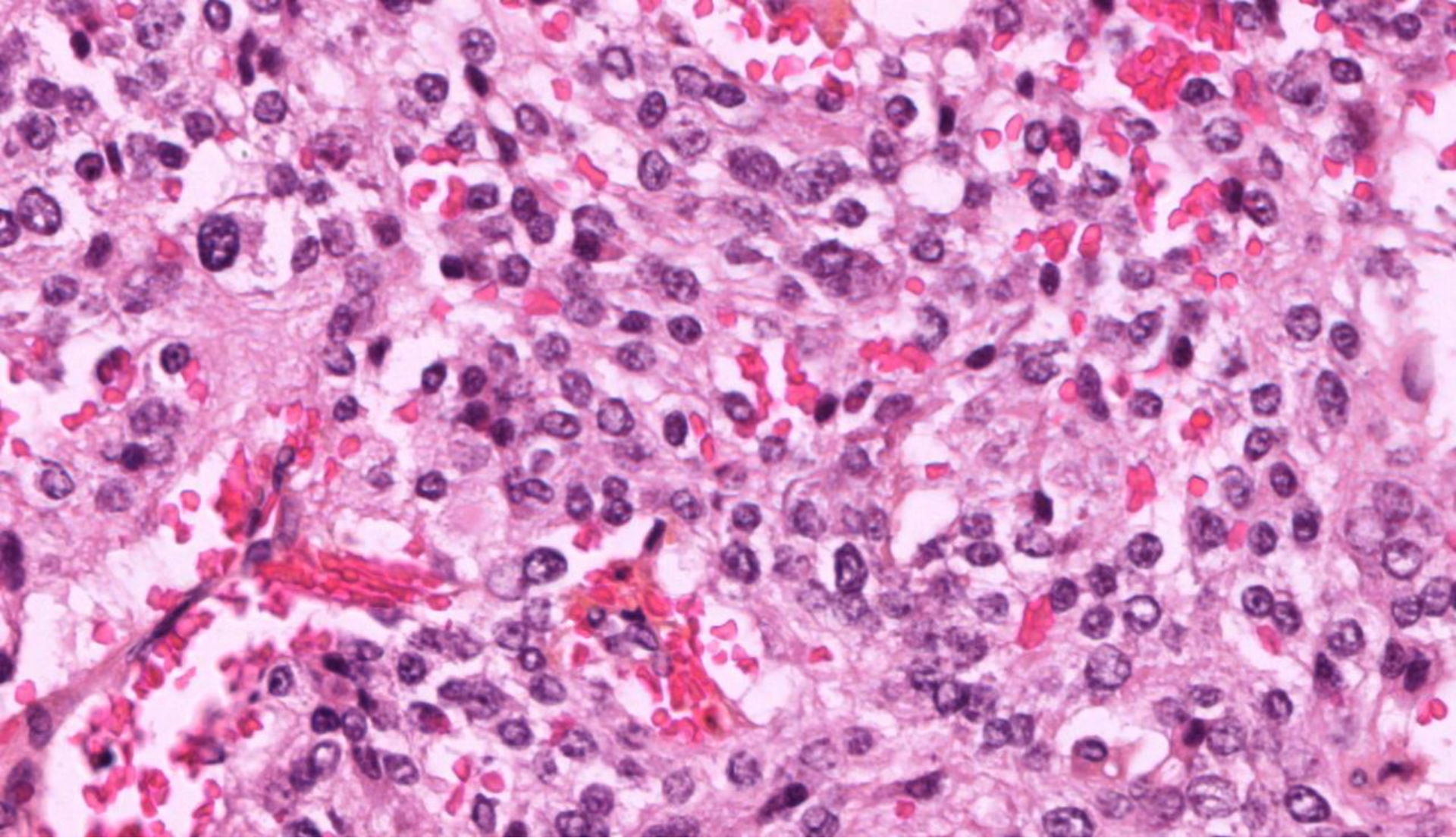
Al Battal M¹, Kanaan C², Labaid N¹, Breuskin I³, Leboulleux S⁴, Soufan R¹, Scoazec JY¹, Al Ghuzlan A¹.

Patiente de 47 ans
Tumeur lobaire thyroïdienne
gauche de 4 cm

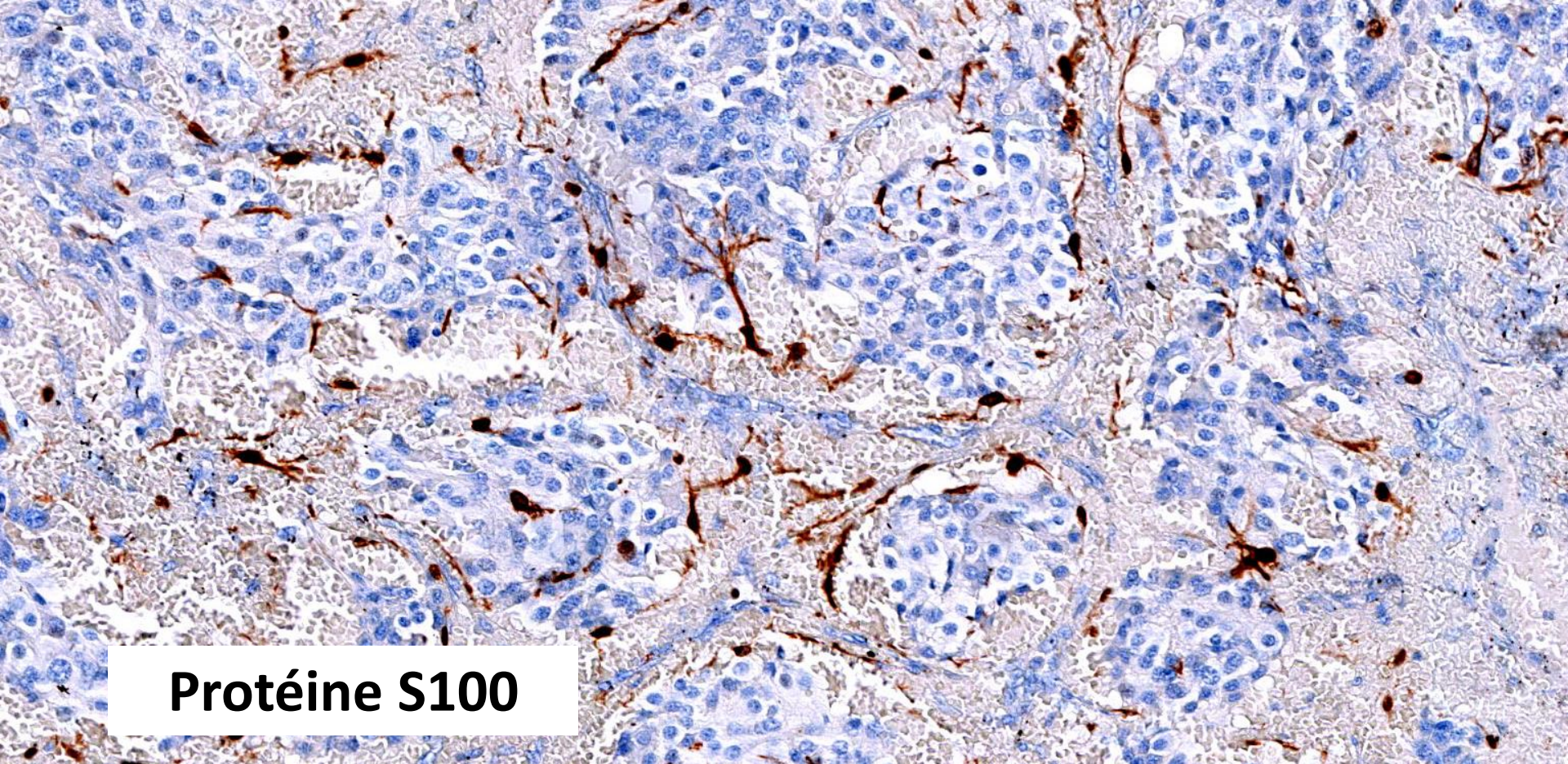


4

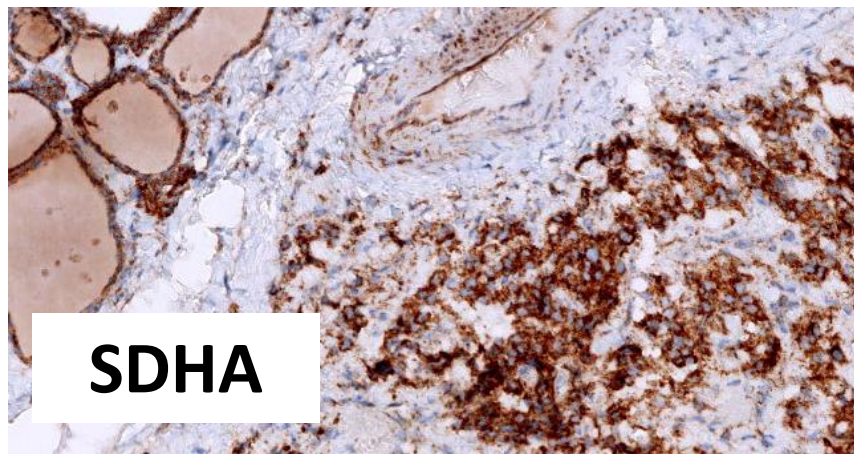




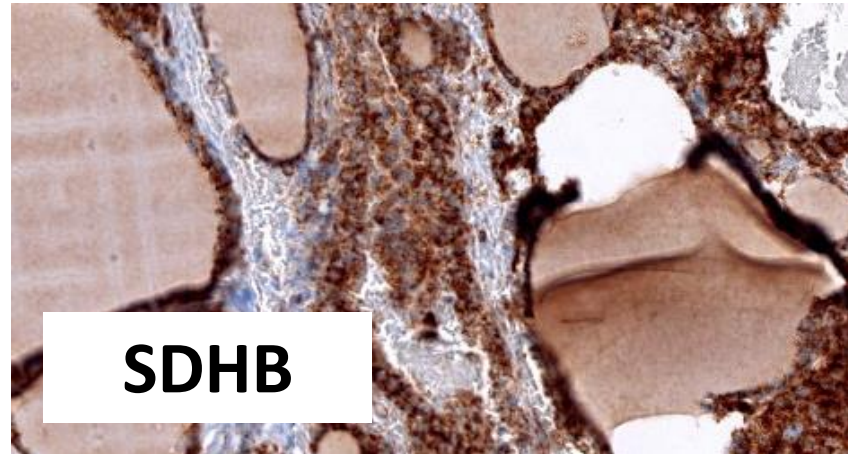
Anticorps	TG	TTF1	PAX8	Chromo Synapto	PTH	Calcito	MIB1	CKAE1
Résultat	-	-	-	+	-	-	2%	-



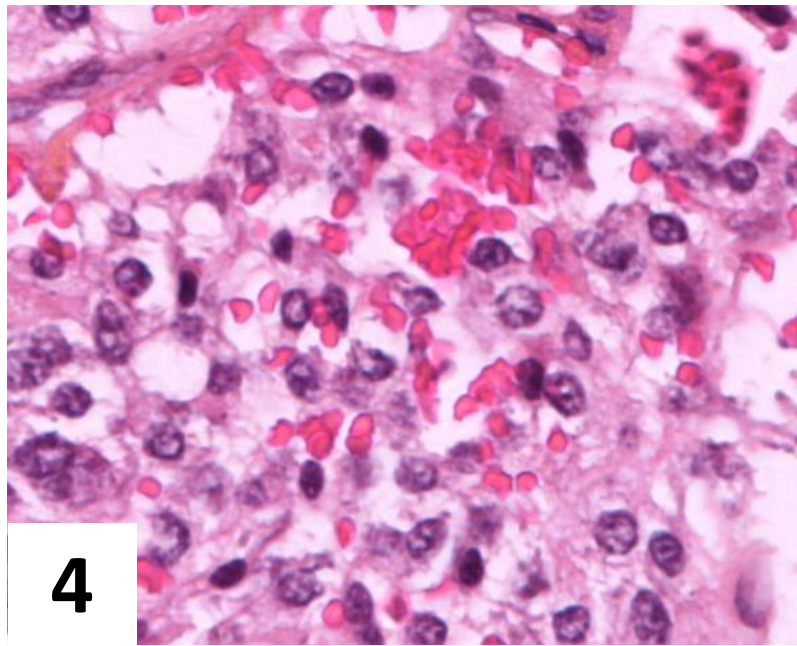
Protéine S100



SDHA



SDHB



Paragangliome intrathyroïdien

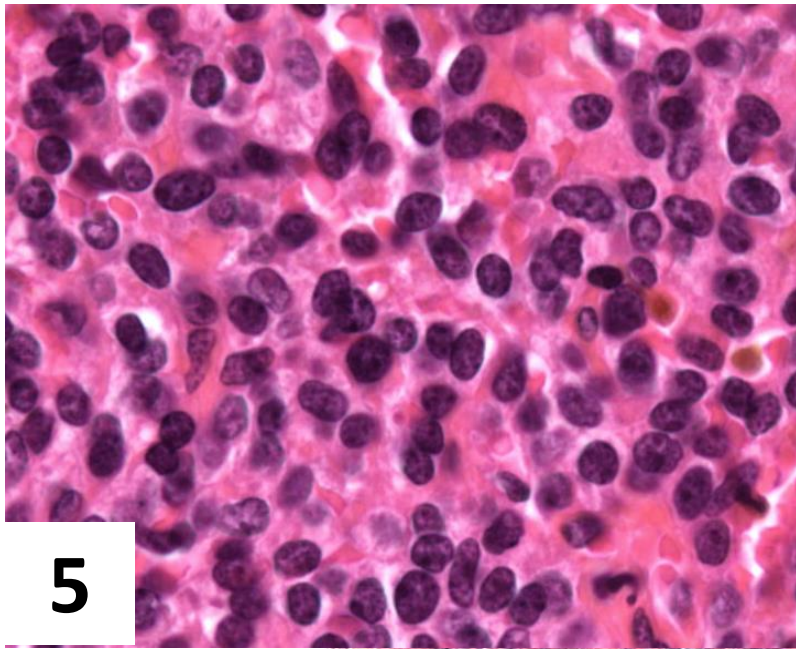
Très rare

0,5 % des paragangliomes « tête et cou »

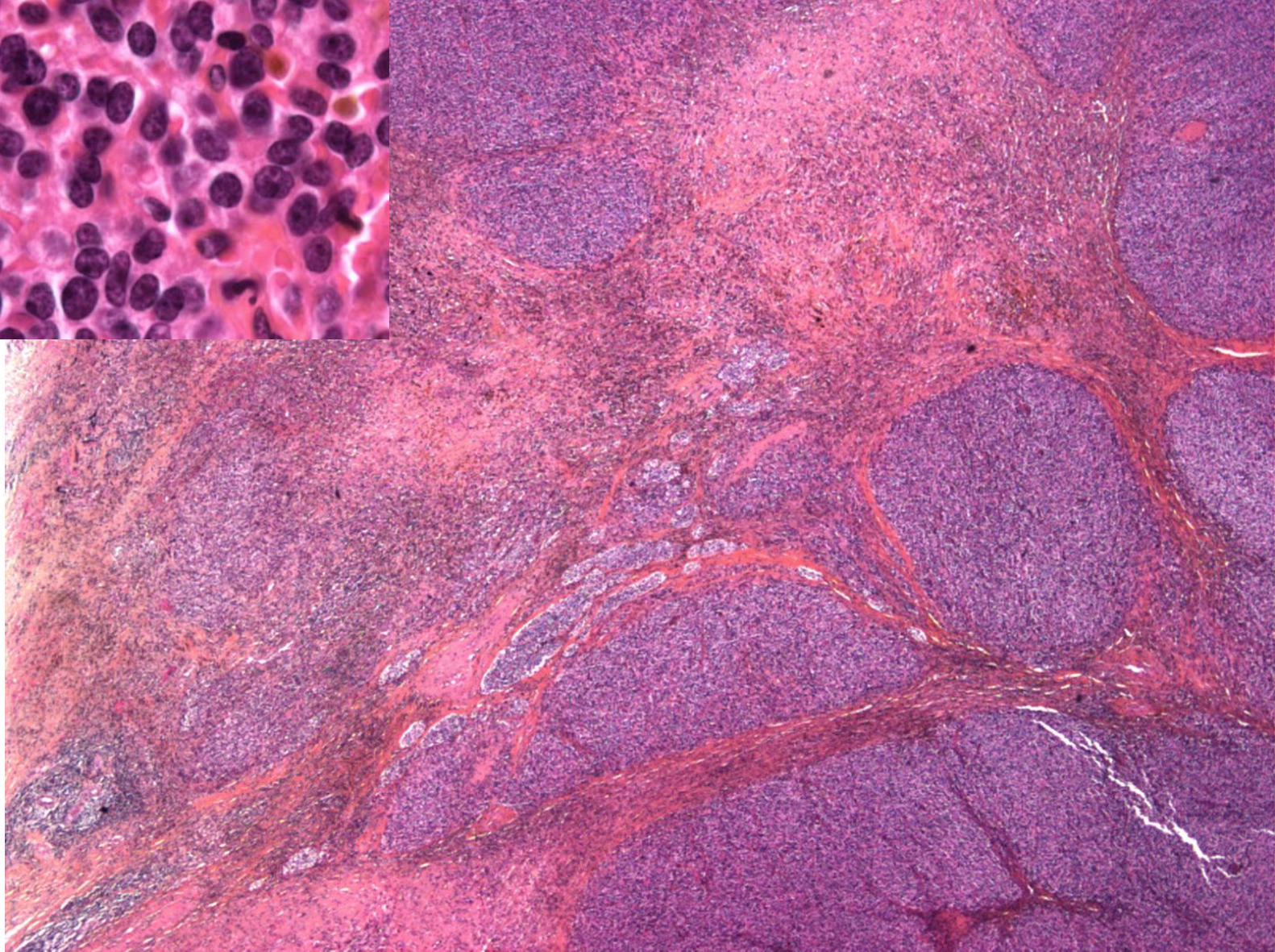
IHC Ac anti-SDHB et SDHA

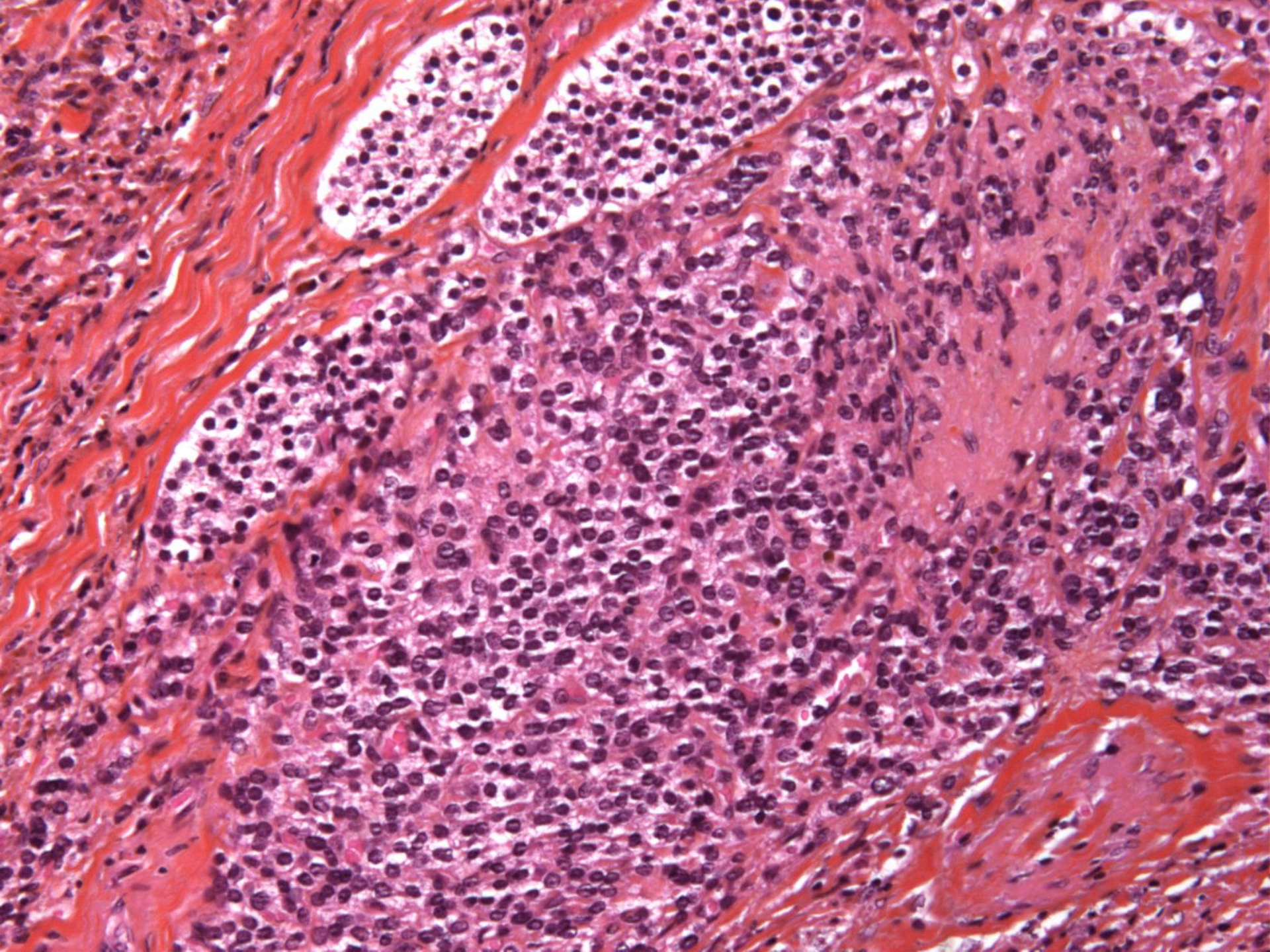
Anticorps	TG	TTF1	PAX8	Chromo Synapto	PTH	Calcito	CKAE1
Résultat	-	-	-	+	-	-	-

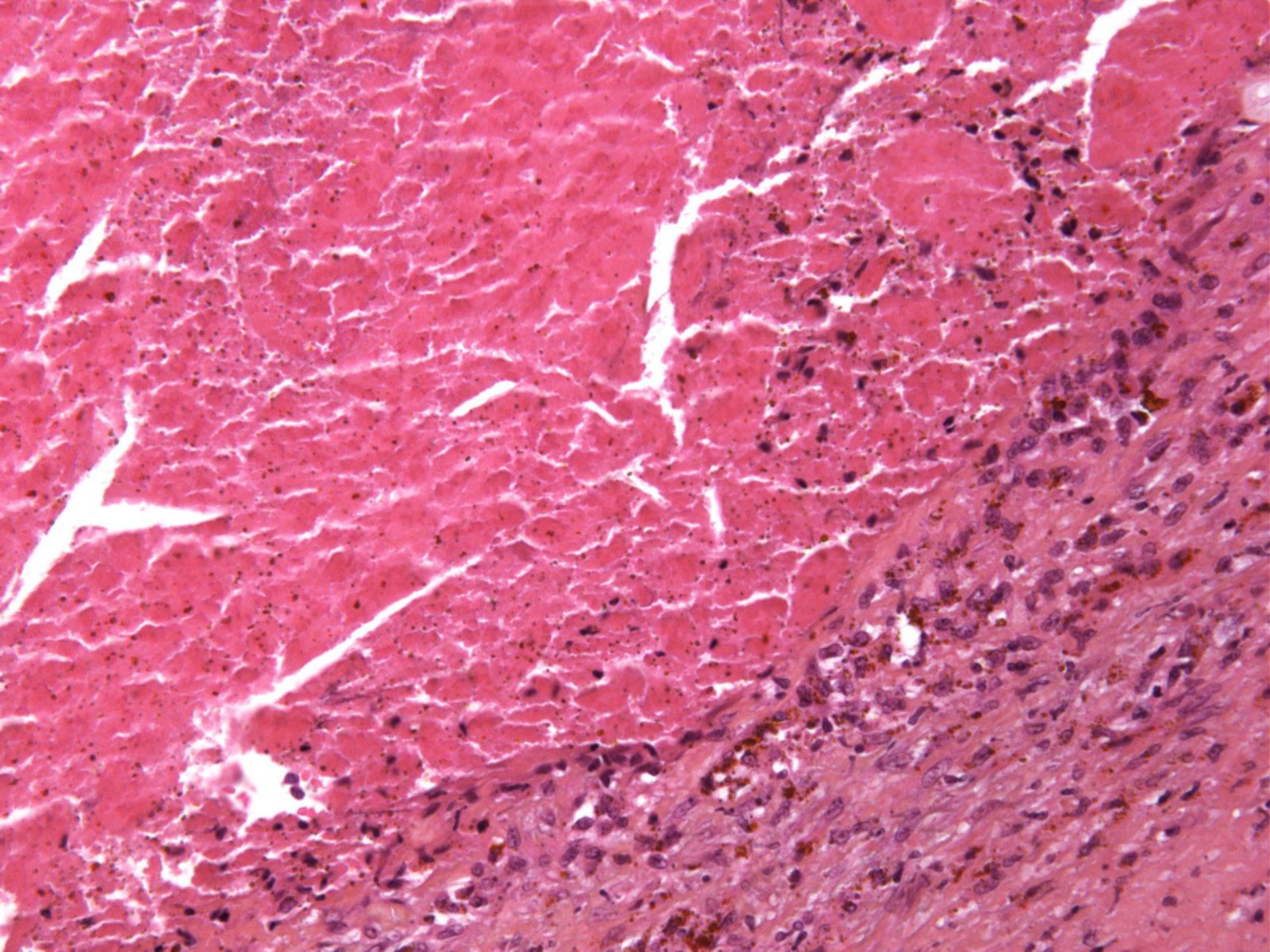
Patient de 37 ans
Nodule thyroïdien droit suspect

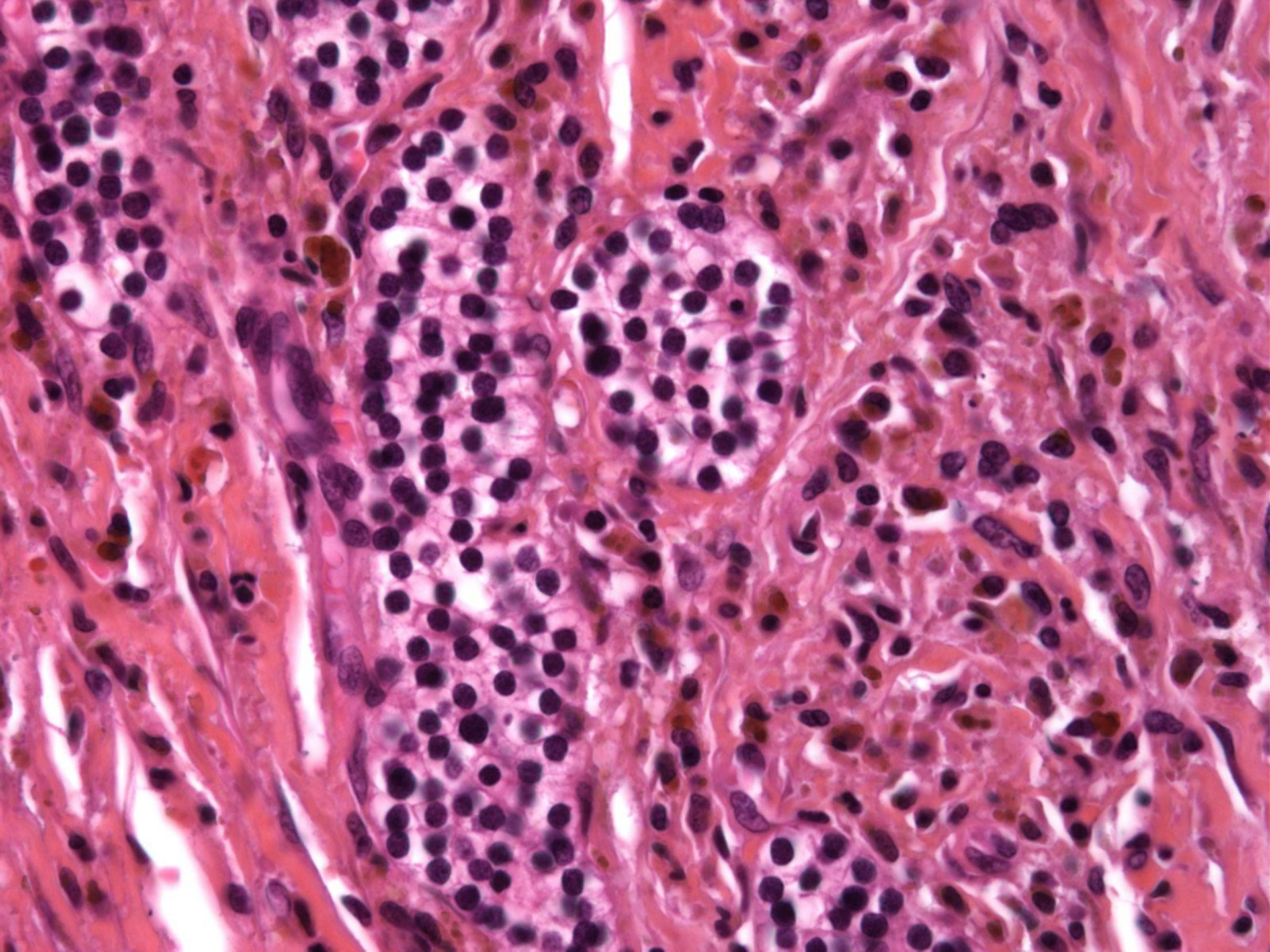


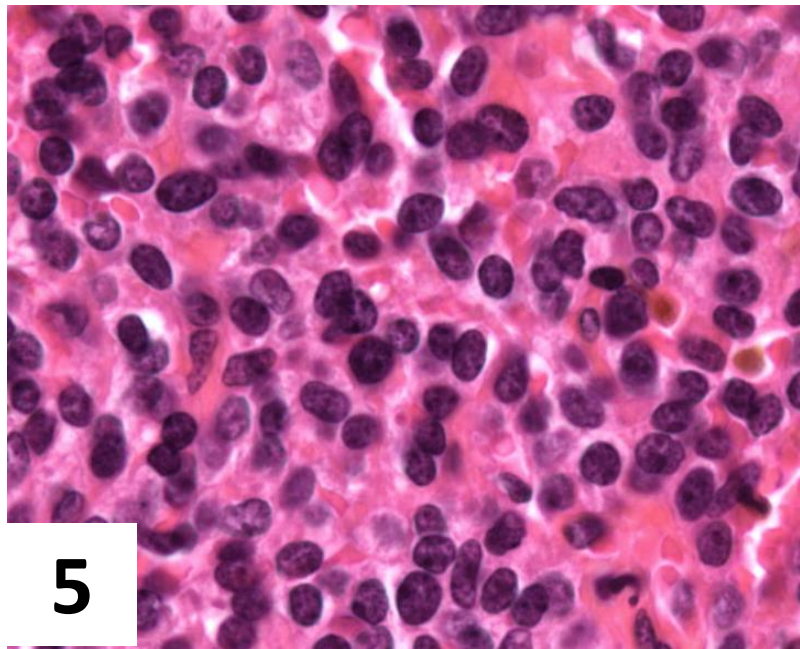
5











Patient de 37 ans
Hyperparathyroïdie primaire

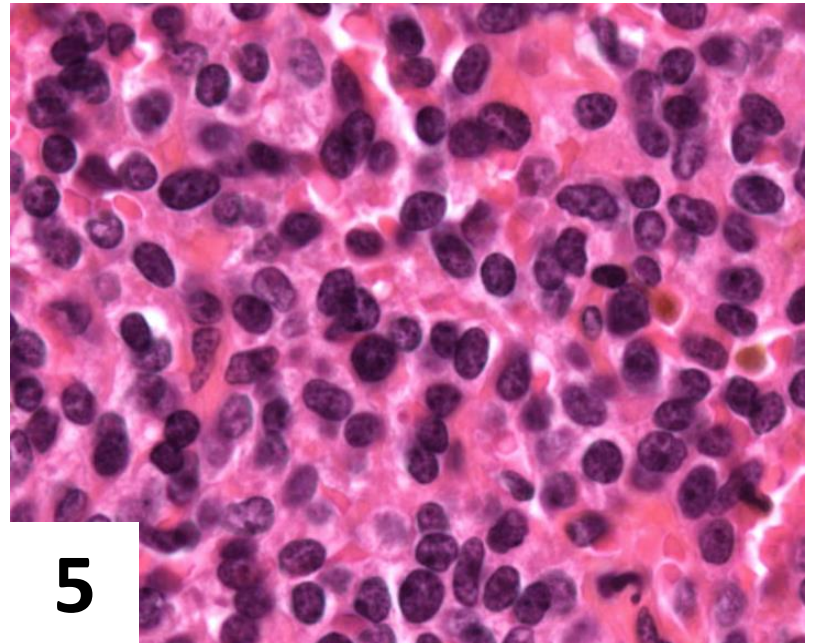
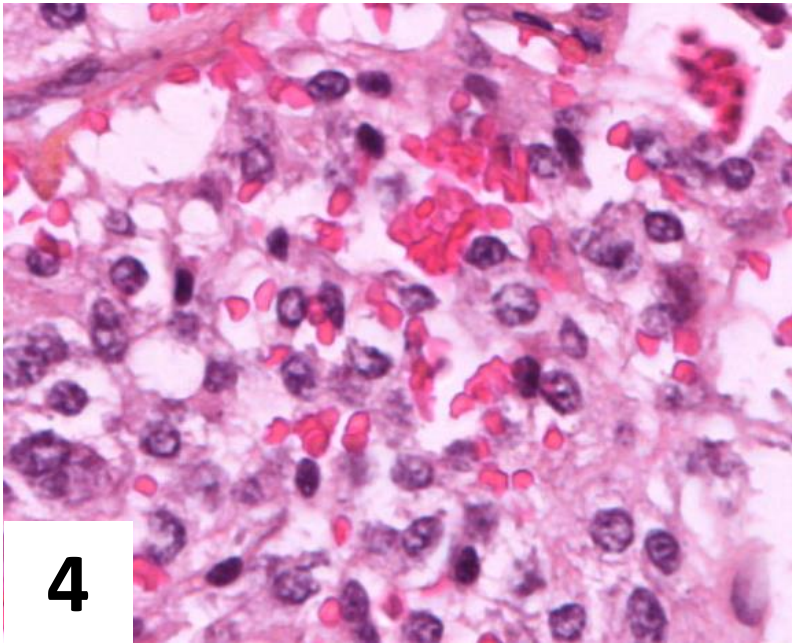
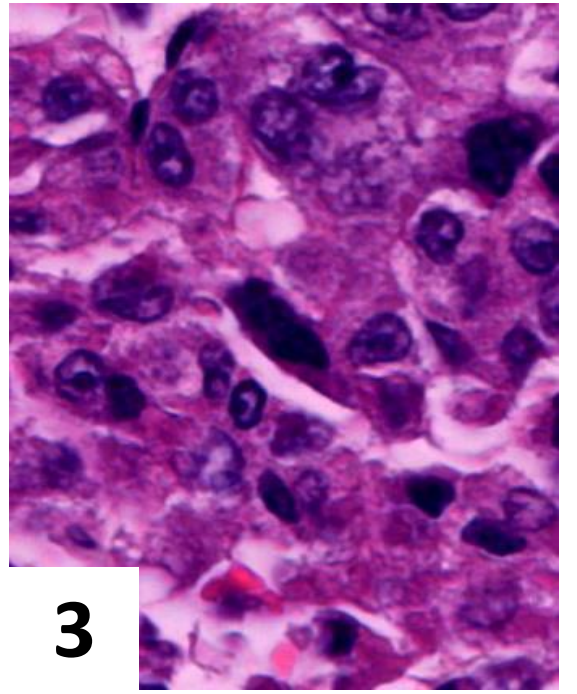
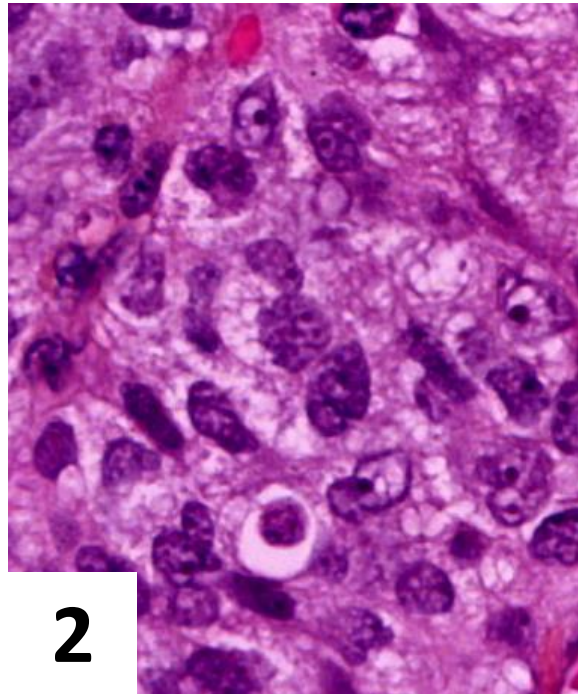
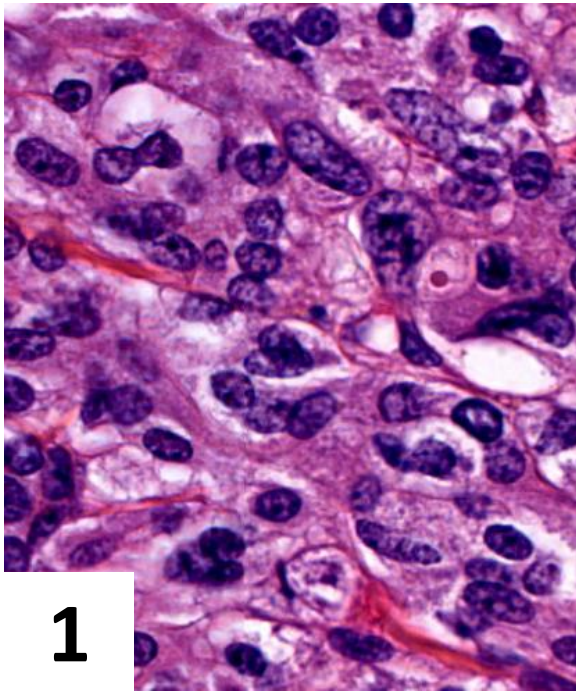
5 mitoses pour 50 HPF

Nécrose

Bandes de fibrose

Anticorps	TG	TTF1	PAX8	Chromo Synapto	PTH	Calcito	MIB1	CKAE1
Résultat	-	-	-	+	+	-	5%	-

Carcinome parathyroïdien




Thyroglobuline + et TTF1+ et PAX8+

OUI



**Tumeur thyroïdienne
de souche folliculaire**



OUI

NON



- **Défaut technique**
- **Type de cellule folliculaire particulier – claire/oxyphile**
- **Carcinome peu différencié**



NON

Tumeurs rares – Pièges diagnostiques

- **Carcinome médullaire méconnu**
- **Métastase**
- **Paragangliome**
- **Tumeur parathyroïdienne.....**

Carrefour Pathologie 2019

Symposium – Pathologie thyroïdienne Pièges diagnostiques

Emmanuelle Leteurtre, Lille

