Symposium SFP : Effets secondaires des immunothérapies

Atteintes digestives et hépatiques liées aux inhibiteurs du checkpoint immunitaire

Charlotte Mussini, Catherine Guettier

Service d' Anatomie Pathologique Hôpitaux universitaires Paris Sud

APHP-Paris Saclay

Faculté de Médecine Paris Sud - Université Paris Saclay

Absence de liens d'intérêt

Carrefour Pathologie 2020

Inhibiteurs du checkpoint immunitaire: une révolution en cancérologie

Target	Agent	Trade Name	FDA-Approved Indications	FDA Approval
CTLA-4	Ipilimumab	Yervoy	Melanoma, MSI-H or dMMR colorectal cancer and intermediate-risk or poor-risk renal cell carcinoma (in combination with nivolumab)	2011
PD-1	Pembrolizumab	Keytruda	Melanoma, non-small-cell lung cancer, head and neck squamous-cell cancer, HCC, classical Hodgkin lymphoma, mediastinal large B-cell lymphoma, urothelial carcinoma, MSI-H or dMMR cancer, gastric cancer, cervical cancer, HCC, Merkel-cell carcinoma, renal-cell carcinoma (in combination with axitinib)	2014
PD-1	Nivolumab	Opdivo	Melanoma, non-small-cell lung cancer, small-cell lung cancer, renal-cell carcinoma, classical Hodgkin lymphoma, squamous-cell carcinoma of the head and heck, urothelial carcinoma, MSI-H or dMMR colorectal cancer, HCC	2014
PD-1	Cemiplimab	Libtayo	Cutaneous squamous-cell carcinoma	2018
PD-L1	Atezolizumab	Tecentriq	Non-small-cell lung cancer, urothelial carcinoma	2016
PD-L1	Avelumab	Bavencio	Merkel-cell carcinoma, urothelial carcinoma	2017
PD-L1	Durvalumab	Imfinzi	Non-small-cell lung cancer, urothelial carcinoma	2017
CTLA4	Tremelimumab		Mesothelioma, non-small-cell lung cancer	

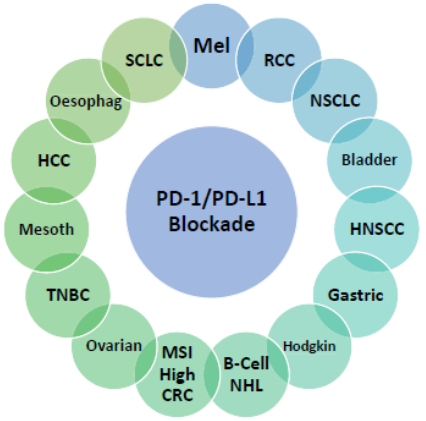

Michot European J Cancer 2016
Peeraphatdit Hepatology 2020

Effets secondaires (irAEs)

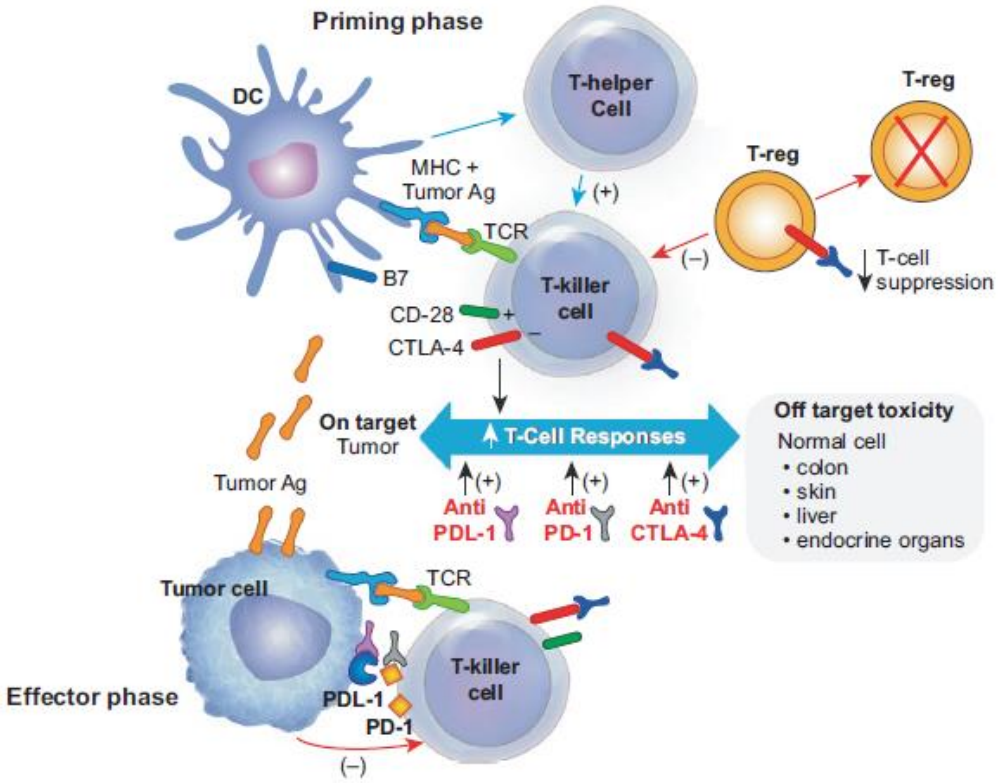

- Cytotoxicité directe (cellules biliaires PD-L1/2)
- Relargage de néoantigènes (epitope spreading)
- Cellules B autoréactives
- Immunisation croisée avec les ag tumoraux
- Déplétion en T-reg CTLA4+
- Composition du microbiote (Firmicutes)

Suzman Liver International 2018
Lleo Dig Liver Dis 2019
Imito Can J Gastroenterol Hepatol 2019
De Martin JHEP Reports 2020

Fréquence des effets secondaires des ICI

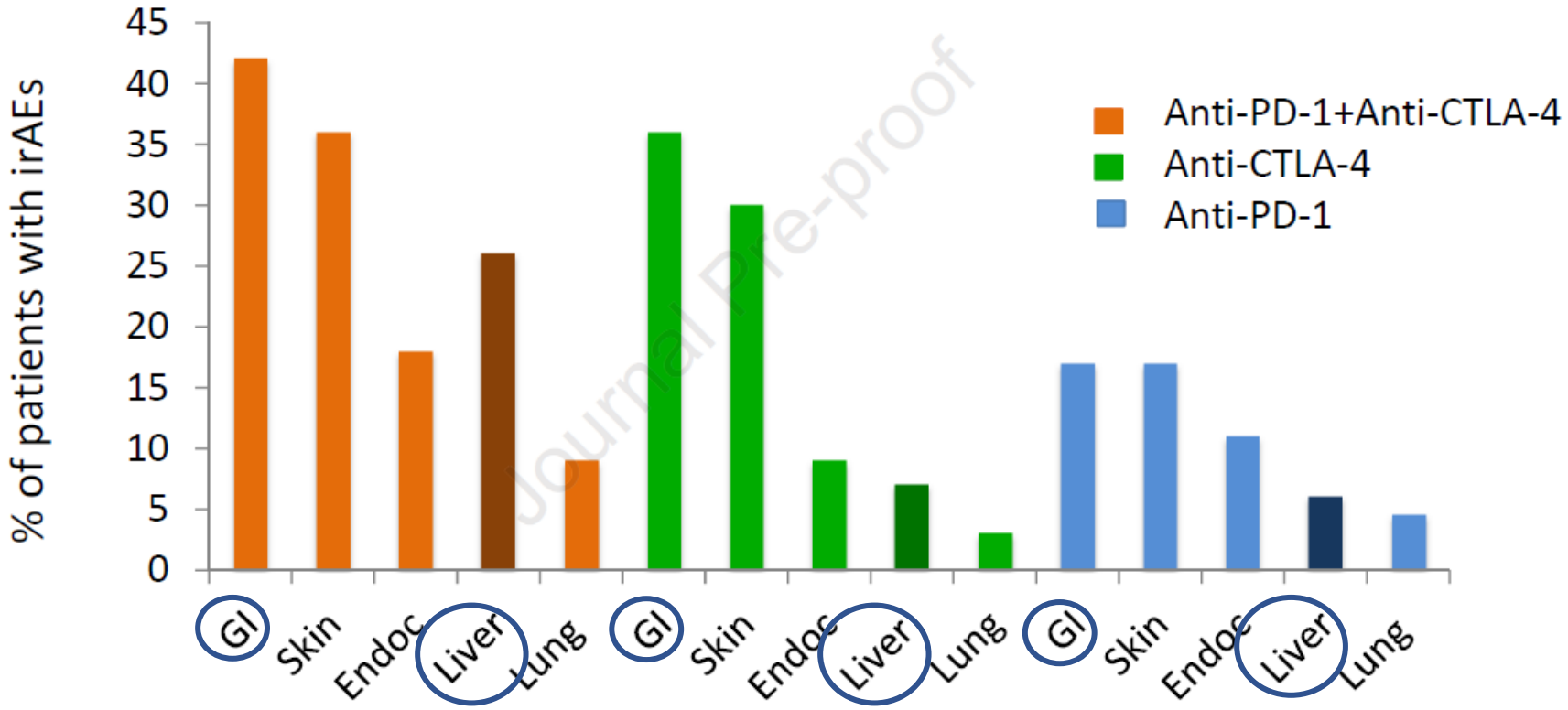

Journal Pre-proof

De Martin JHED Reports 2020

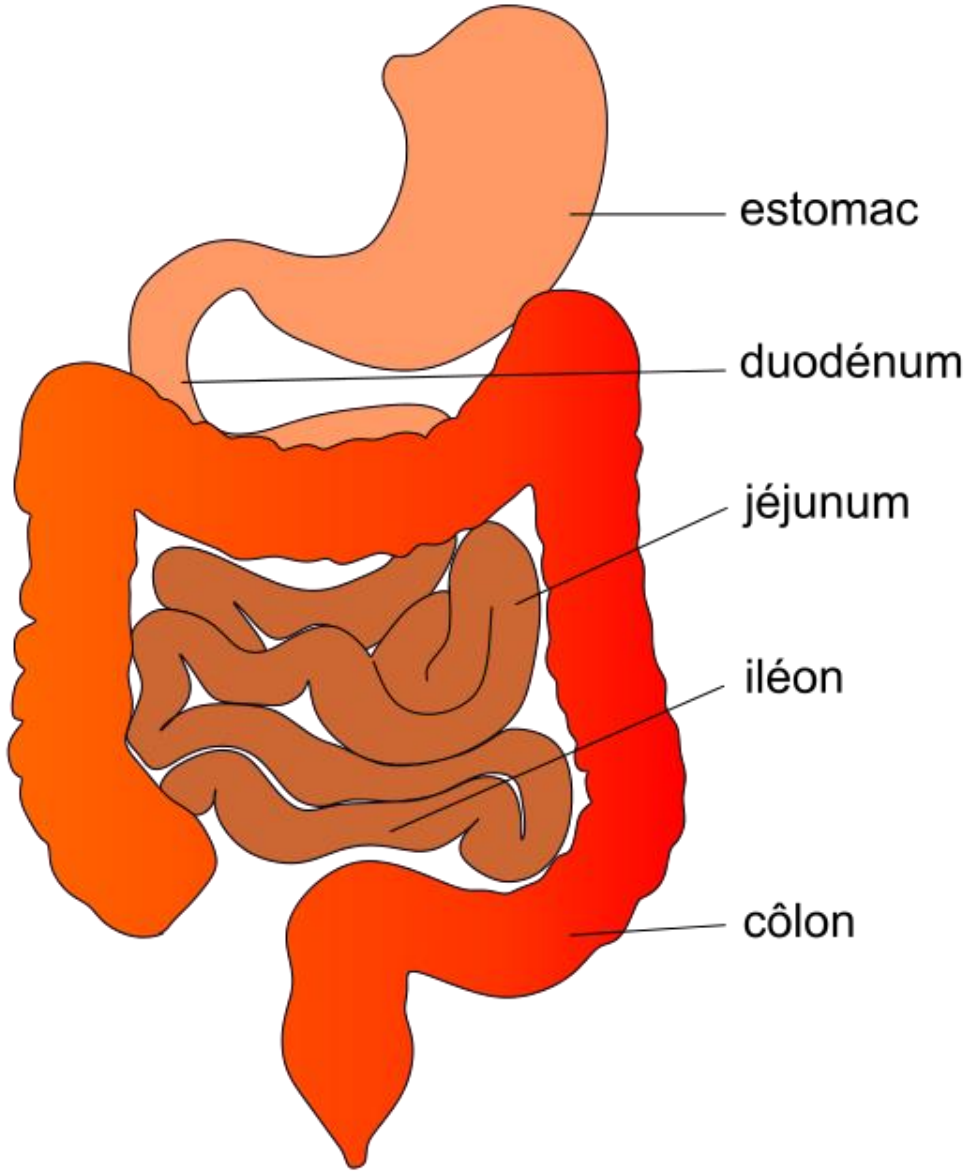
estomac
duodénum
jéjunum
iléon
côlon

Atteintes digestives immuno-induites

Fréquence:

anti-CTLA4: 27-43%

anti-PD1/PD-L1: 6 à 20%

Délai :

anti-CTLA4 : 2 à 8 semaines

anti-PD1: 6 à 18 semaines

Atteintes:

Côlon ++ (côlon descendant)

Estomac

Duodénum/Iléon

Gravité:

Colites aiguës graves, colectasies aiguës, perforation

Table 2 Grading the severity of immune checkpoint inhibitor-induced colitis and diarrhea based on Common Terminology Criteria for Adverse Events grade

	Colitis	Diarrhea
Grade 1	Asymptomatic	Increase of < 4 stools/d over baseline
Grade 2	Abdominal pain, mucus, blood in stool	Increase of 4-6 stools/d
Grade 3	Severe pain, fever, peritoneal signs	Increase of ≥ 7 stools/d
Grade 4	Life-threatening consequences such as perforation, ischemia, necrosis, bleeding, toxic megacolon	Life-threatening consequences such as hemodynamic collapse
Grade 5	Death	Death

Papouin Ann Pathol 2018
Cramer Curr Gastroenterol Rep 2017

Reddy Clin Transl Gastroenterol 2018
Som World J Clin Cas 2019

Atteintes coliques: Endoscopie

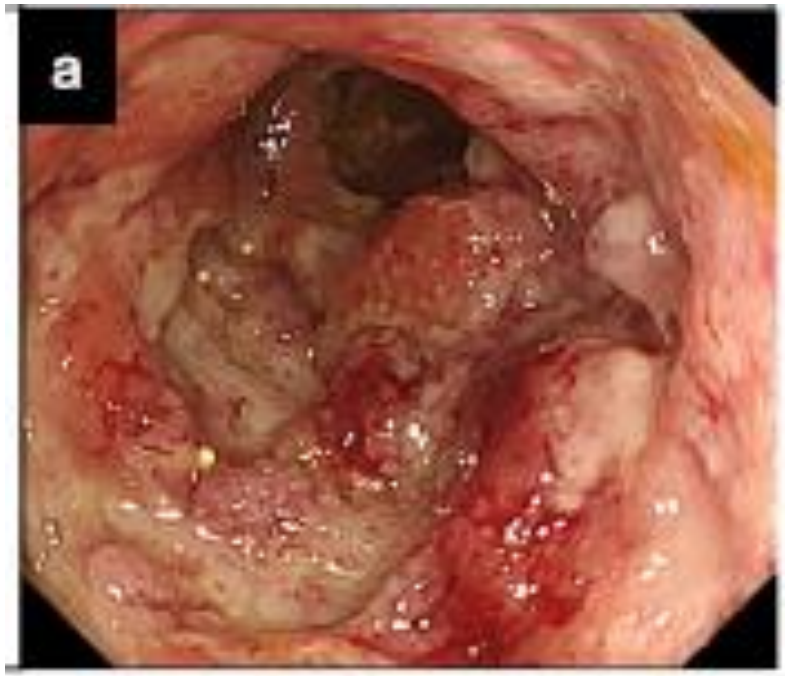

Endoscopie colique:

- Normale
- Erythème
- Erosions
- Ulcérations
- Perte du pattern vasculaire

Atteinte focale: 75%
Atteinte continue : 25%

Cramer Curr Gastroenterol Rep 2017
Collins Ann Oncol 2017
Reddy Clin Transl Gastroenterol 2018
Som World J Clin Cas 2019
Yoshino BMC C ancer 2019

Atteintes coliques: Histologie

Anti-PD1/PD-L1

Anti-CTLA4

Colite aiguë active à PNN focale ou diffuse ± iléite

Colite lymphocytaire

Colite collagène

Colite granulomateuse

Signes de chronicité?

Cramer Curr Gastroenterol Rep 2017
Collins Ann Oncol 2017

Reddy Clin Transl Gastroenterol 2018
Som World J Clin Cas 2019
Yoshino BMC C ancer 2019

Atteintes coliques: Colite aiguë active

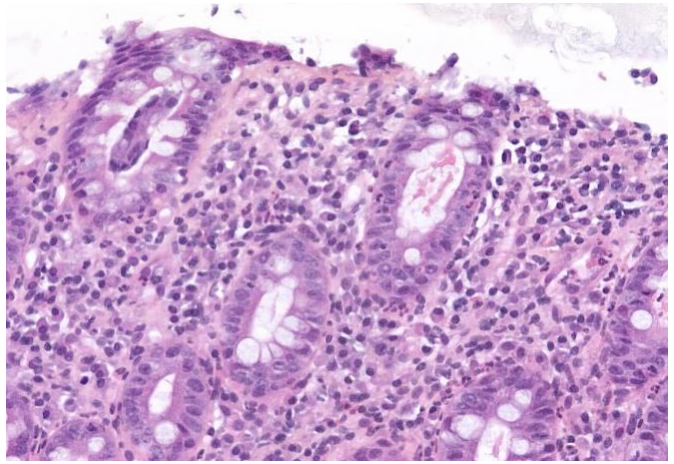

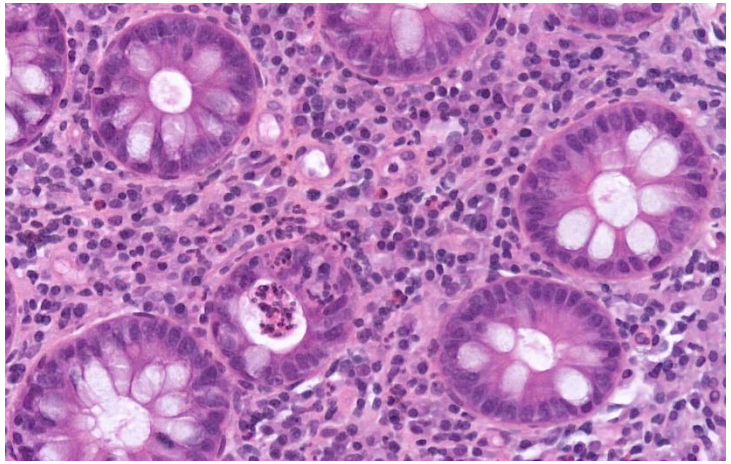

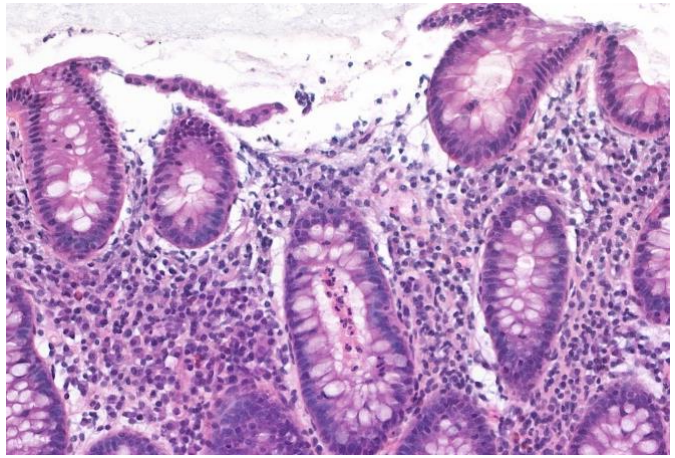

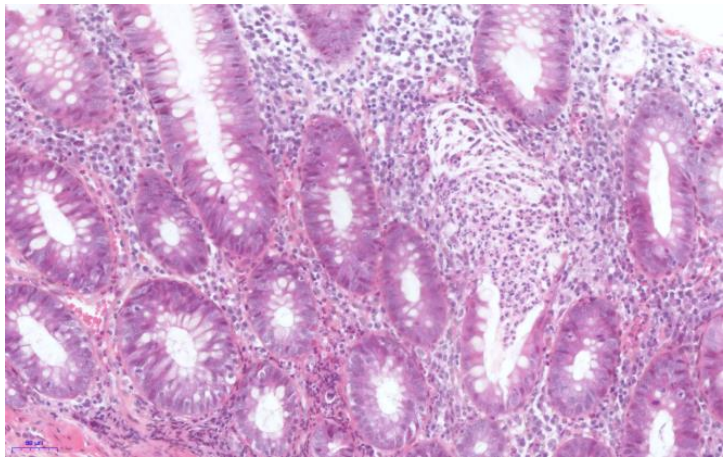

- Infiltrat inflammatoire du chorion
- Erosions/ulcérations
- Exocytose à PNN
- Abcès cryptiques
- Apoptose dans les cryptes
- Granulomes (anti-CTLA4)

- Distorsion des cryptes

- Anti-PD1: CD8+, T reg+
- Anti-CTLA4: CD4 +

Collins Ann Oncol 2017
Som World J Clin Cas 2019

Atteintes coliques: Colites microscopiques

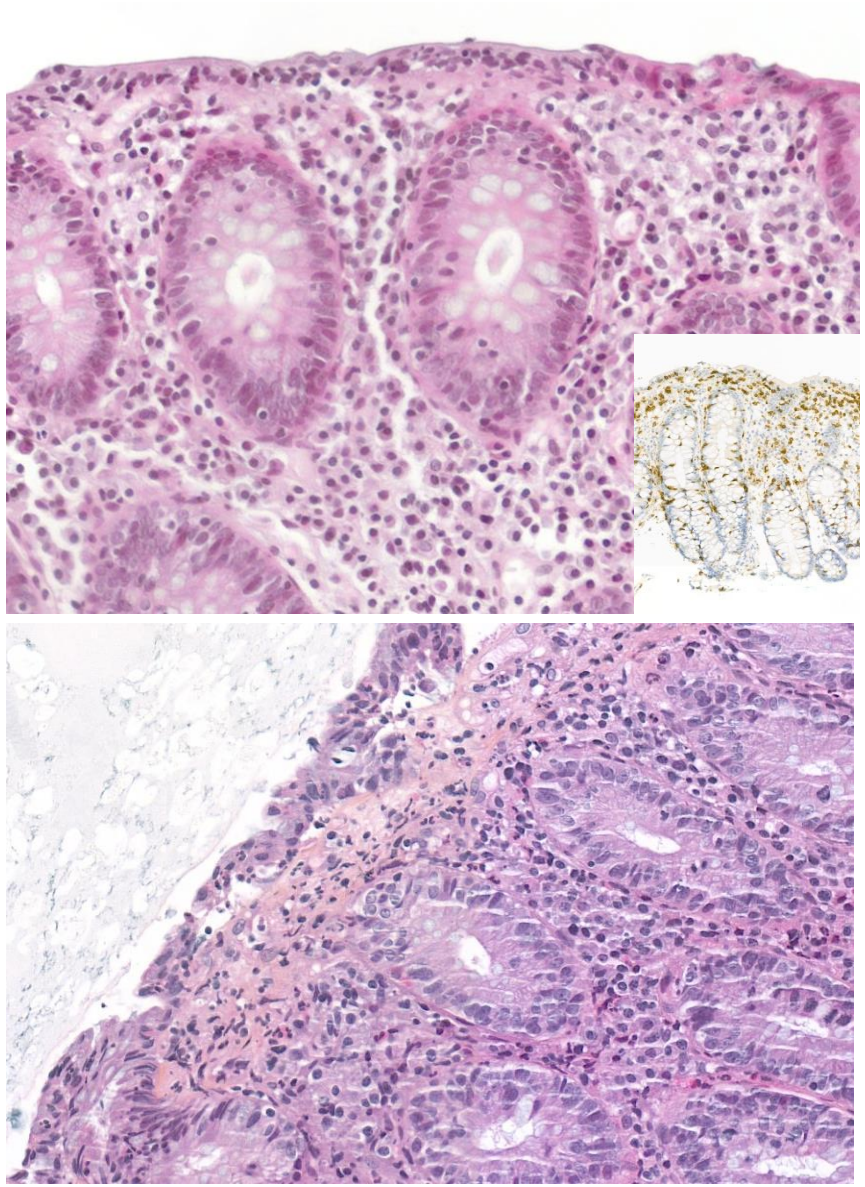

- Anti-PD1
- Colite lymphocytaire (6/20):
  lymphocytose > 30/100 entérocytes dans
  l'épithélium de surface et les cryptes
- Lymphocytes CD3+ CD8+
- Colite collagène (1/20)
- Lésions associées de colite aiguë active

Collins Ann Oncol 2017

Atteintes digestives hautes

Anti-PD1/PD-L1

Anti-PD1/Anti-CTLA4

Gastrite active à PNN HP- (gastrite nécrosante)

Gastrite lymphoplasmocytaire (collet des glandes)

Gastrite granulomateuse

Duodénite active à PNN

Duodénite lymphoplasmocytaire

Duodénite lymphocytaire

Duodénite granulomateuse

Fréquence ?

Collins Ann Oncol 2017
Zhang Histopathology 2020
Som World J Clin 2019

Atteintes digestives hautes

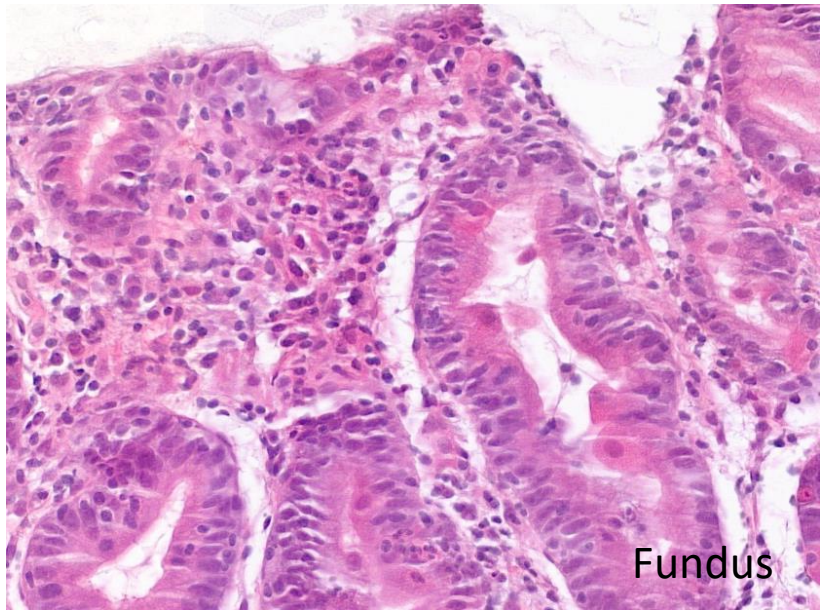

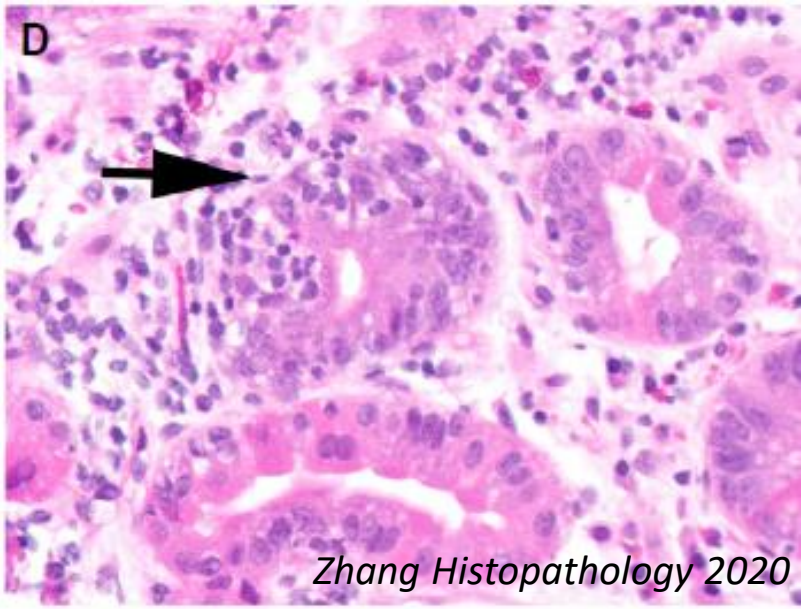

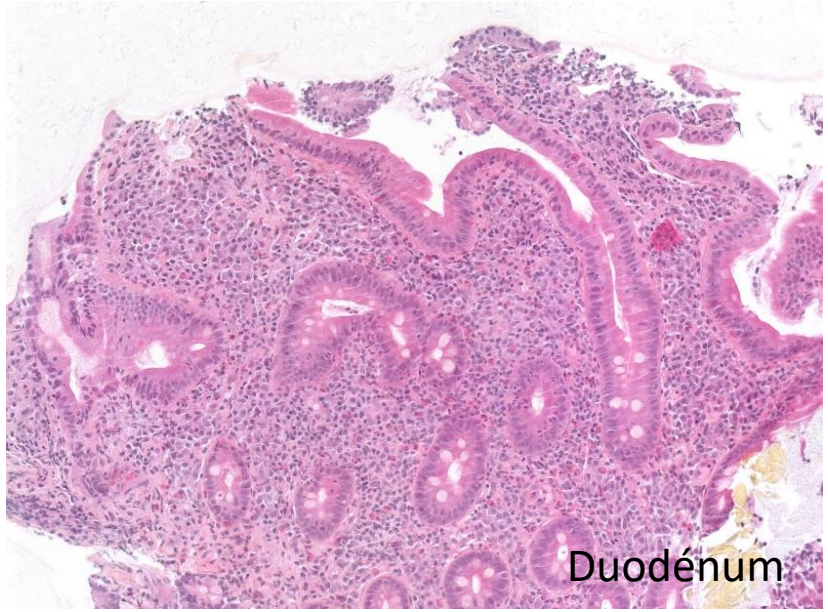

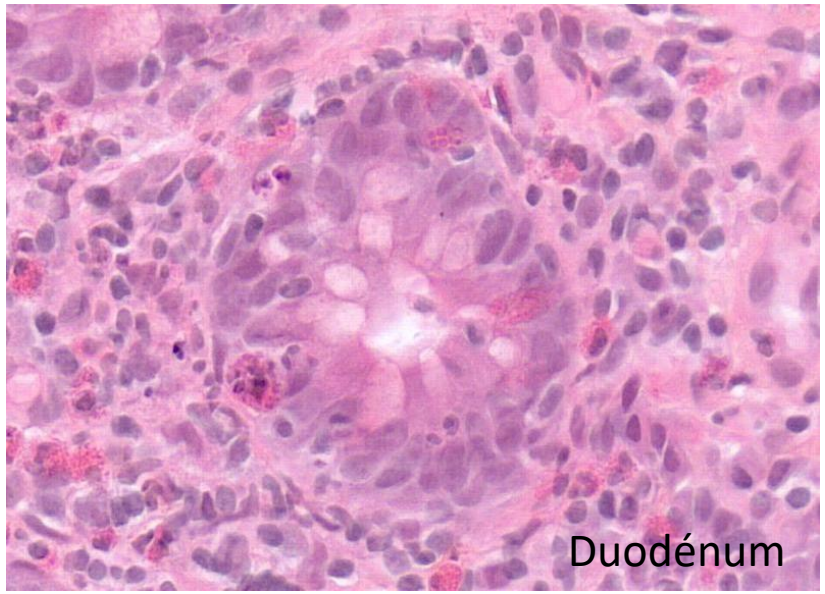

Atteintes digestives: Apport des biopsies

- Recommandées même si aspect endoscopique normal
- Diagnostics différentiels (causalité)

Iléon-côlon
Localisation métastatique
Entérocolite infectieuse
Autres colites médicamenteuses
MICI*

Estomac
Localisation métastatique
Gastrite HP
Gastrite CMV
Gastrite Crohn

Duodénum
Localisation métastatique
Duodénite CMV
Duodénite Crohn
Maladie coeliaque

- Diagnostic de gravité : mais histologie non prise en compte dans les algorithmes de management

Grade of colitis	Society for Immunotherapy of Cancer recommendations	American Society of Clinical Oncology recommendations	European Society for Medical Oncology recommendations

Cramer Curr Gastroenterol Rep 2017
Reddy Clin Transl Gastroenterol 2018

Atteintes digestives: Diagnostic différentiel

	Crohn's disease	Ulcerative colitis	CPI irAE
Primary location of inflammation	Anywhere along the GI tract (most commonly involves the terminal ileum)	Colon (increasing intensity distally)	Anywhere along the GI tract
Distribution	Patchy, transmural	Continuous, superficial	Continuous, superficial
Histological findings	- Granulomas - Skip lesions - Crypt distortion - Cryptitis	- Basal plasmacytosis - Paneth cell metaplasia - Mucin depletion - Crypt distortion - Cryptitis	- Granulomas - Cryptitis

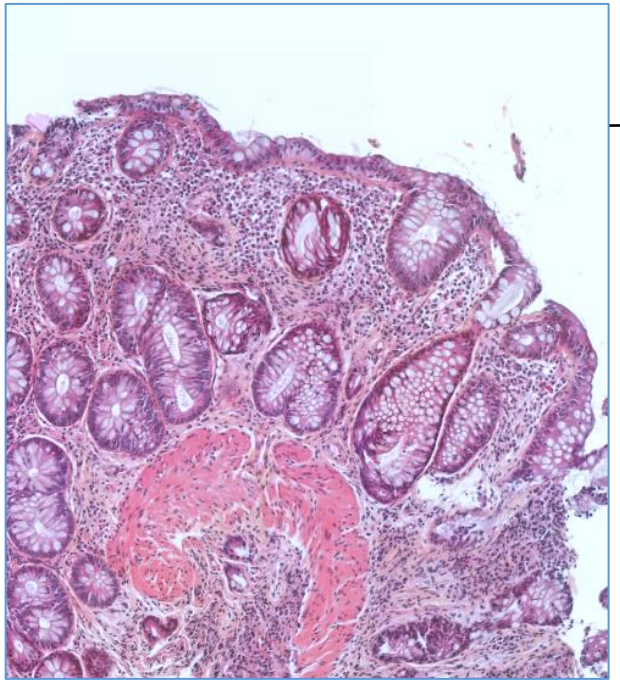

Colite sous PD-L1

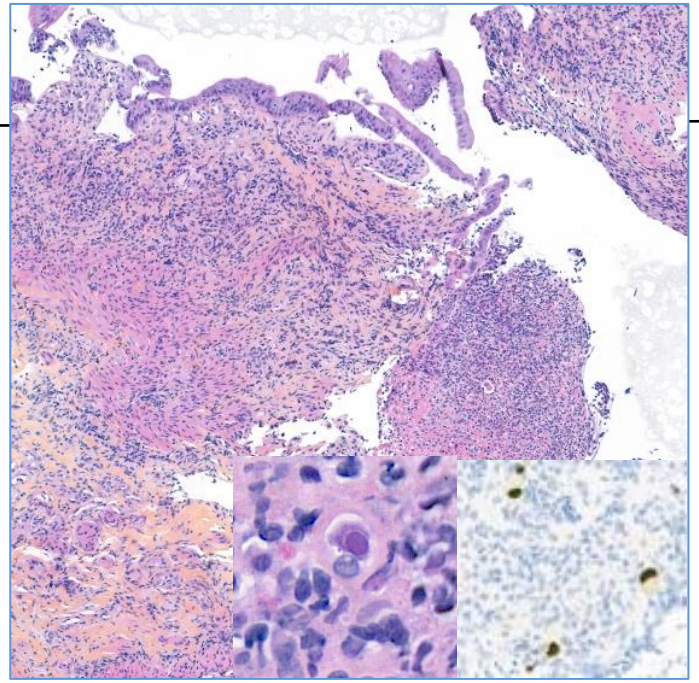

Iléite ulcérée à CMV
Traitement par anti-PD1

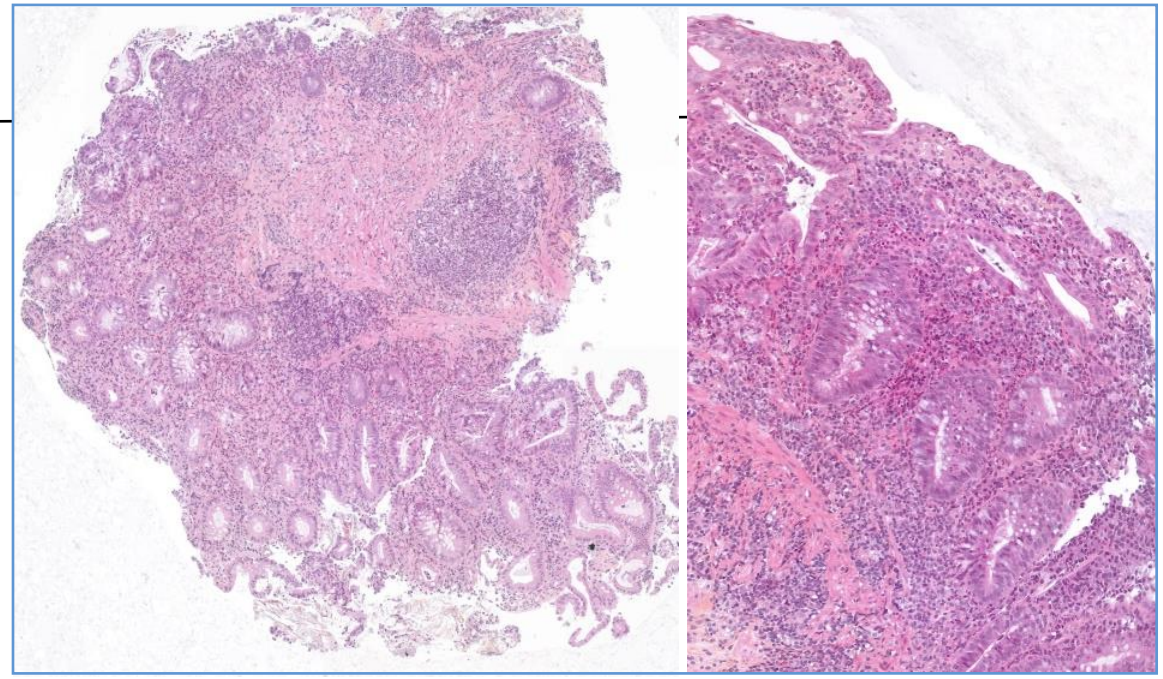

RCH sous Salazopyrine
Anti-PD1

Cramer Curr Gastroenterol Rep 2017

Atteintes digestives: Evolution

- Arrêt de l'immunothérapie
- Corticothérapie
- Si corticorésistance, infliximab ou autre immunosuppresseur
- Reprise de l'immunothérapie anti-PD1/anti-PDL1 >>CTLA4

- Résolution complète
- Evolution prolongée
- Evolution chronique « MICI -like»

Collins Ann Oncol 2017
Cramer Curr Gastroenterol Rep 2017
Som World J Clin Cas 2019

Atteintes digestives immuno-induites

Take home message

- Fréquentes en particulier sous anti-CTLA4 ou traitement combiné
- Atteinte colique prédominante
- Gravité potentielle
- Biopsies recommandées
- Colites aiguës actives (anti-PD1 ou PDL1/ anti-CTLA4)
- Colites microscopiques (anti-PD1)
- Evolution vers la chronicité?
- Confrontation anatomoclinique++

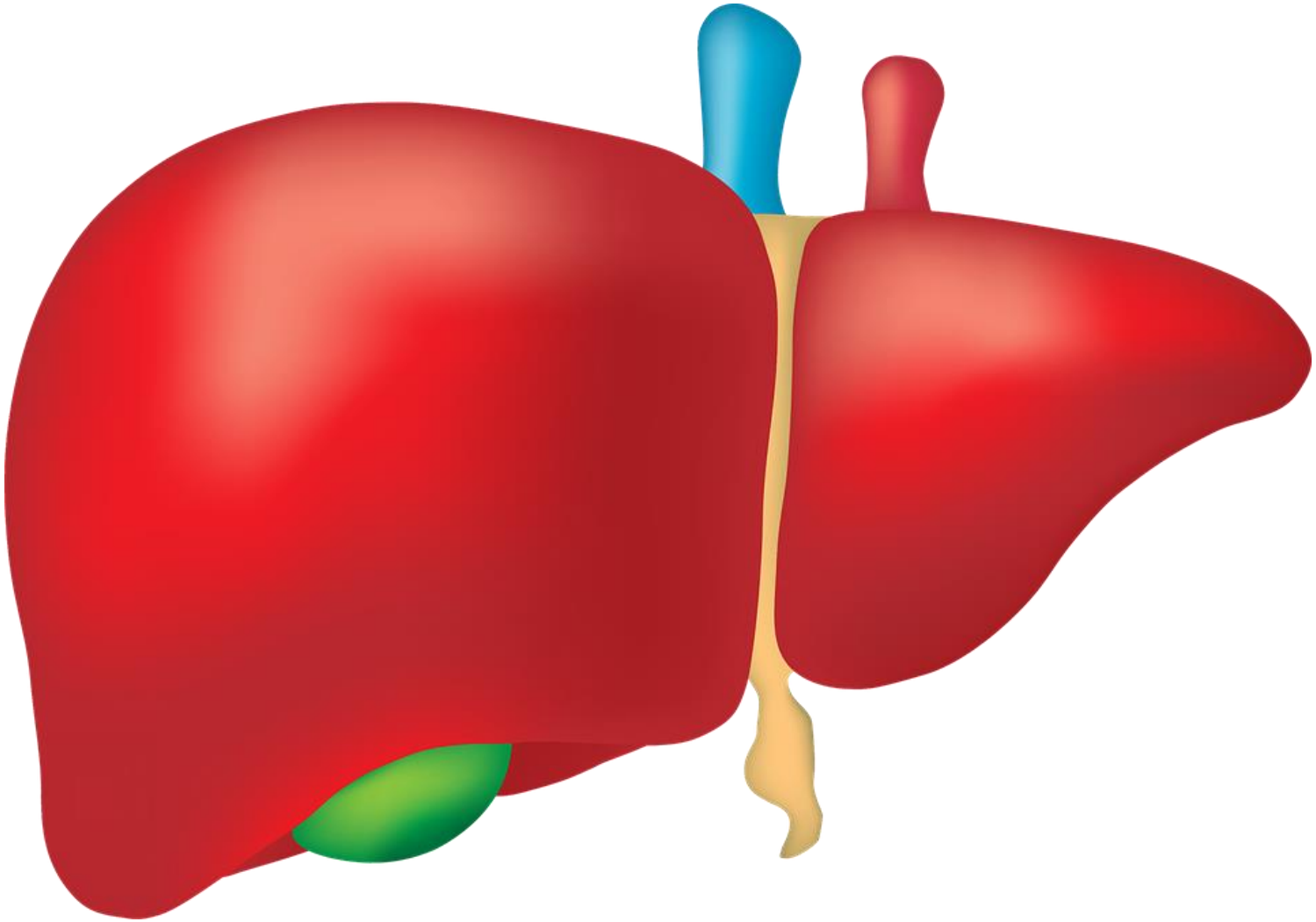

Atteintes hépatiques immuno-induites

Fréquence:

anti-PD1: 1-2%
anti-PD-L1/ anti-CTLA4 (St): 1 à 12%
anti-CTLA4 (Hd) ou anti-CTLA4/PD1: 16-37%

Délai :

anti-CTLA4: 1 à 6 semaines
anti-PD1/anti-PD-L1: 14 semaines

Atteintes:

Asymptomatique
Hépatite cytolytique ou mixte
Fièvre

Gravité:

Exceptionnels cas d'hépatites fulminantes

Grade	1 Mild	2 Moderate	3 Severe	4 Life-Threatening
AST (xULN)	>1-3x	>3-5x	>5-20x	>20x
ALT (xULN)	>1-3x	>3-5x	>5-20x	>20x
ALP (xULN)	>1-2.5x	>2.5-5x	>5-20x	>20x
GGT (xULN)	>1-2.5x	>2.5-5x	>5-20x	>20x
Total- bilirubin (xULN)	>1-1.5x	>1.5-3x	>3-10x	>10x

Papouin Ann Pathol 2018
De Martin JHED Reports 2020
Peeraphatdit Hepatology 2020

Atteintes hépatiques: incidence

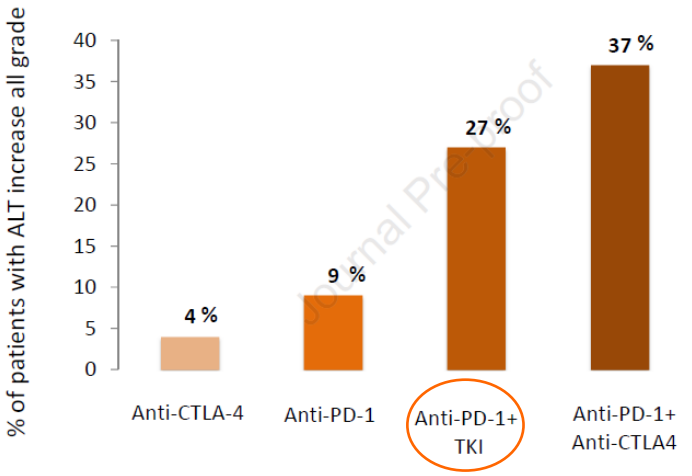

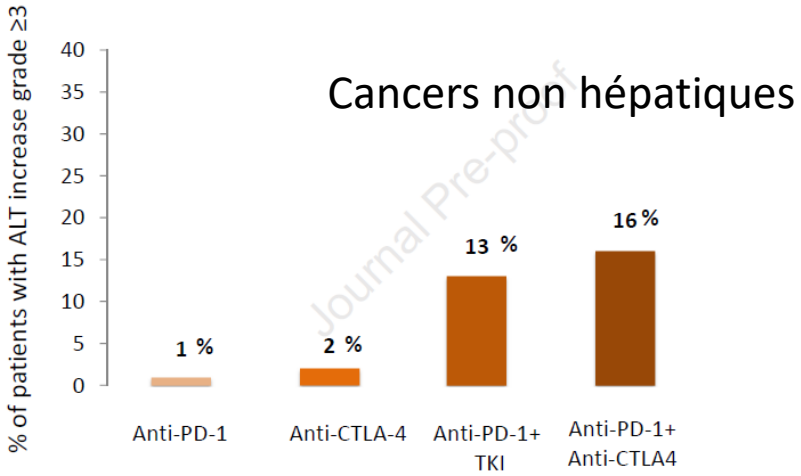

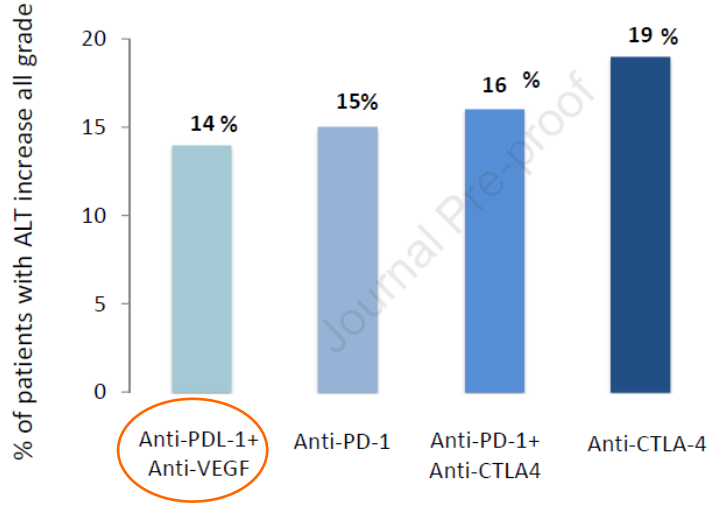

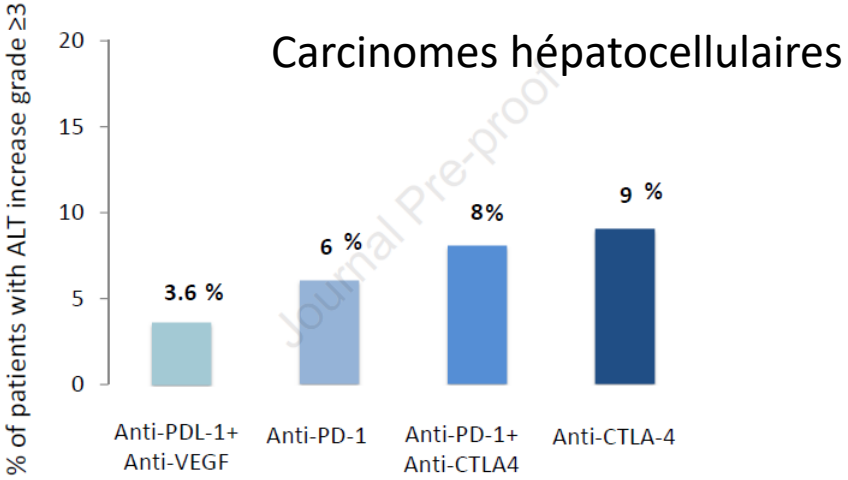

De Martin JHED Reports 2020

Atteintes hépatiques: Histologie

Anti-PD1/PD-L1

Anti-CTLA4 ± anti-PD1

Hépatite lobulaire avec nécrose ponctuée

Hépatite avec nécrose confluente CL/PL

Cholangite lymphocytaire/PNN

Atteinte des gros canaux biliaires

Hépatite microgranulomateuse

Granulomes à anneau de fibrine

HNR/SOS?

Signes de chronicité?

Papouin Ann Pathol 2018
Nishida Hepatol Int 2019

De Martin JHED Reports 2020
Peeraphatdit Hepatology 2020

Atteintes hépatiques: Anti-PD1/PD-L1

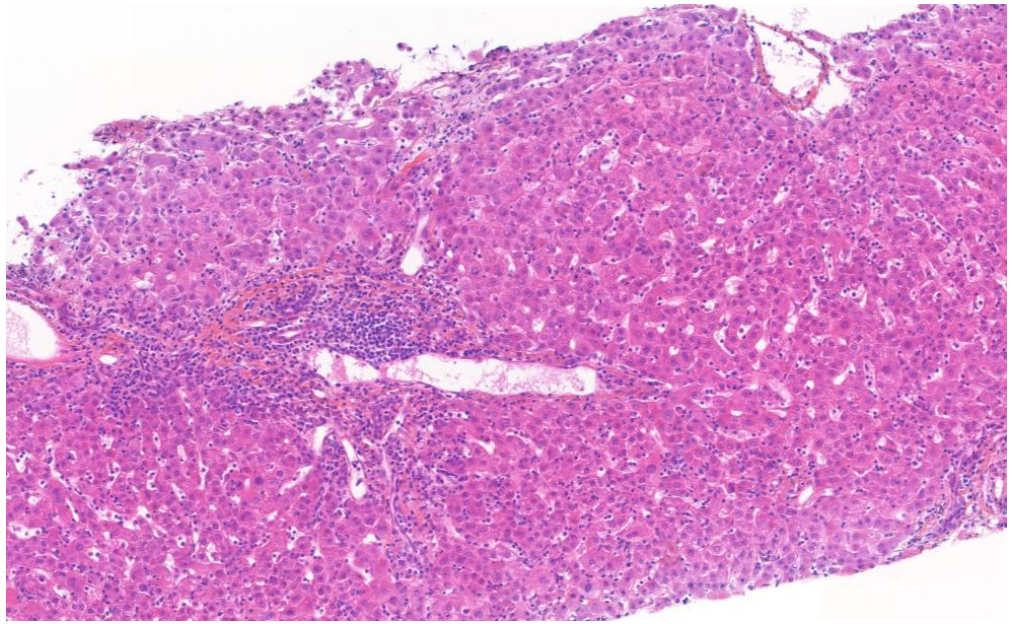

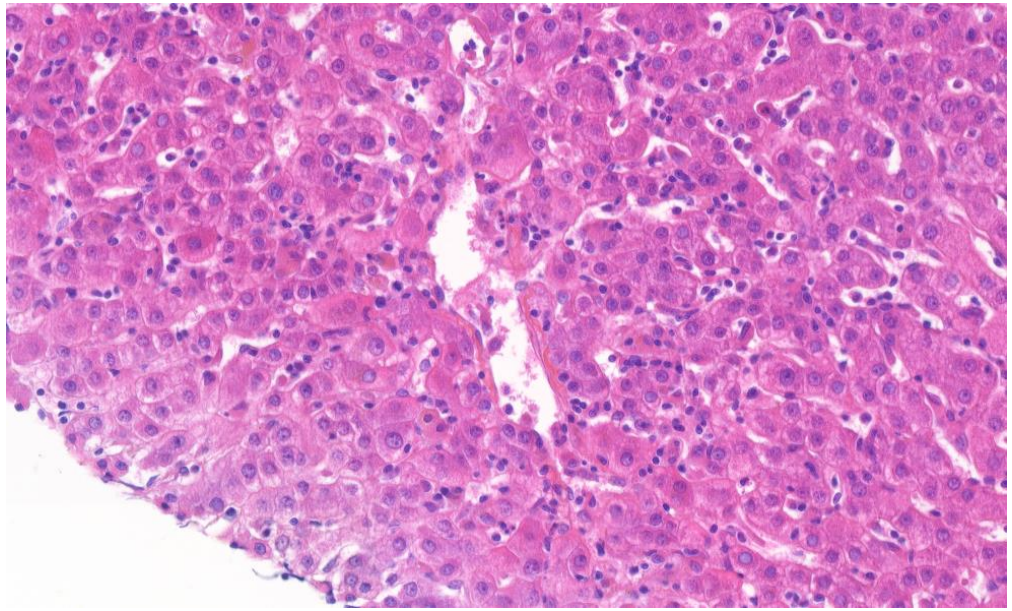

- Hépatite lobulaire avec nécrose ponctuée
- Nécrose confluente rare
- Infiltrat portal avec discrète activité périportale
- Endothélite veineuse portale
- Lymphocytes, histiocytes, PNN
- **Pas de plasmocytes**
- Signes de régénération hépatocellulaire
- CD8+ CD4+

Papouin Ann Pathol 2018
Nishida Hepatol Int 2019

De Martin JHED Reports 2020
Peeraphatdit Hepatology 2020

Atteintes hépatiques: Anti-PD1/PD-L1

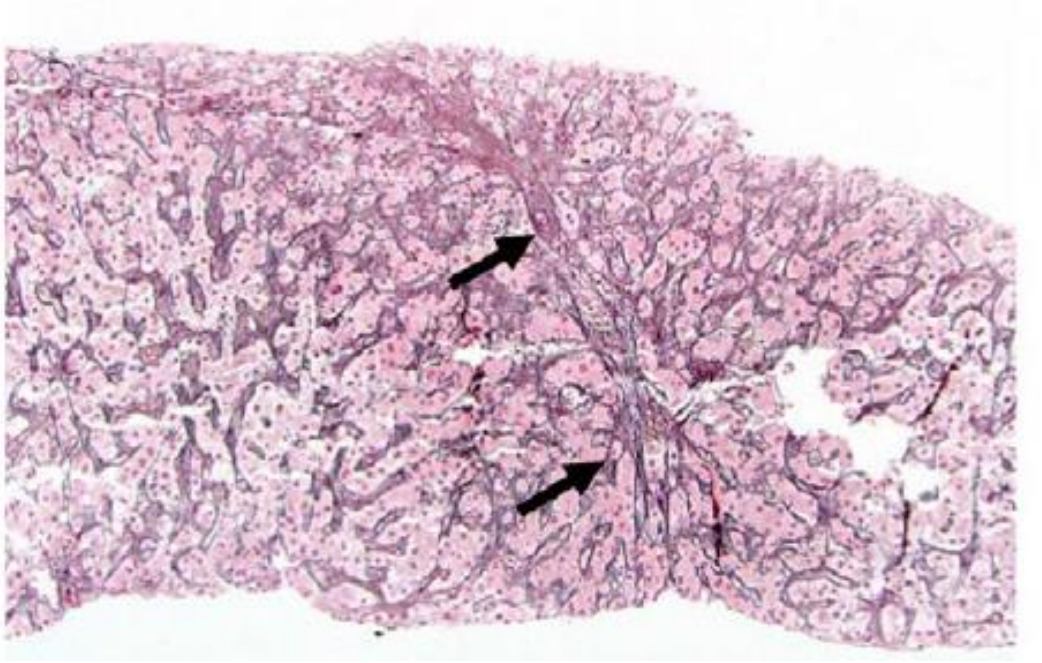

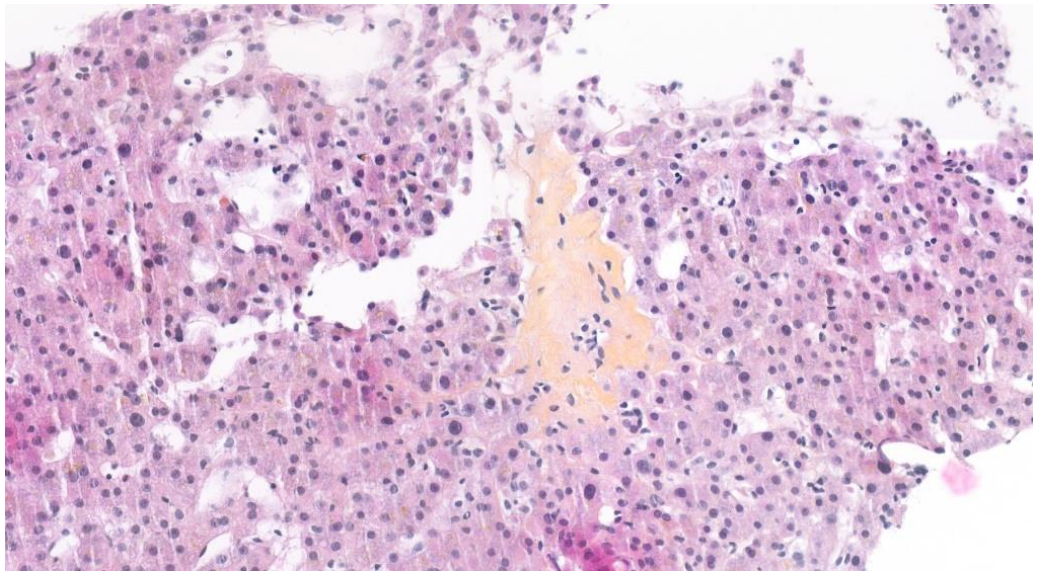

Atteintes vasculaires

- Hyperplasie nodulaire régénérative
- Syndrome d'obstruction sinusoïdale?

Papouin Ann Pathol 2018
De Martin J Hepatol 2018
LoPiccolo Hepatology 2018

Atteintes biliaires: Anti-PD1/PD-L1

- Cholangite lymphocytaire ou à PNN
- Ductopénie
- Prolifération cholangiolaire avec cholangiolite

- Atteinte des grands canaux: fibrose et infiltrat lymphocytaire CD8+

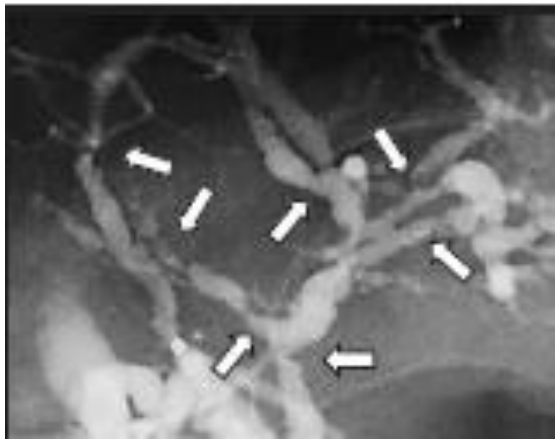

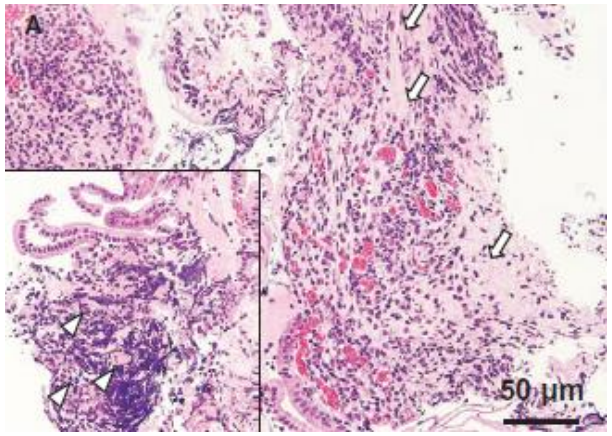

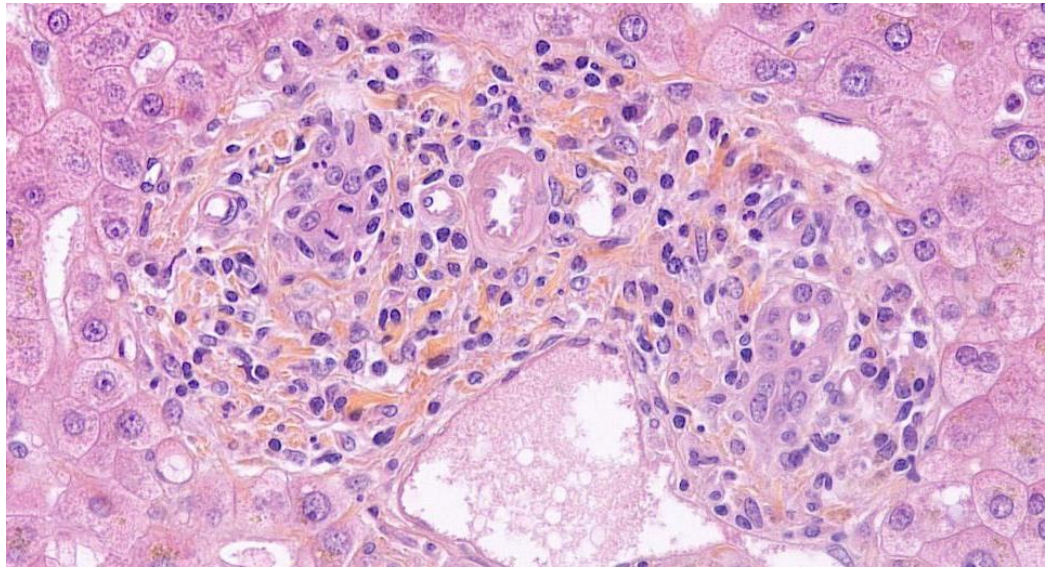

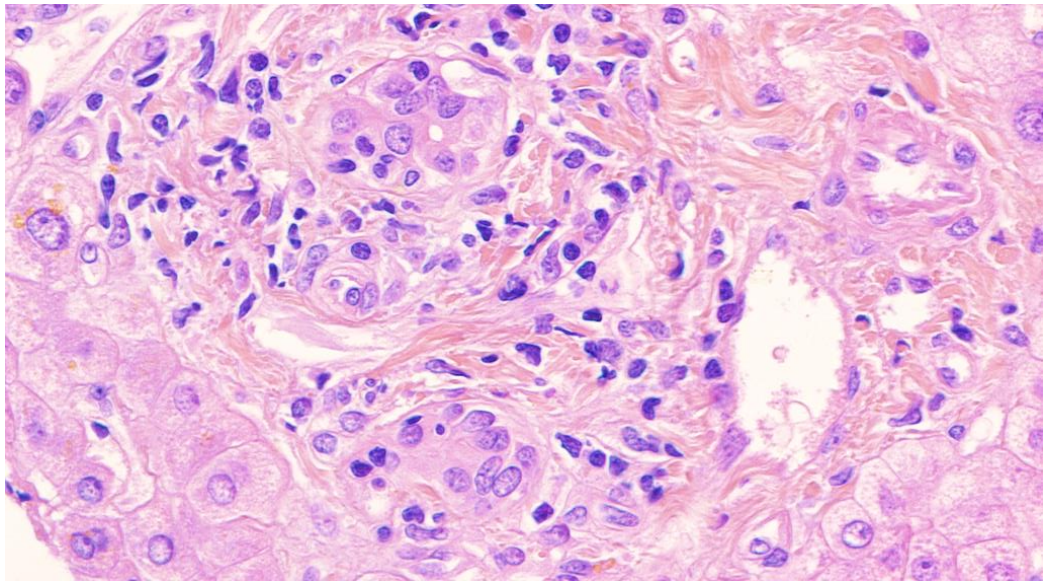

Ogawa Hepatology 2019, De Martin JHED Reports 2020

Atteintes hépatiques: Anti-CTLA4 ± anti-PD1 (1)

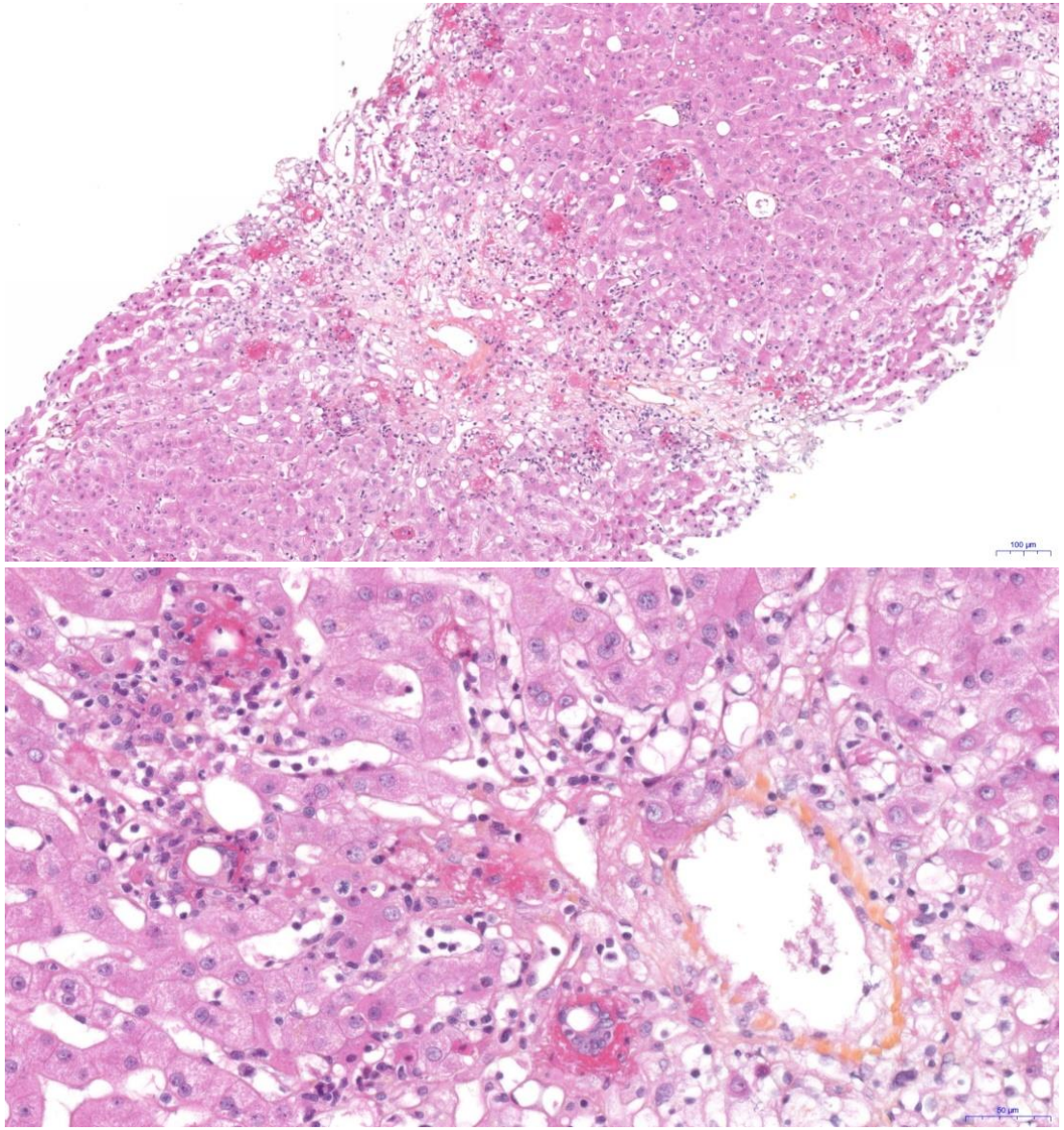

- Hépatite lobulaire avec nécrose ponctuée
- Nécrose confluente centrolobulaire
- Endothélite veineuse centrale
- Lymphocytes, histiocytes
- **Pas de plasmocytes**
- Granulomes
- **Granulomes à anneau de fibrine**
- Signes de régénération hépatocellulaire
- CD8+

Papouin Ann Pathol 2018
Nishida Hepatol Int 2019
De Martin JHED Reports 2020
Peeraphatdit Hepatology 2020

Atteintes hépatiques: Anti-CTLA4 ± anti-PD1 (2)

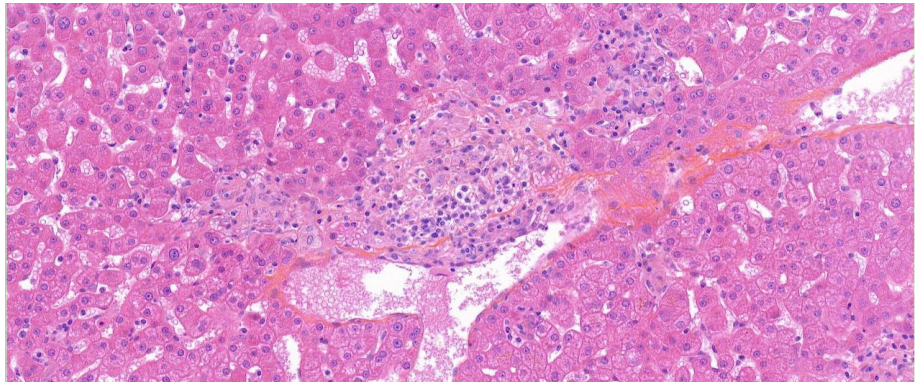

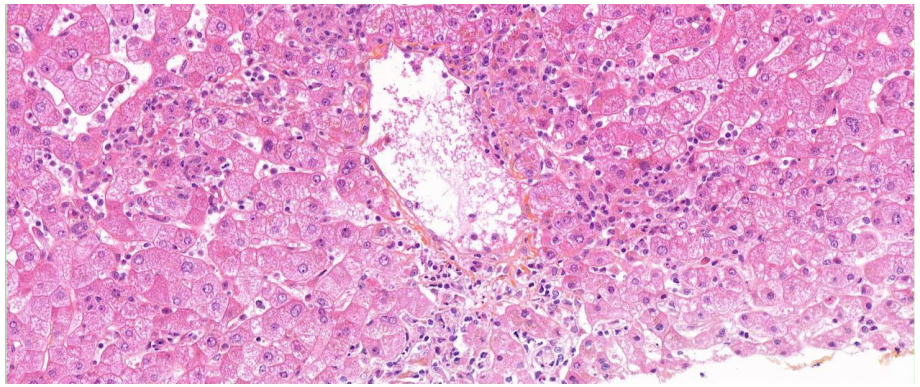

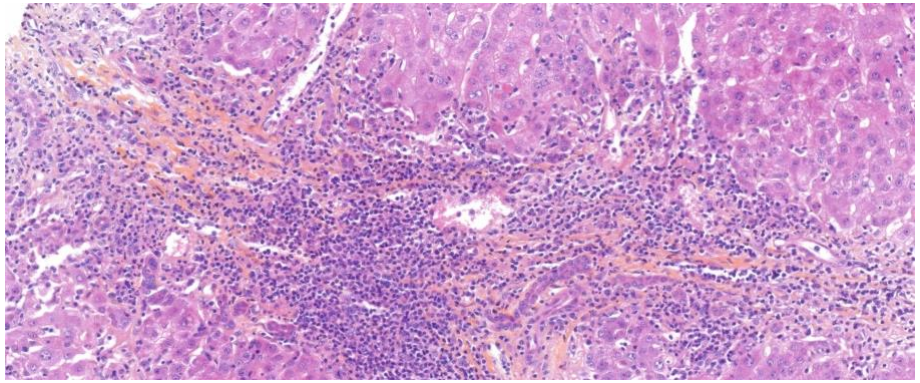

- Granulomes
- Endothélite veineuse centrale
- Chronicité

Papouin Ann Pathol 2018
Nishida Hepatol Int 2019
De Martin JHED Reports 2020
Peeraphatdit Hepatology 2020

Atteintes hépatiques: Apport de la biopsie

- Indication non systématique: ++ si grade ≥ 3 ou diagnostic incertain
- Diagnostics différentiels (causalité)

Localisation métastatique
Hépatite infectieuse (BK,CMV, VHE)
Hépatite médicamenteuse autre
Hépatite auto-immune
Cholangite biliaire primitive

Hépatopathie sous-jacente

Granulomes à anneau de fibrine
Rickettsioses
Brucellose
Hépatite A
EBV
Médicament

HNR/SOS
Chimiothérapie

- Diagnostic de gravité: aide à la décision de corticothérapie

Papouin Ann Pathol 2018
Peeraphatdit Hepatology 2020
De Martin JHED 2020

Atteintes hépatiques: Dg différentiel théorique

Table 5. Comparison of the clinicopathologic features and outcomes of hepatic injury due to ICI-IMH, iAIH, and DI-AIH.

Feature	ICI-IMH	iAIH	DI-AIH
Onset following drug exposure	3–9 weeks	Not applicable	Months to years
Presence of other autoimmune disorders	Data unavailable	25–40%	21%
Mean Peak liver enzymes including jaundice	Usually < 5 ULN, Less than 2% >10 ULN	AST: 154-1031 IU ALT: 185-1141 IU Bili: 2 mg–4 mg	ALT: 291-956 AST: 255-1141 Bili: 4 mg–13 mg
Clinical presentation	Most commonly asymptomatic on routine monitoring	20% present with Acute hepatitis, others are insidious	Insidious
Autoimmune Serology	Absent or rare	Type I: ANA (70%–80%); SMA (34%–45%); Anti-LKM1 (3%)	ANA positivity 83% SMA (16%–50%)
Histology	CTLA-4: panlobular hepatitis with centrilobular necrosis, granulomatous hepatitis with fibrin ring granulomas, central vein endothelitis. PD-1/L1: lobular hepatitis with centrilobular necrosis, periportal inflammation however no fibrin ring granulomas. Rarely cholestatic injury with ductopenia.	Interface hepatitis with lymphocytic/ lymphoplasmacytic infiltrate, rosettes, and emperipolesis (presence of an intact cell within the cytoplasm of another cell)	Indistinguishable from iAIH
Immunohistochemistry	Usually CD3+ and CD8+	Usually CD4+ and CD20+	Indistinguishable from iAIH
Response to steroids	88% for grade 3 or 4 hepatitis.	20% achieve complete remission, 80% require on going immunosupression due to relapse on withdrawal	Resolves on withdrawal of the agent in 40% patients, 60% required steroids but rarely relapsed after withdrawal
Citations	[29], [64], [69], [77–80]		

Note: ICI-IMH = immune-mediated hepatitis from checkpoint inhibitors; iAIH = idiopathic autoimmune hepatitis; DI-AIH = drug-induced autoimmune hepatitis

Jennings Expert Opinion on Drug Metab and Tox 2019

Atteintes hépatiques: « dans la vraie vie »

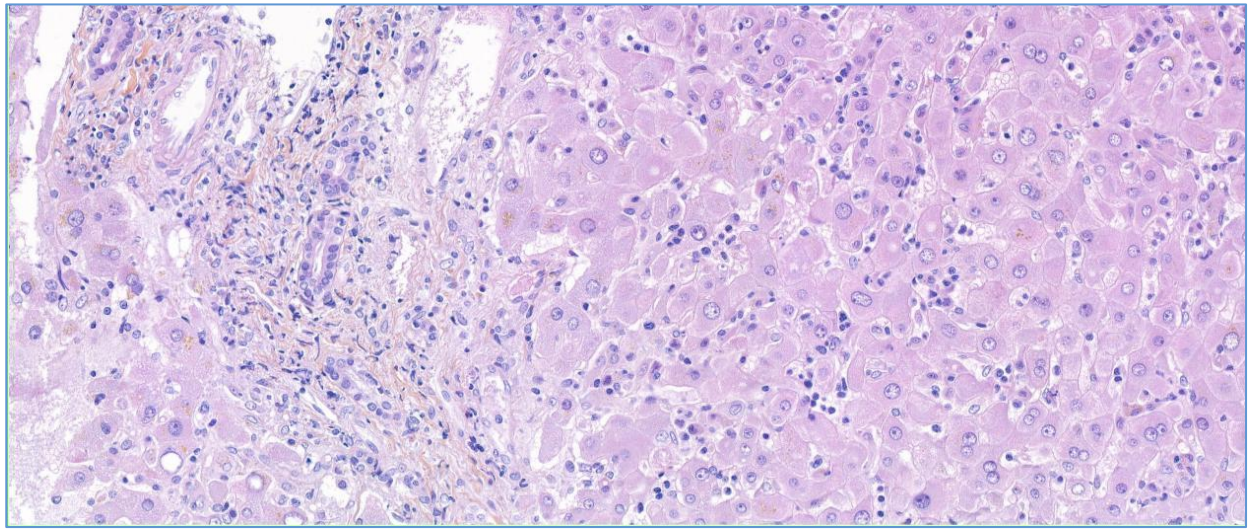

Hépatite E chez un patient sous anti-PD1

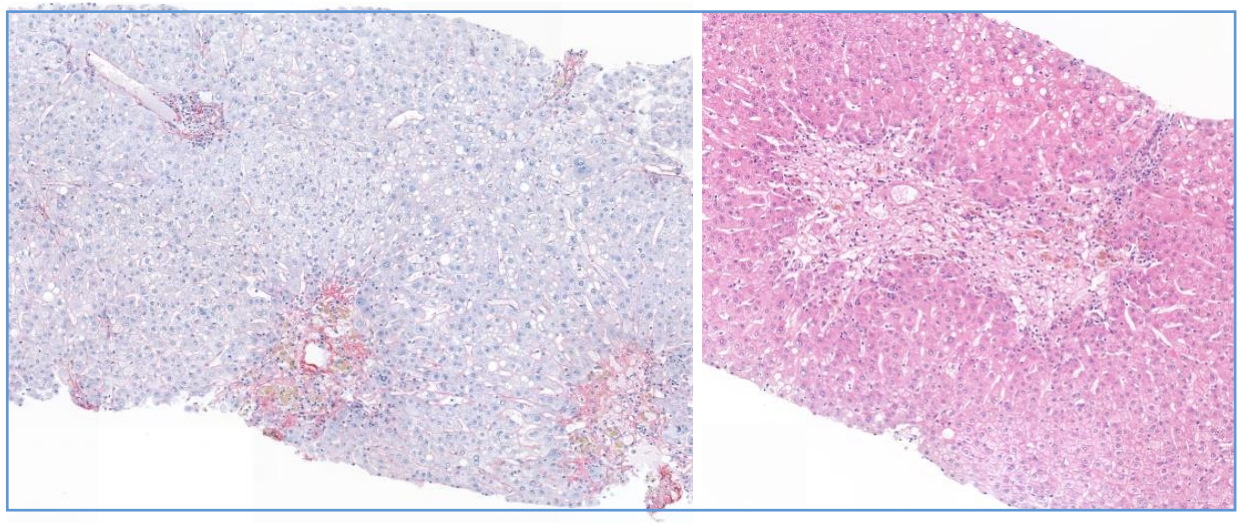

Hépatite chez un patient sous anti-PD1
et Imatinib

Atteintes hépatiques: Evolution

- Résolution spontanée à l'arrêt du traitement
- Résolution sous corticothérapie
- Nécessité d'une autre immunosuppresseur
- Reprise de l'immunothérapie anti-PD1/anti-PDL1 >>CTLA4: 20% de récidive

De Martin JHED Reports 2020

Atteintes hépatiques immuno-induites

Take home message

- Complication rare
- Plus fréquente et plus grave sous anti-CTLA4 ou traitement combiné
- Association à des irAEs d'autres organes
- Histologie hétérogène
- Spécificité relative: granulomes à anneau de fibrine, cholangite
- Biopsie recommandée pour grade ≥ 3 ou diagnostic incertain
- Evolution vers la chronicité?
- Discussion pluridisciplinaire++