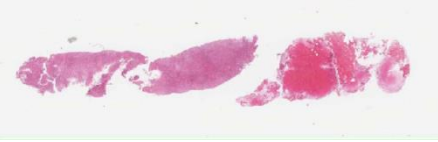
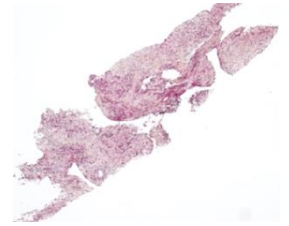


Microbiopsie ganglionnaire : Intérêts et limites en hématopathologie



Professeur Alexandra Traverse-Glehen



Université Claude Bernard



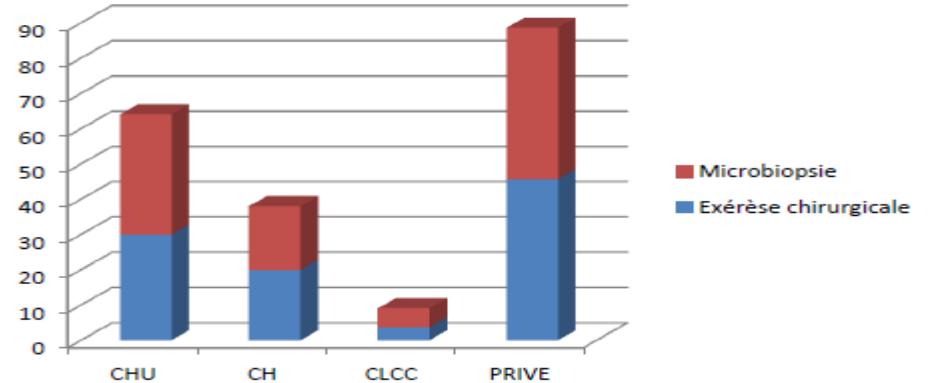
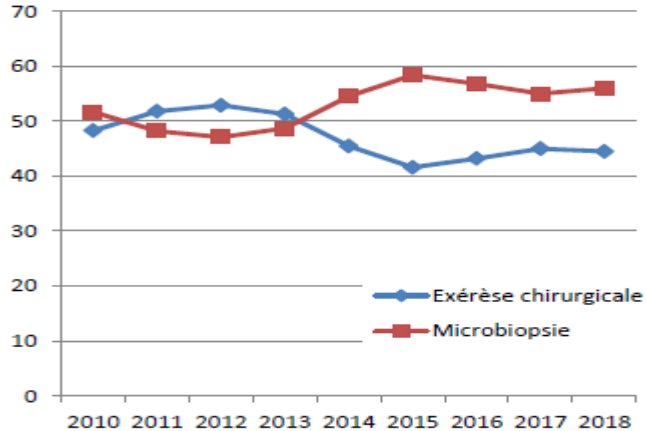
Lyon 1



**Carrefour
Pathologie**
2019

Lymphopath 2010-2018

n=85583



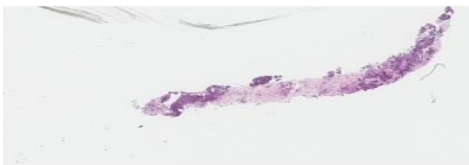
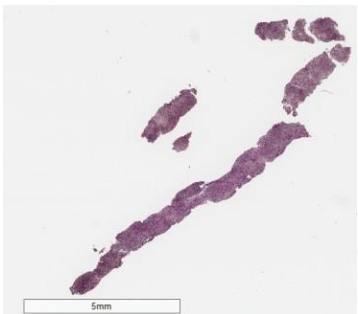
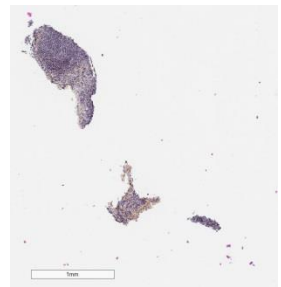
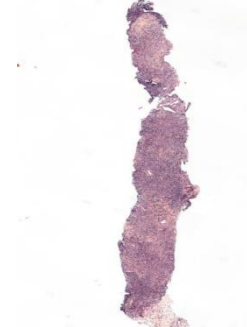
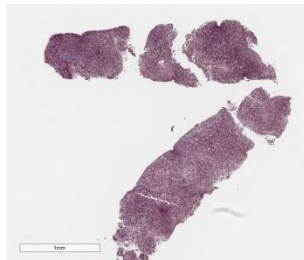
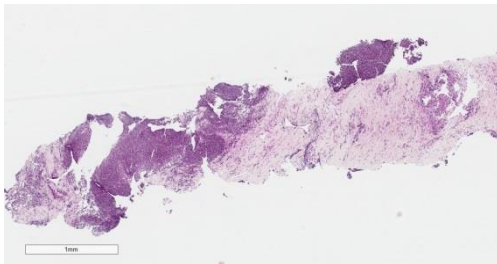
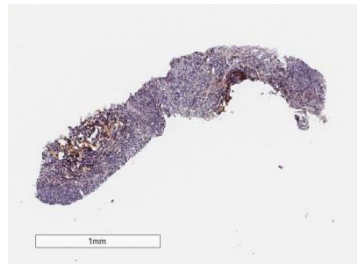
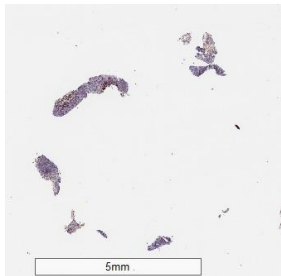
*D'après Camille Laurent, Philippe Gaulard, Pierre Brousset
Nadia Amara, Virginie Fataccioli*



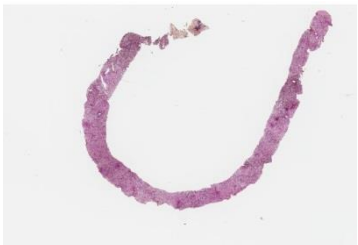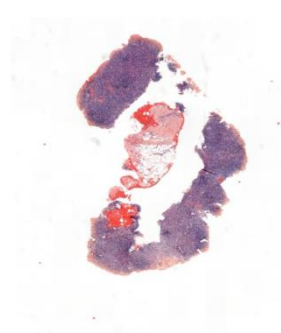
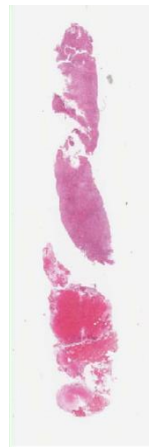
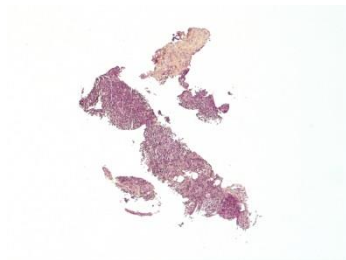
Objectifs



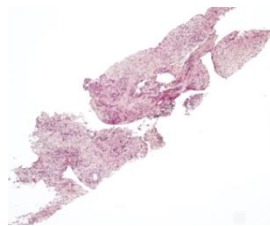
- **Prise en charge** d'une microbiopsie dans la pathologie ganglionnaire lymphatique
 - Mode de de prélèvement, technique, prise en charge, limites, analyse moléculaire...
- **Diagnostic positif**, contexte, potentiel, **limites**, gain pour le patient
- **Attentes du clinicien** et les **indications**
- **Pièges à éviter**



7mm



5mm



AIP / Carrefour Pathologie, Paris, 7 novembre 2019

Emmanuel Bachy, *Lyon*

Véronique Meignin, *Saint Louis*

Christiane Copie Bergman, *Créteil*

Marie Parrens, *Bordeaux*

Jean François Emile, *Ambroise Paré*

Julien Moroch, *Tenon*

Céline Bossard, *Nantes*

Juliette Fontaine, *Lyon*

