Update on Emerging Sinonasal Tumors

Justin A. Bishop, MD
Chief of Anatomic Pathology
UT Southwestern Medical Center
Dallas, Texas
@ENTPathology

Case Presentation

21-year-old man with nasal obstruction, nosebleeds, and pain.


17

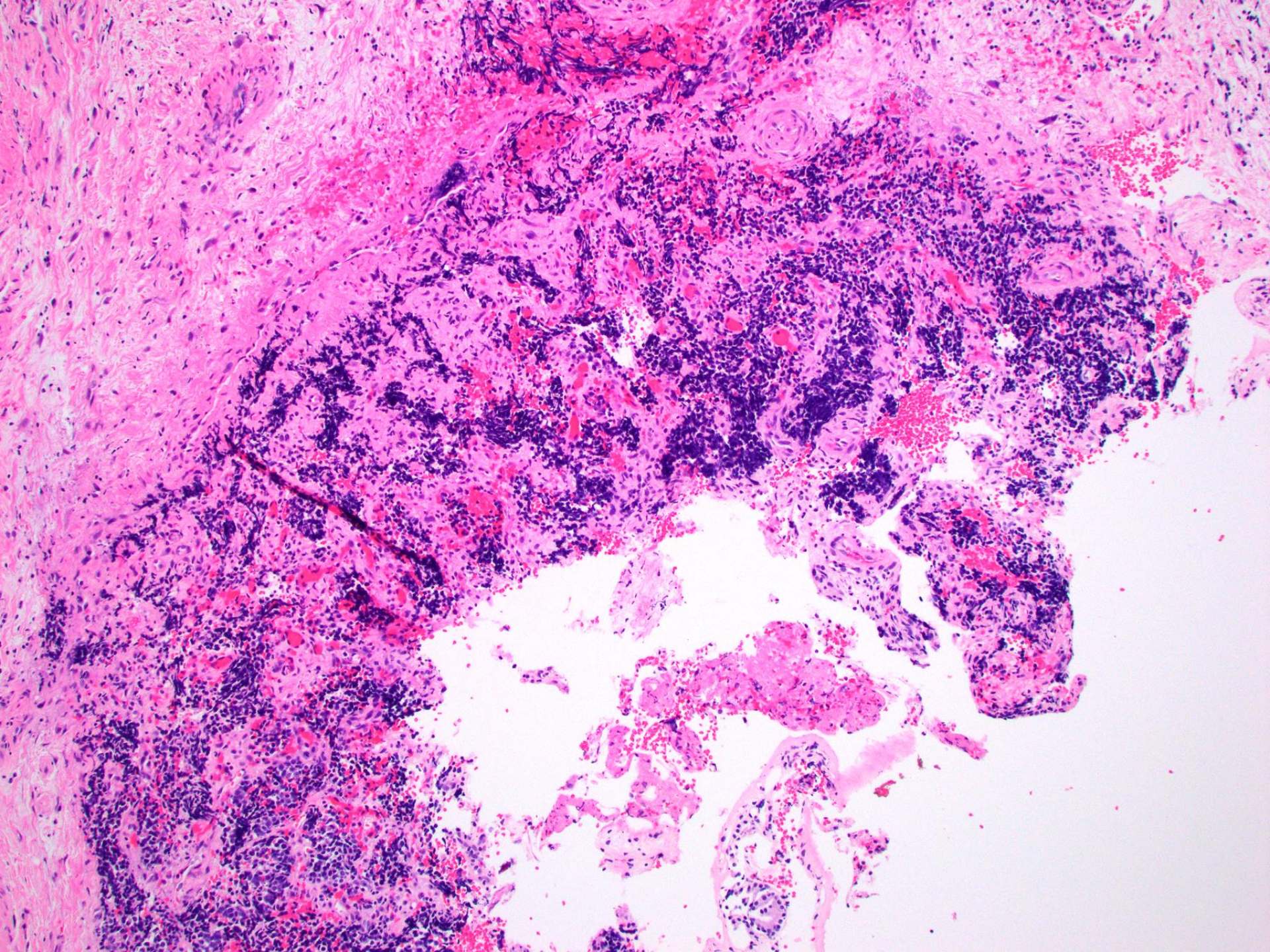

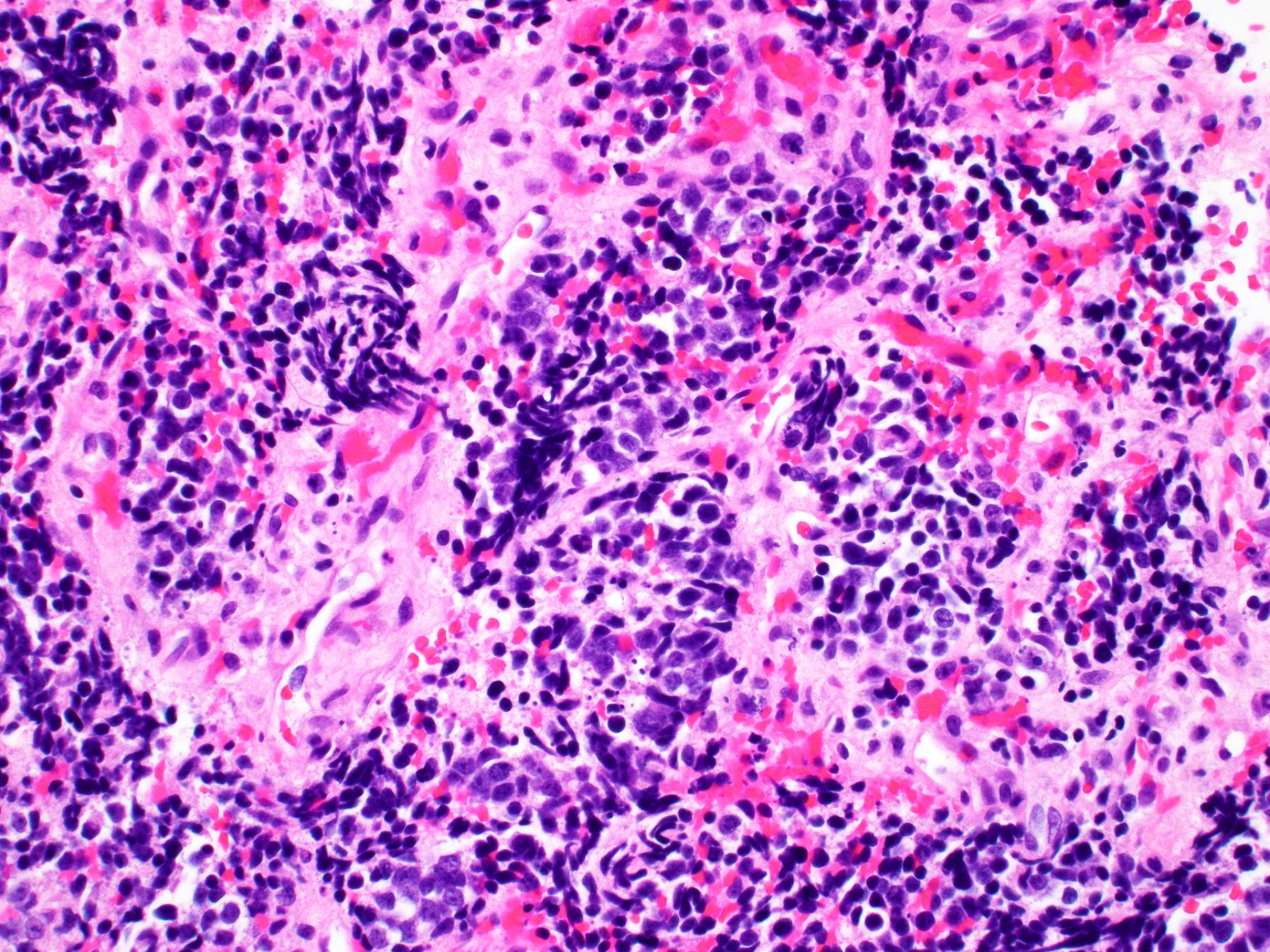

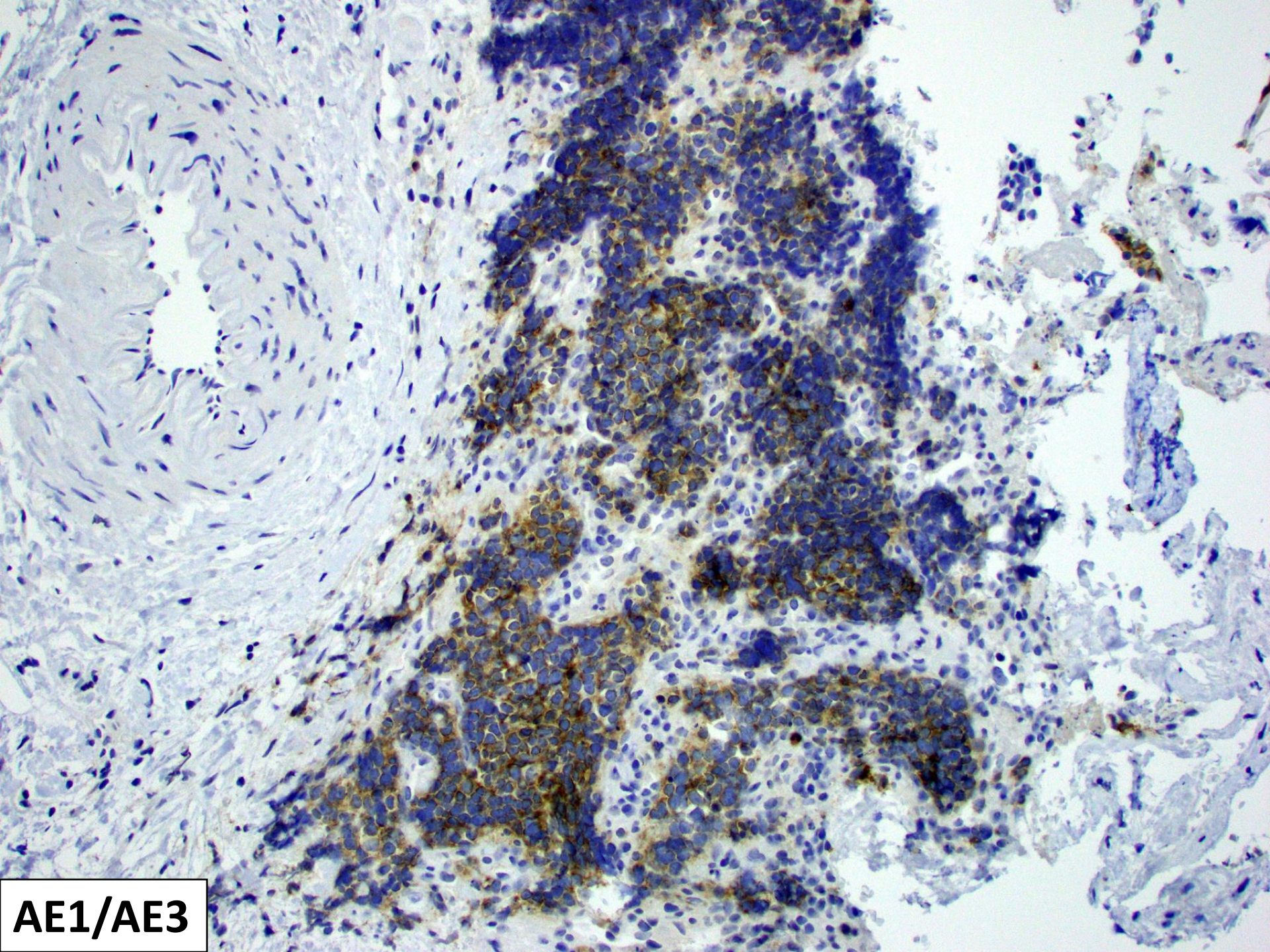
AE1/AE3

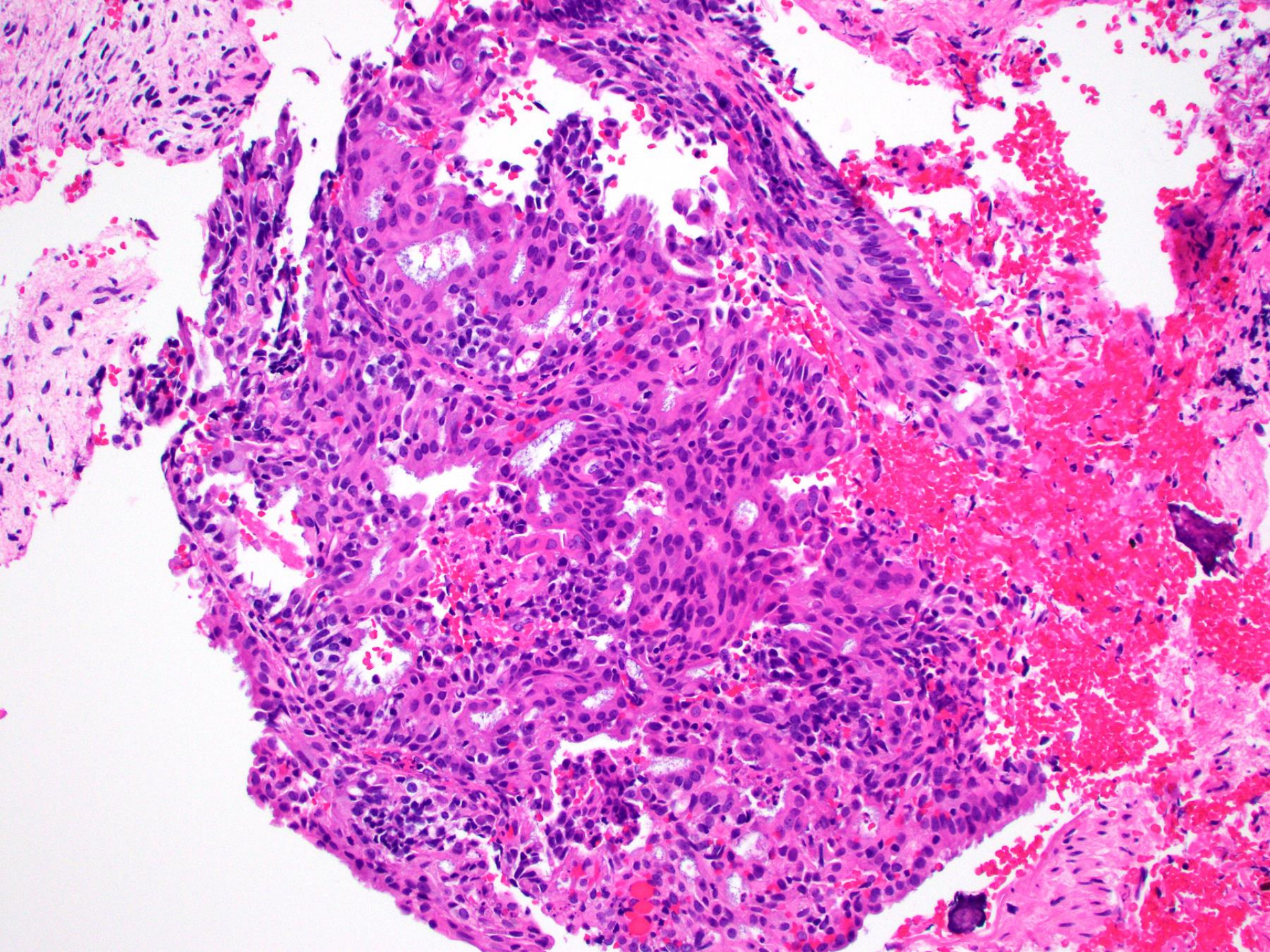

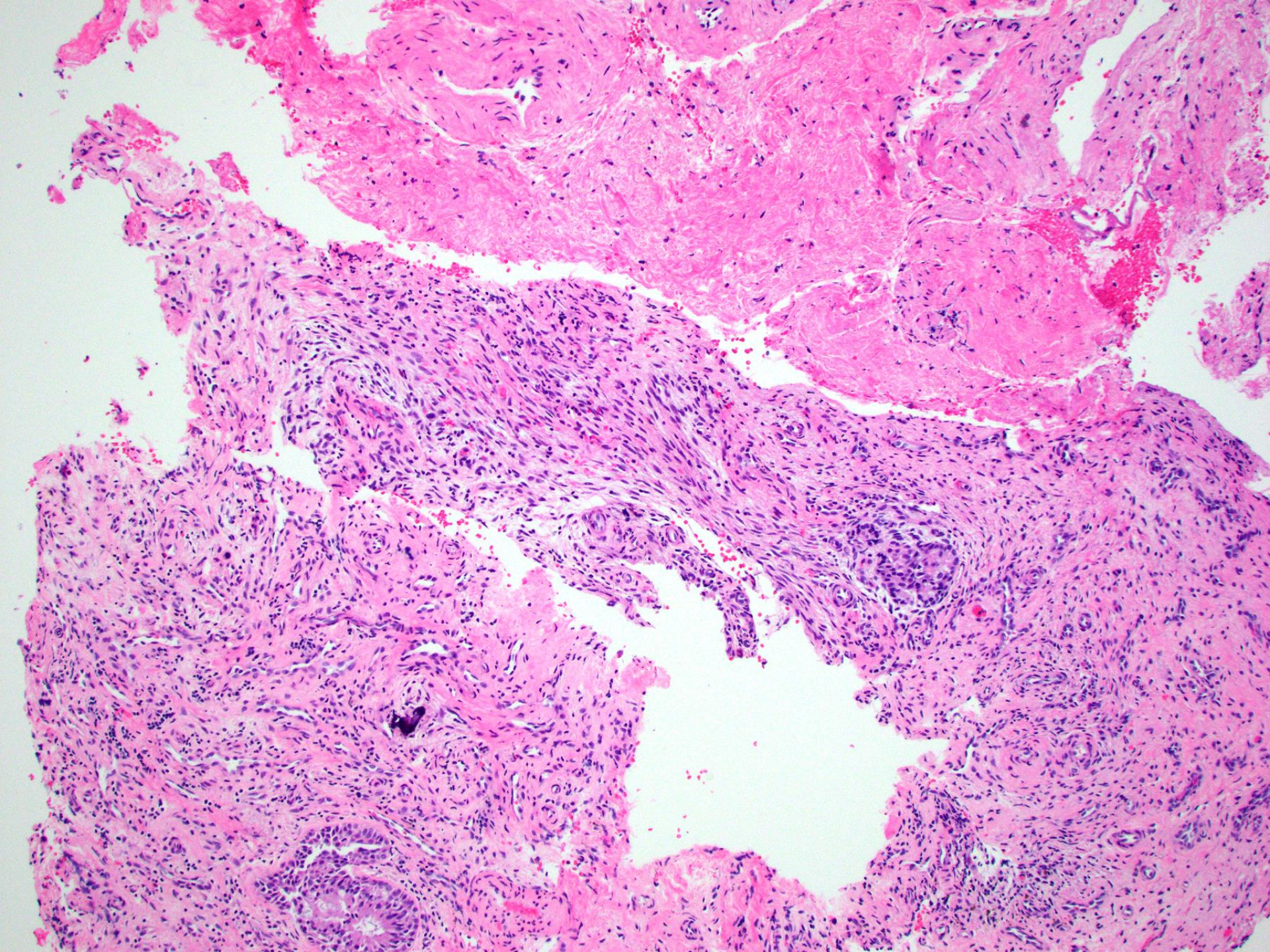

Diagnosis?

Sinonasal Tumors

- Many challenges:
  - Overlapping clinical histories
  - Overlapping ages
  - Overlapping histology
  - Small biopsies
  - Abundant artifact

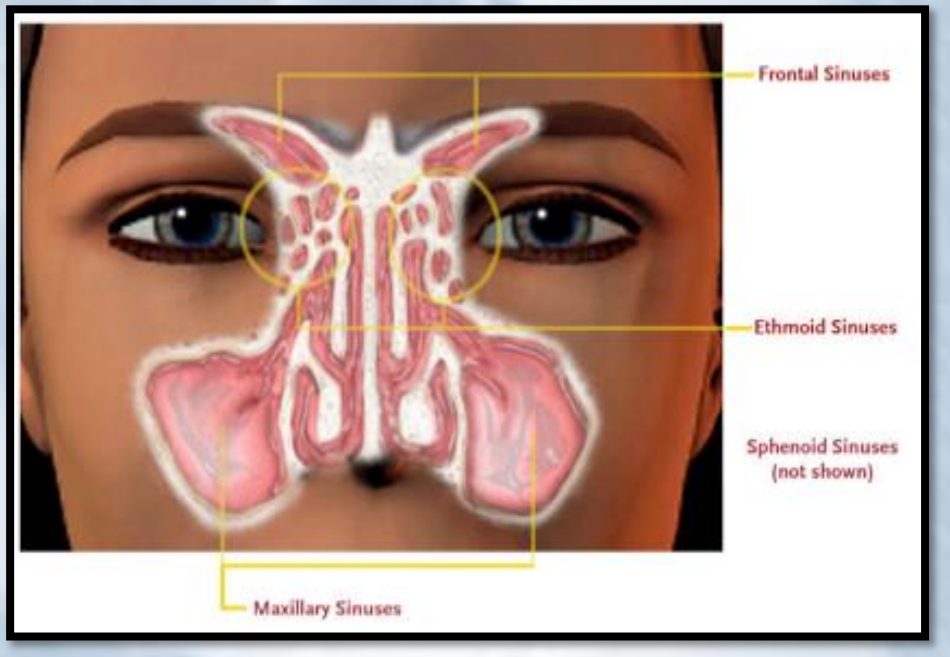

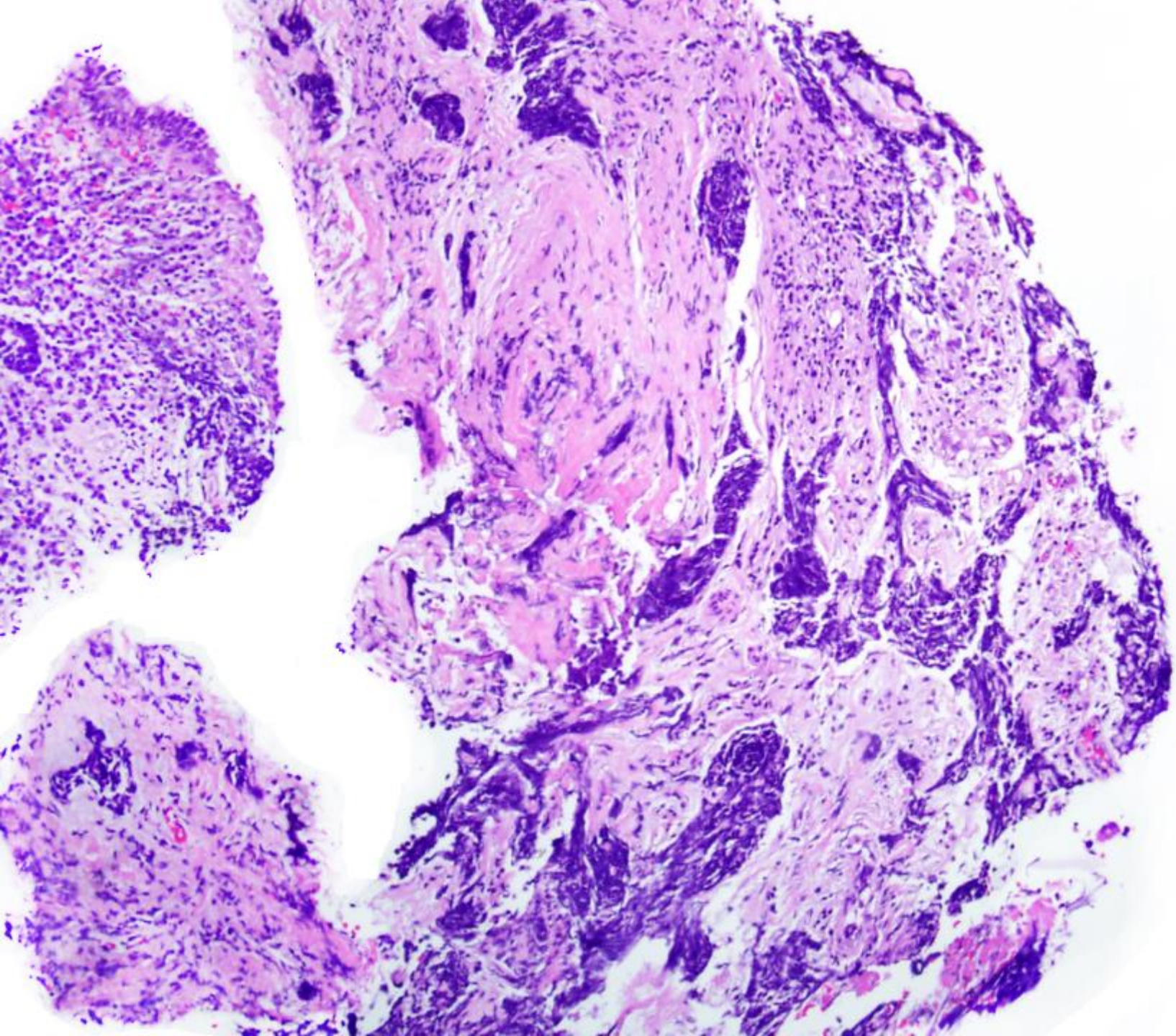

Sinonasal Tumors

- Many challenges:
  - Overlapping clinical histories
  - Overlapping ages
  - Overlapping histology
  - Small biopsies
  - Abundant artifact
  - ***New entities and concepts affecting classification***

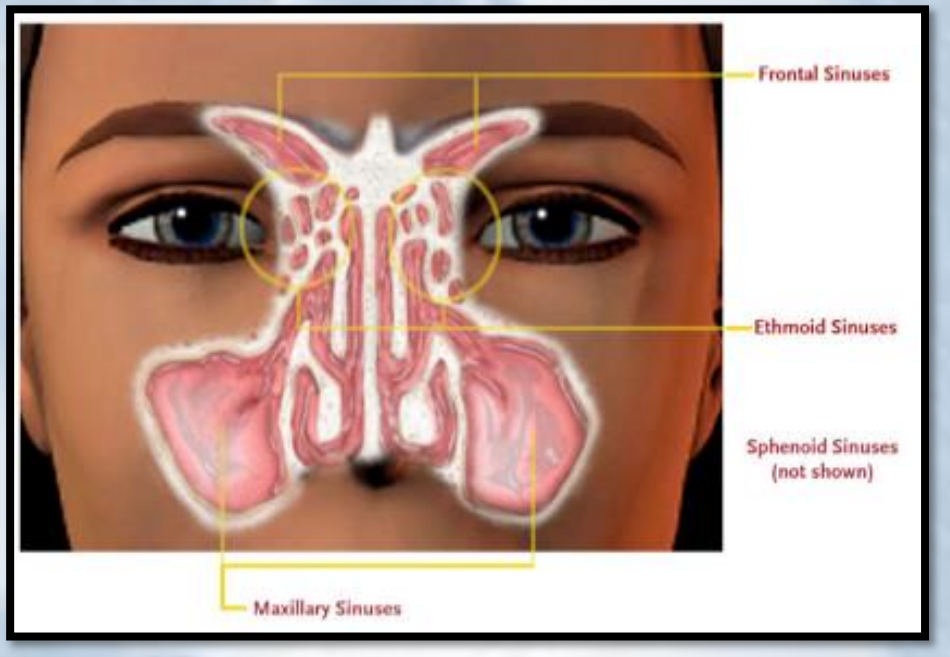

SNUC

Lymphoepithelial CA

Neuroendocrine carcinoma

Adenocarcinoma

Teratocarcinosarcoma

Squamous Cell Carcinoma

Sinonasal Squamous Cell Carcinoma

- Keratinizing and non-keratinizing
- Maxillary sinus > nasal cavity > ethmoid
- Like other HNSCC except
  - Rarer
  - Risk factors are not well understood

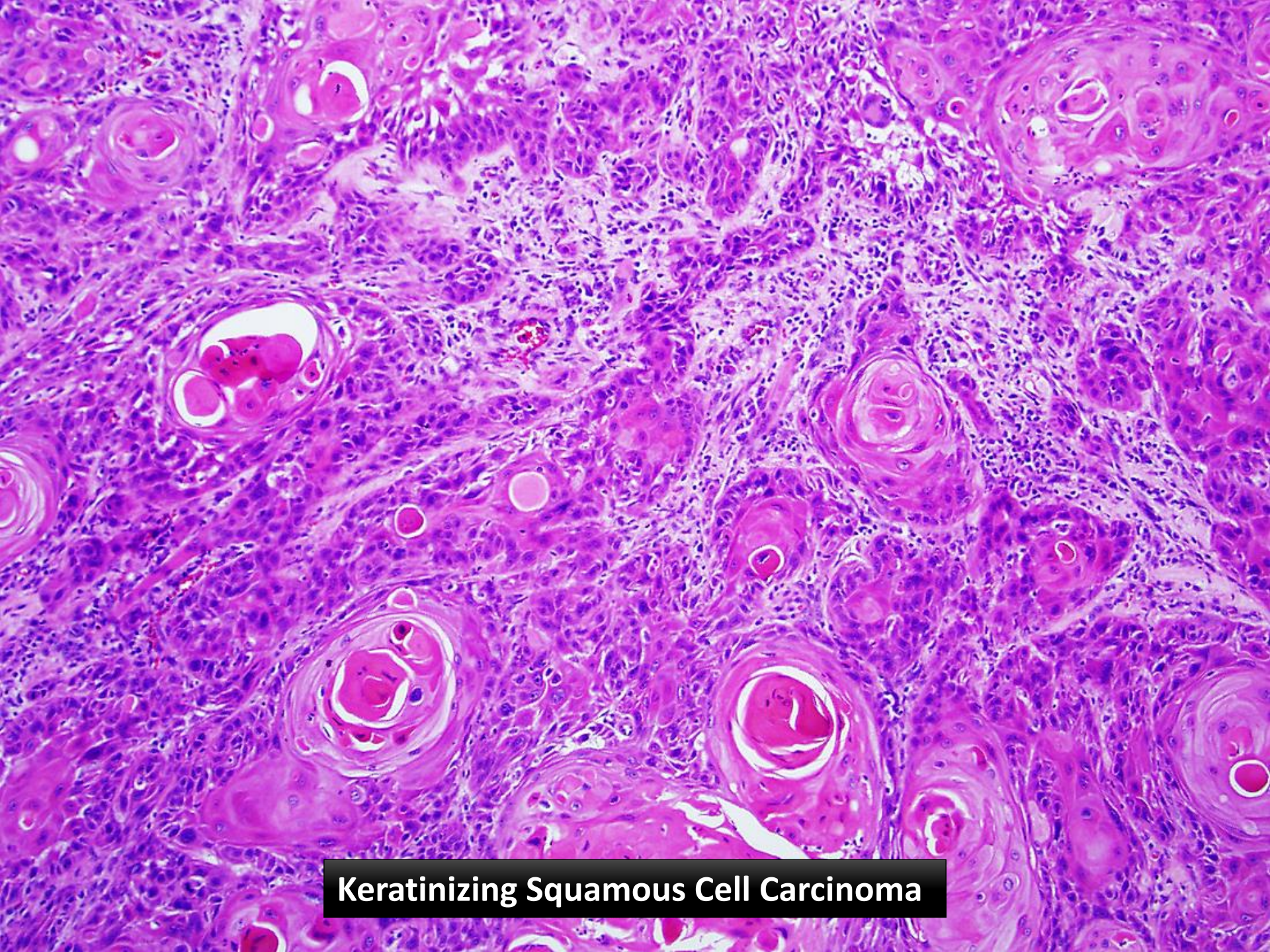
Keratinizing Squamous Cell Carcinoma


Non-keratinizing Squamous Cell Carcinoma

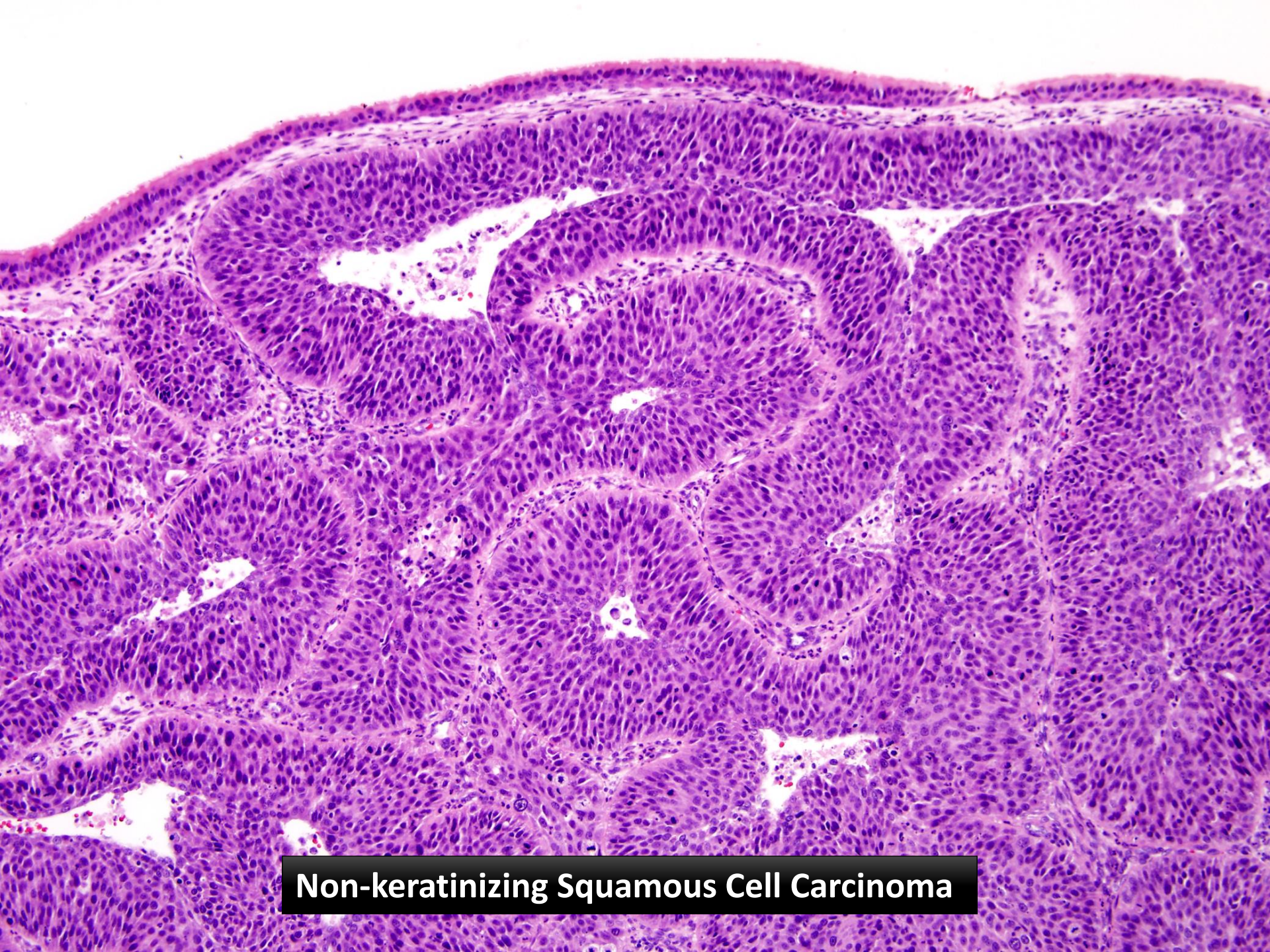
Non-keratinizing Squamous Cell Carcinoma

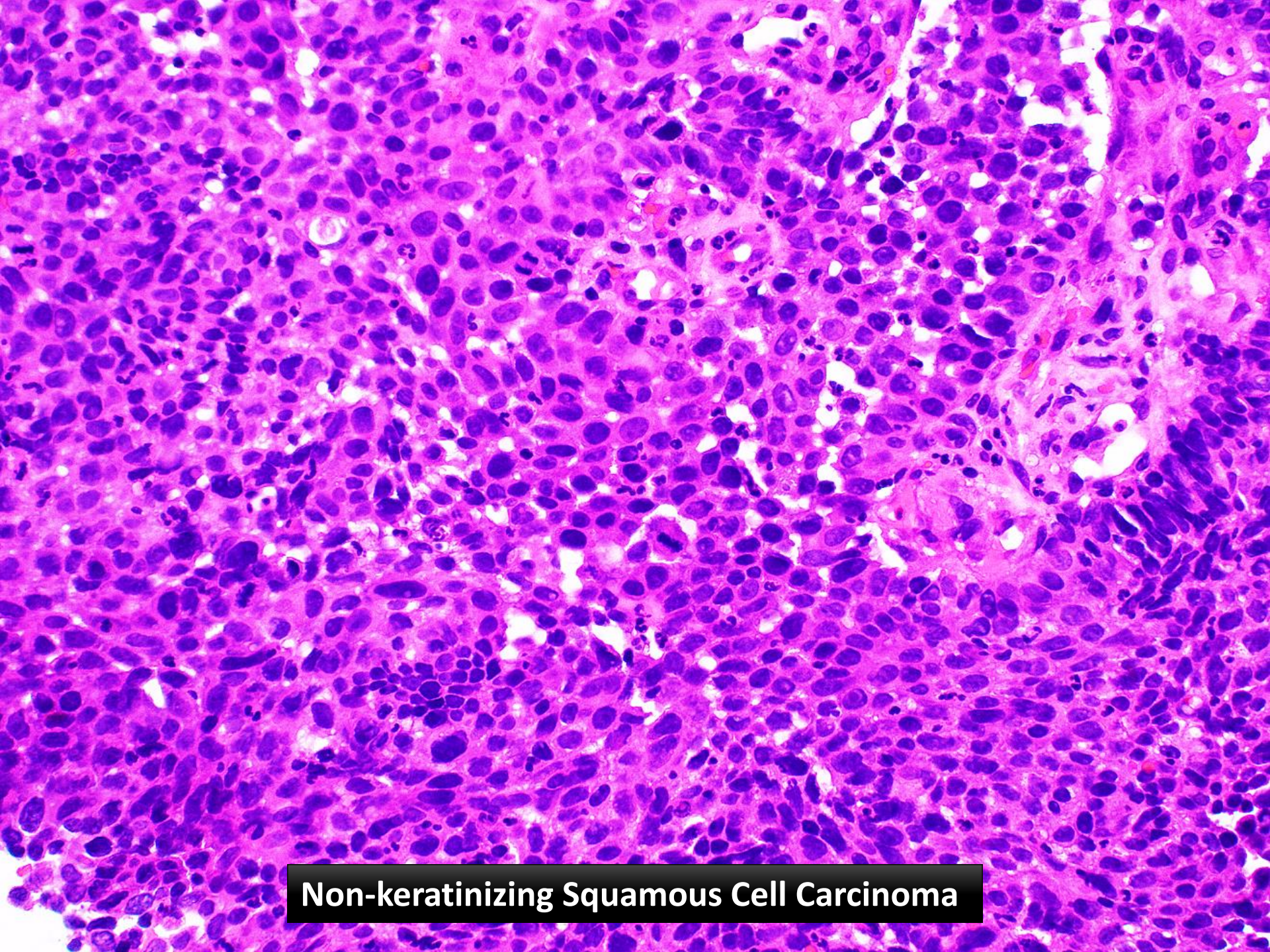
Non-keratinizing Squamous Cell Carcinoma

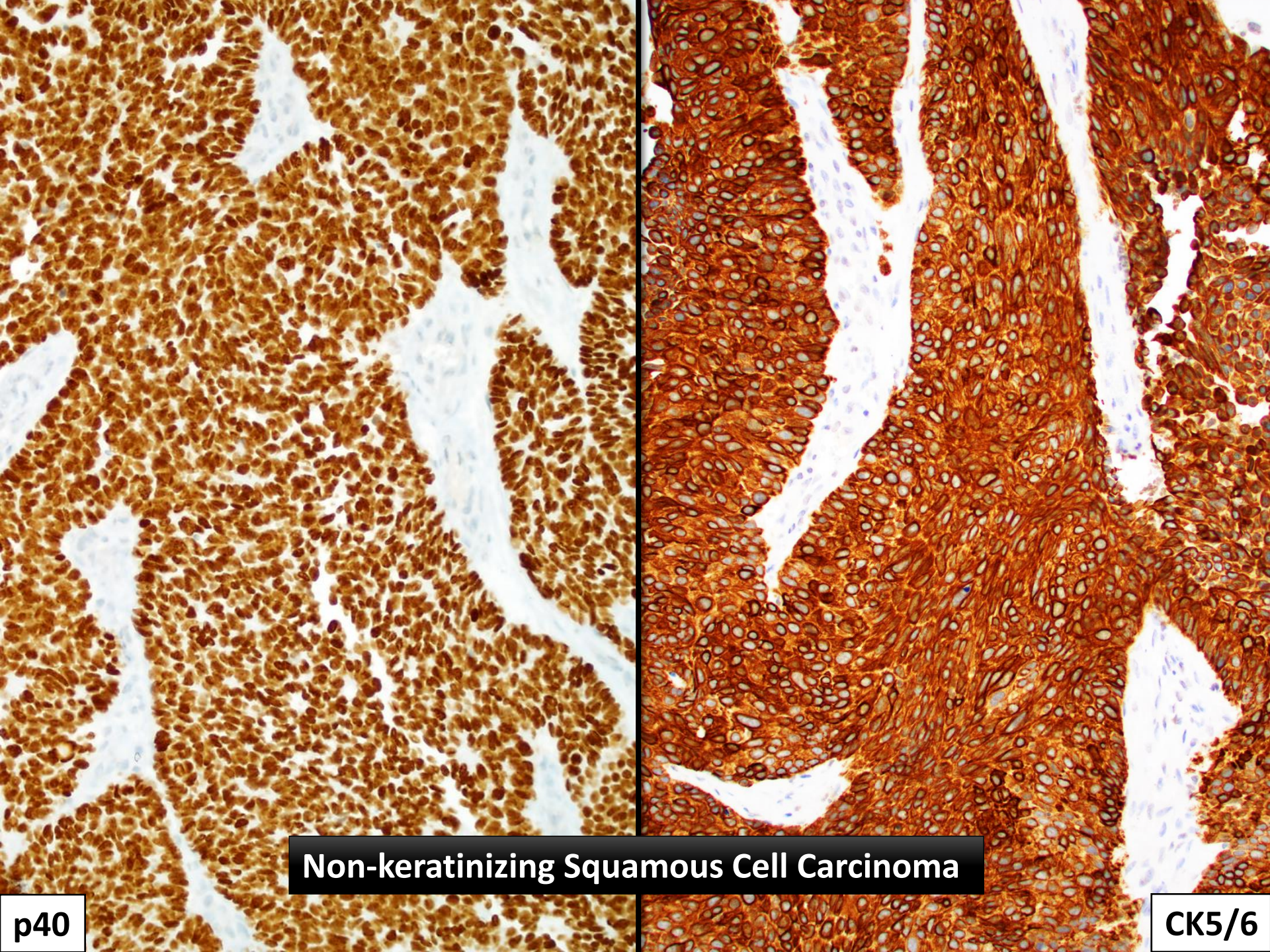
Non-keratinizing Squamous Cell Carcinoma
p40
CK5/6

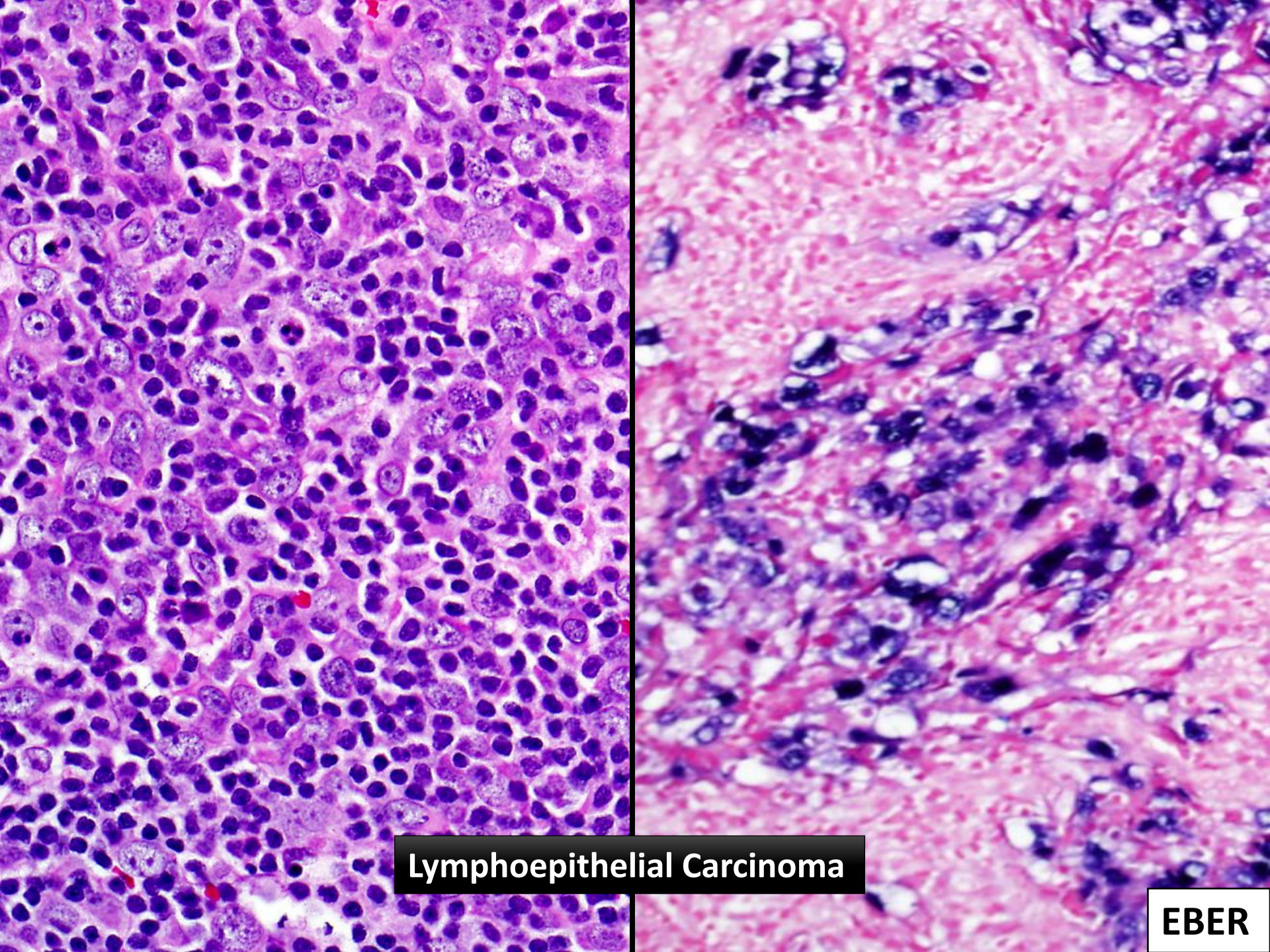
Lymphoepithelial Carcinoma
EBER

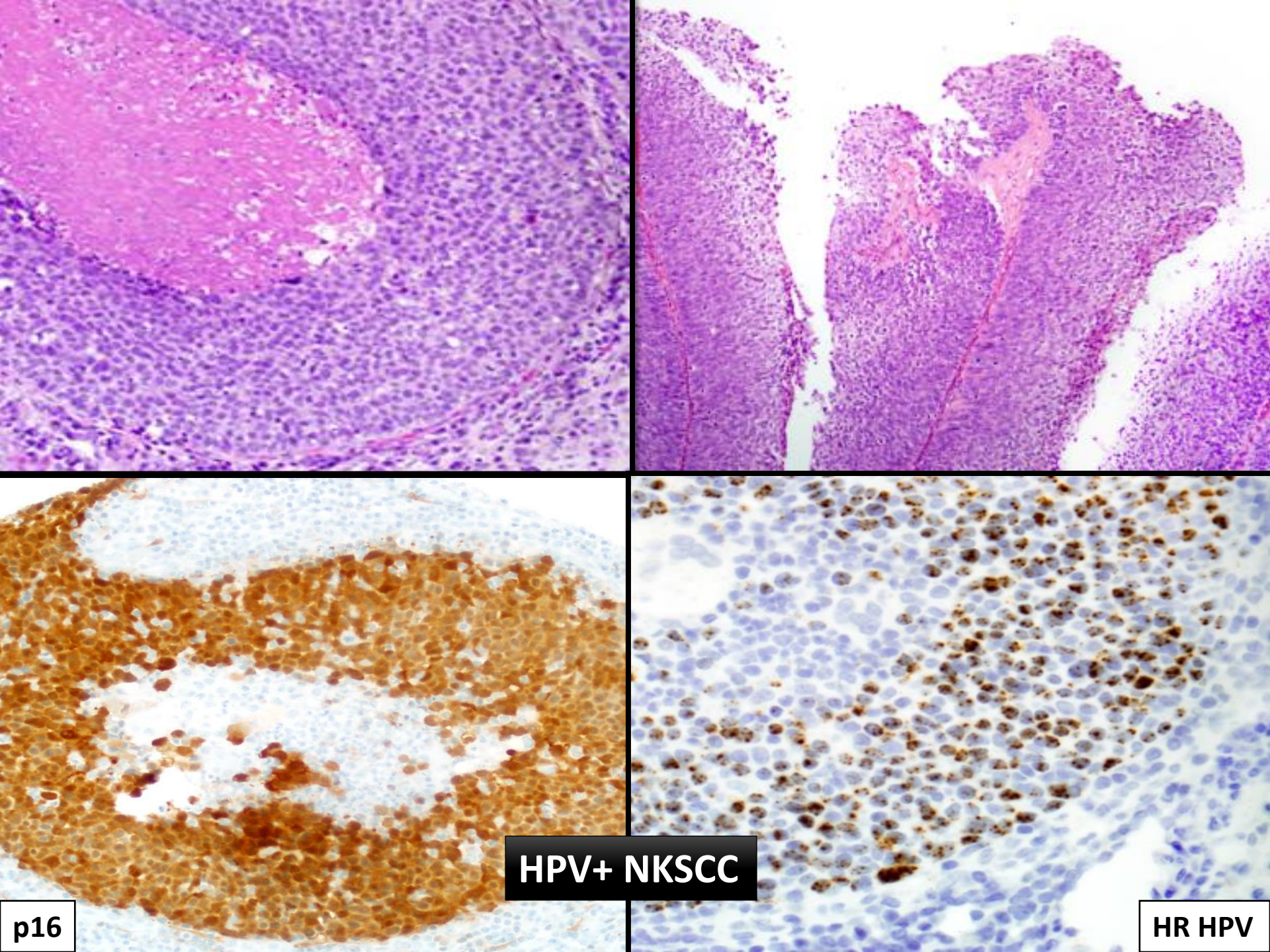
HPV+ NKSCC
p16
HR HPV

HPV-related Multiphenotypic Sinonasal Carcinoma

- Provisional entity in 2017 WHO, now well-established.
- Sinonasal only, especially nasal cavity (turbinate)
- Adults (mean, 54), slight female predominance
- Harbors high-risk HPV, especially 33 (about 80%)
- Paradoxically indolent behavior
  - Recurrences common, can be very late
  - Regional and distant metastases, tumor deaths rare

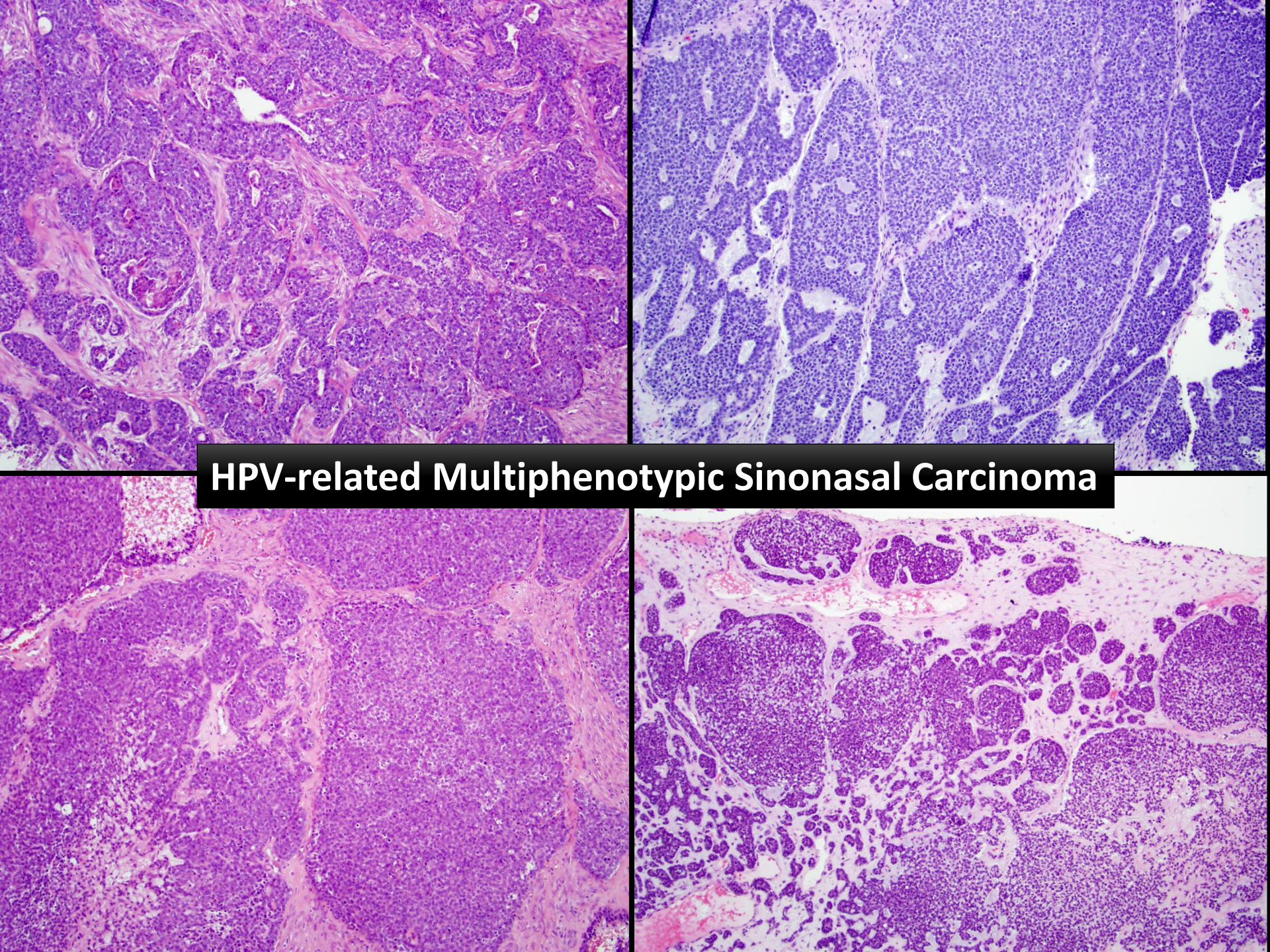
HPV-related Multiphenotypic Sinonasal Carcinoma

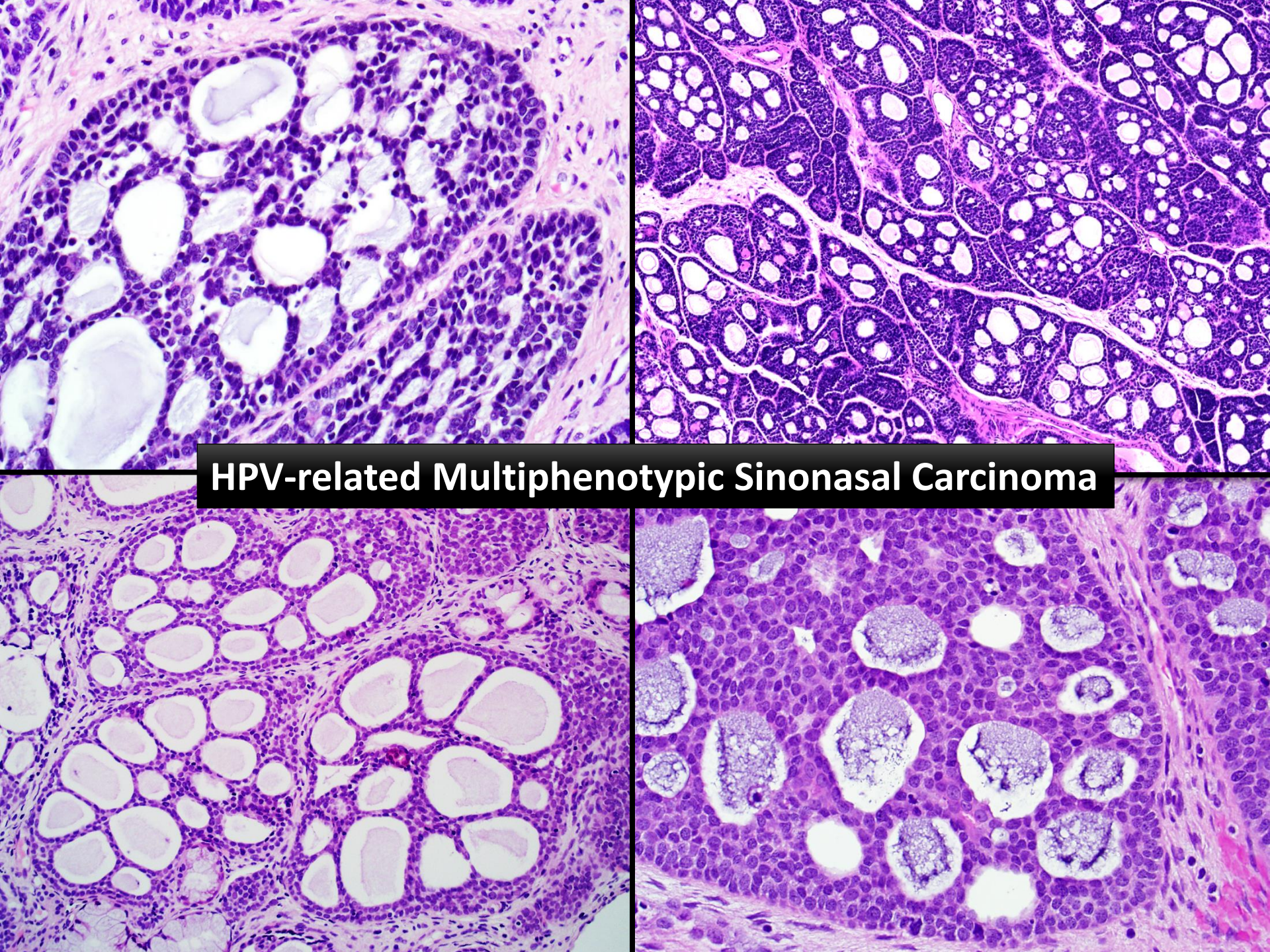
HPV-related Multiphenotypic Sinonasal Carcinoma

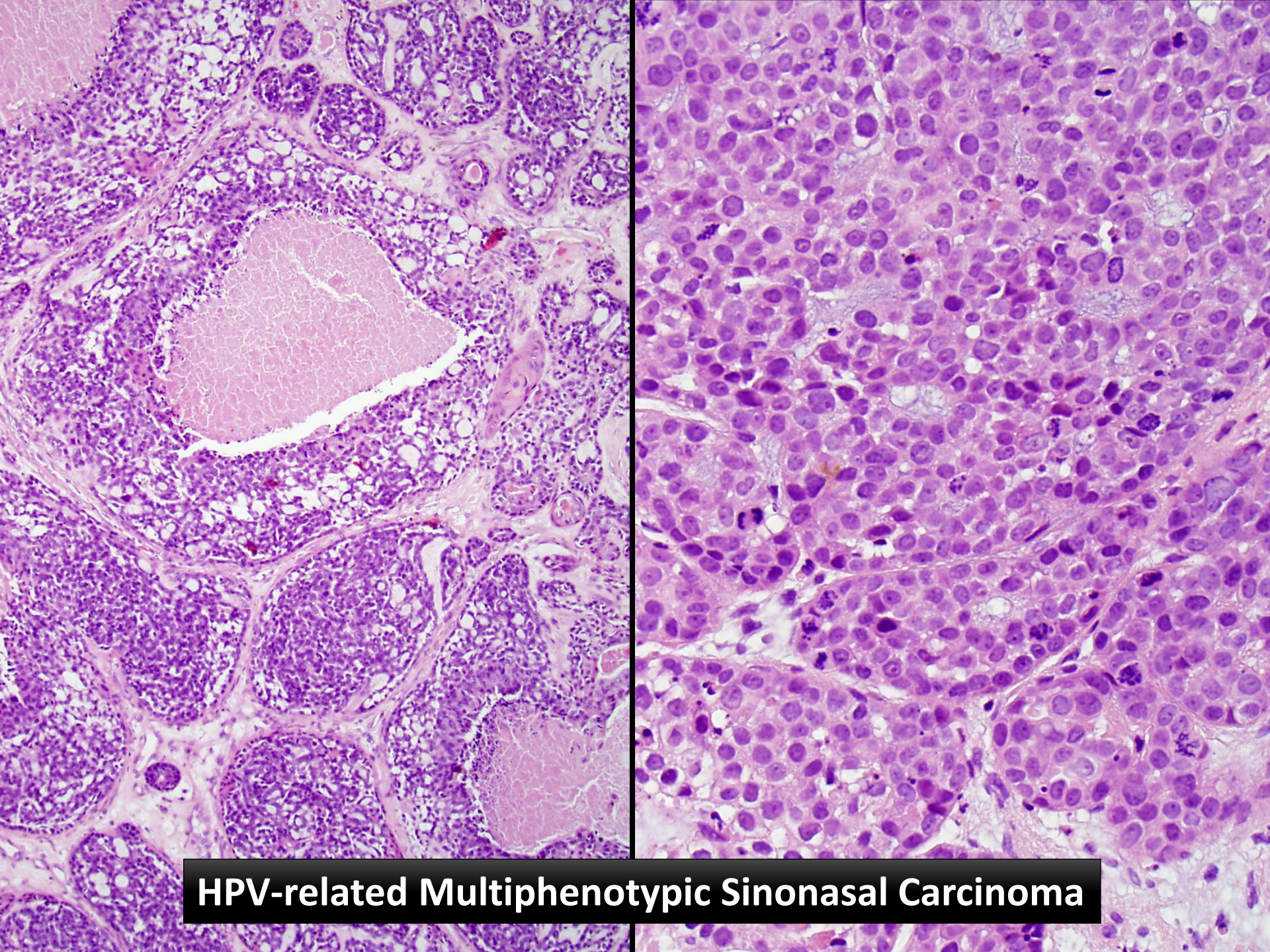
HPV-related Multiphenotypic Sinonasal Carcinoma

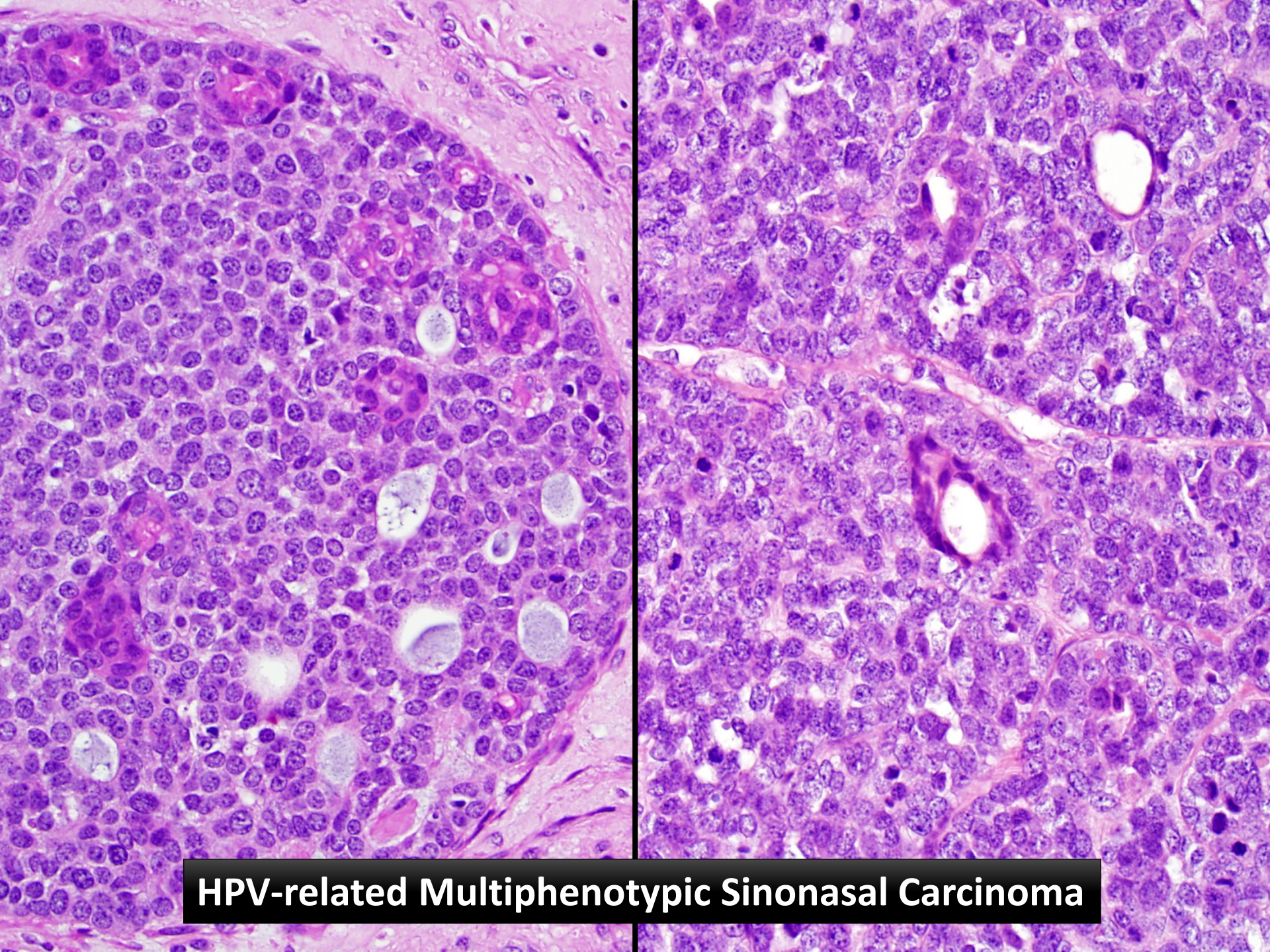
HPV-related Multiphenotypic Sinonasal Carcinoma

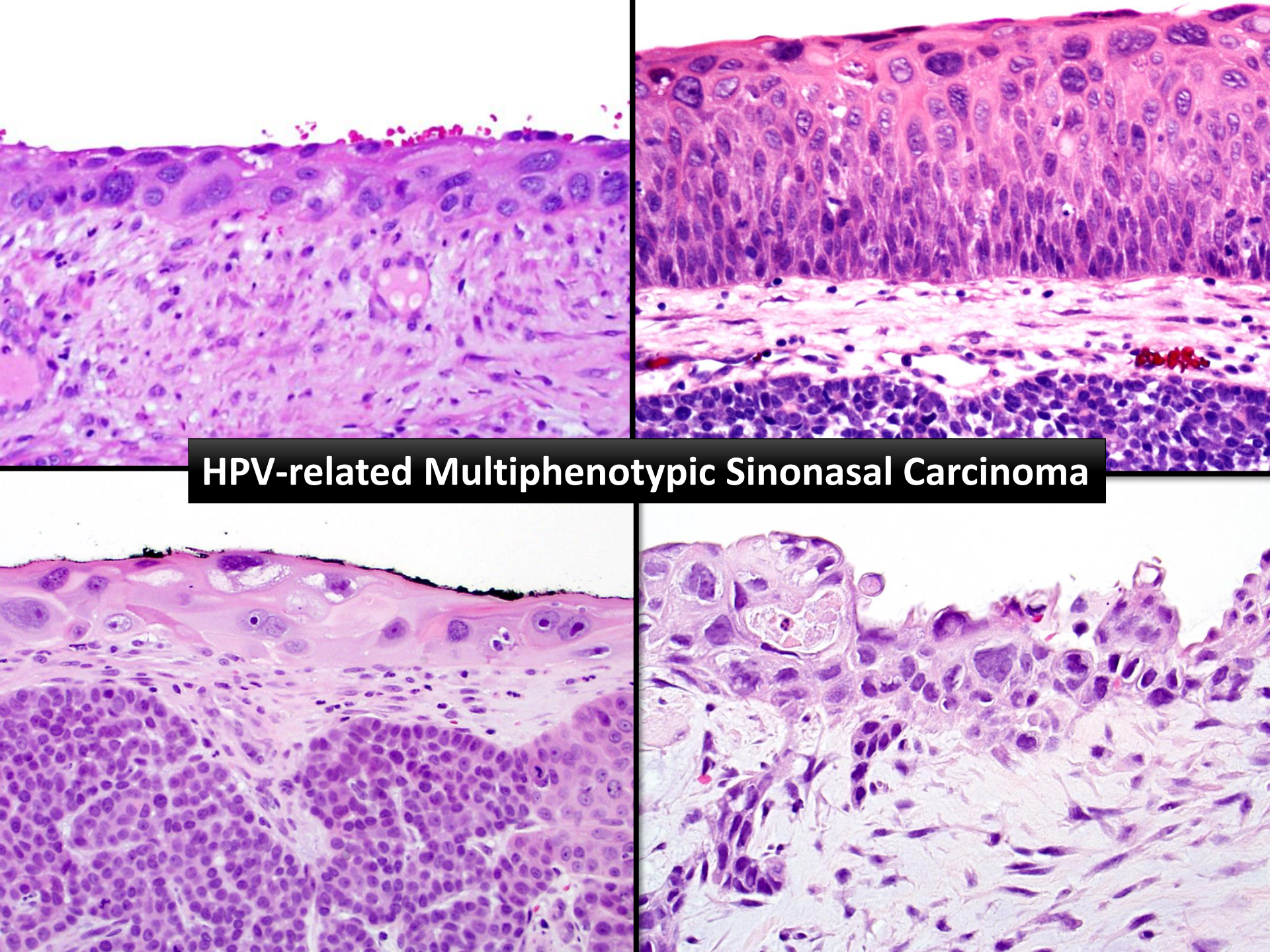
HPV-related Multiphenotypic Sinonasal Carcinoma

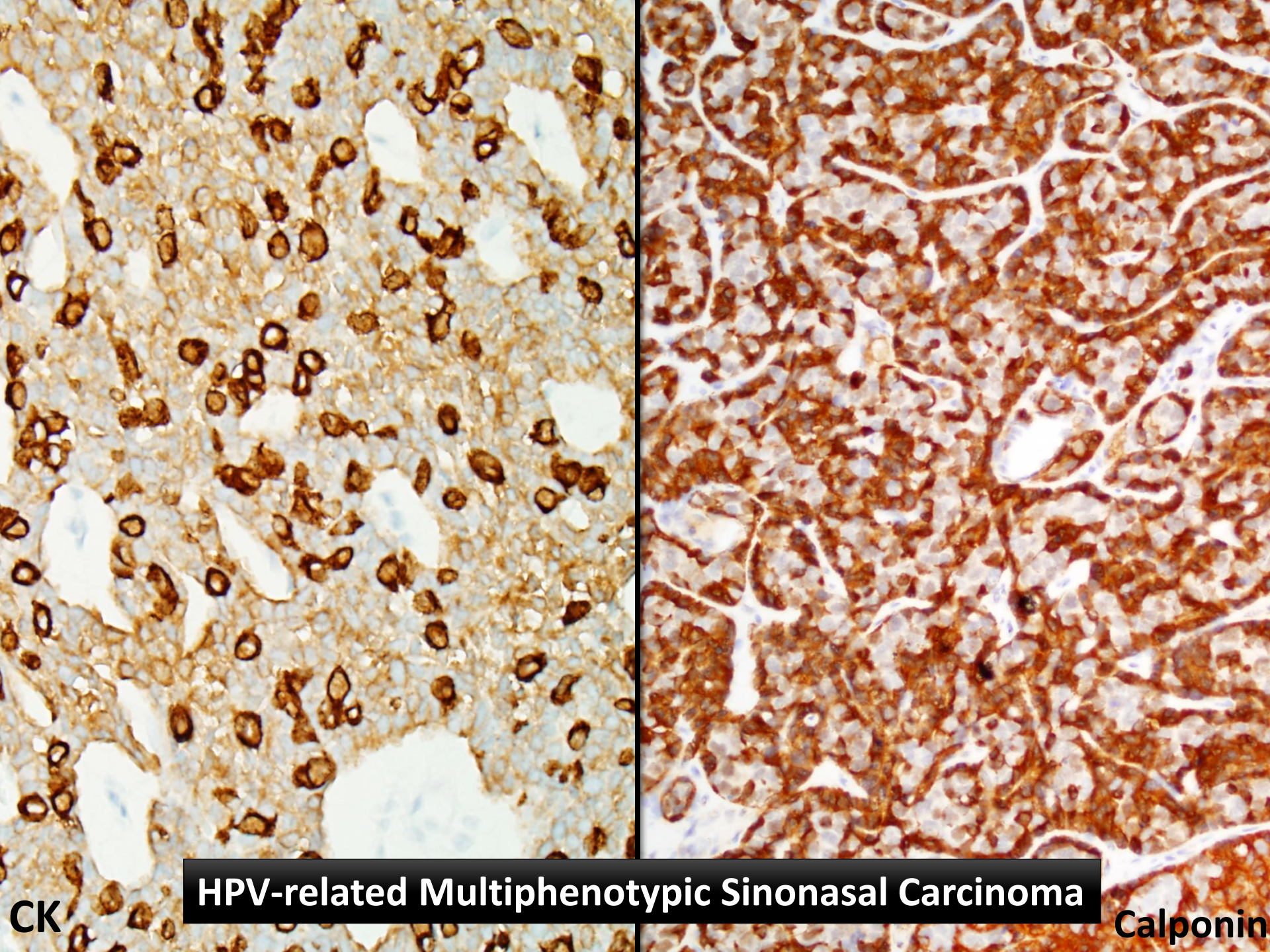
HPV-related Multiphenotypic Sinonasal Carcinoma
CK
Calponin

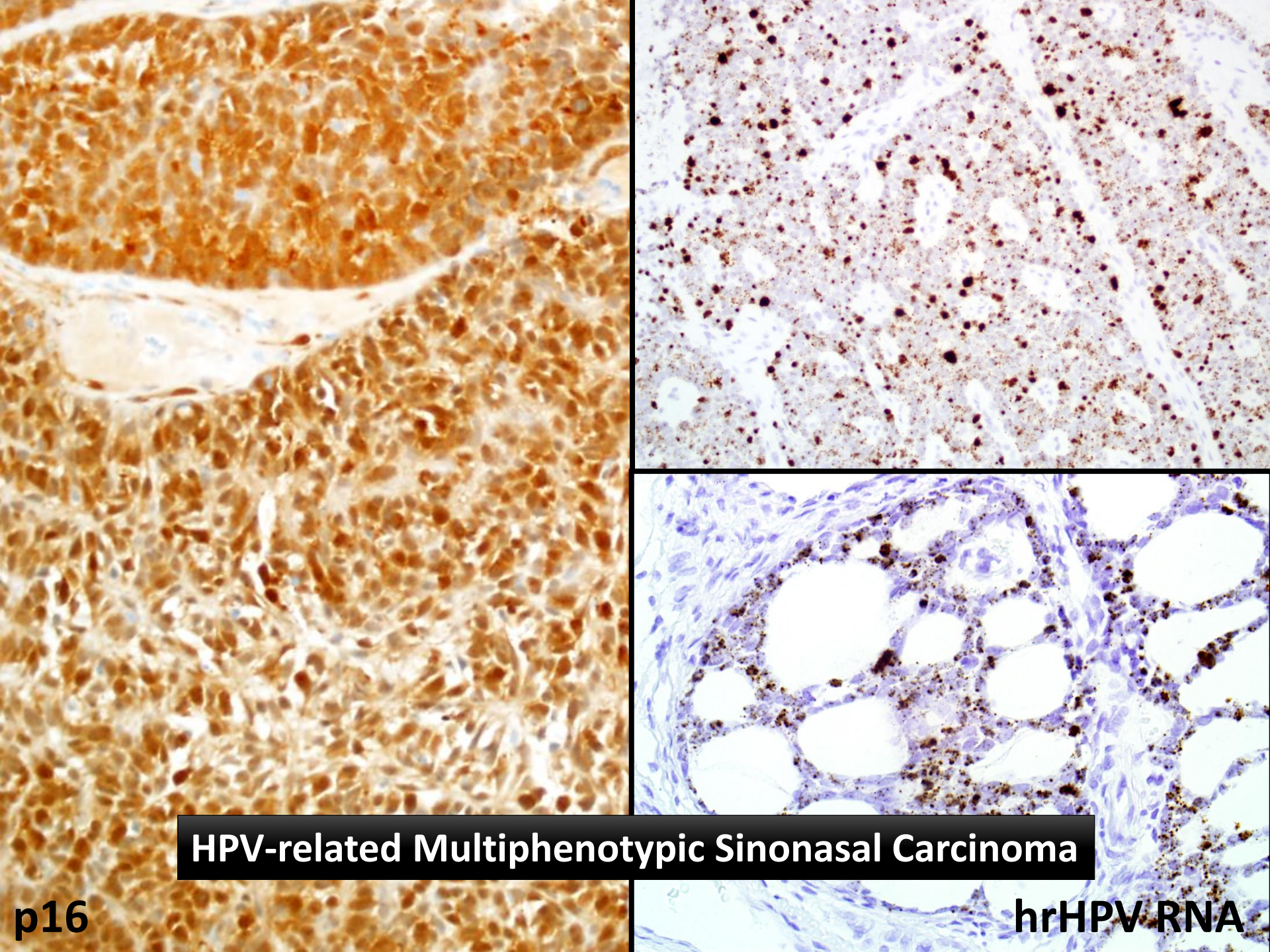
HPV-related Multiphenotypic Sinonasal Carcinoma
p16
hrHPV RNA

HPV-related Multiphenotypic Sinonasal Carcinoma

- Diagnostic criteria:
  - Essential:
    - Carcinoma with myoepithelial differentiation by immunohistochemistry
    - High-risk HPV by HPV-specific assay (not p16 alone)
  - Desirable:
    - Sinonasal tract location
    - Ductal differentiation
    - Overlying squamous dysplasia

Fusion-Driven Sinonasal Tumors Resembling NKSCC

NUT Carcinoma

- Wide age range, most common in young adults
- Defined by translocations involving the *NUT* gene at 15q14
- Rare, but still underdiagnosed
- Devastating prognosis
- Experimental targeted therapies

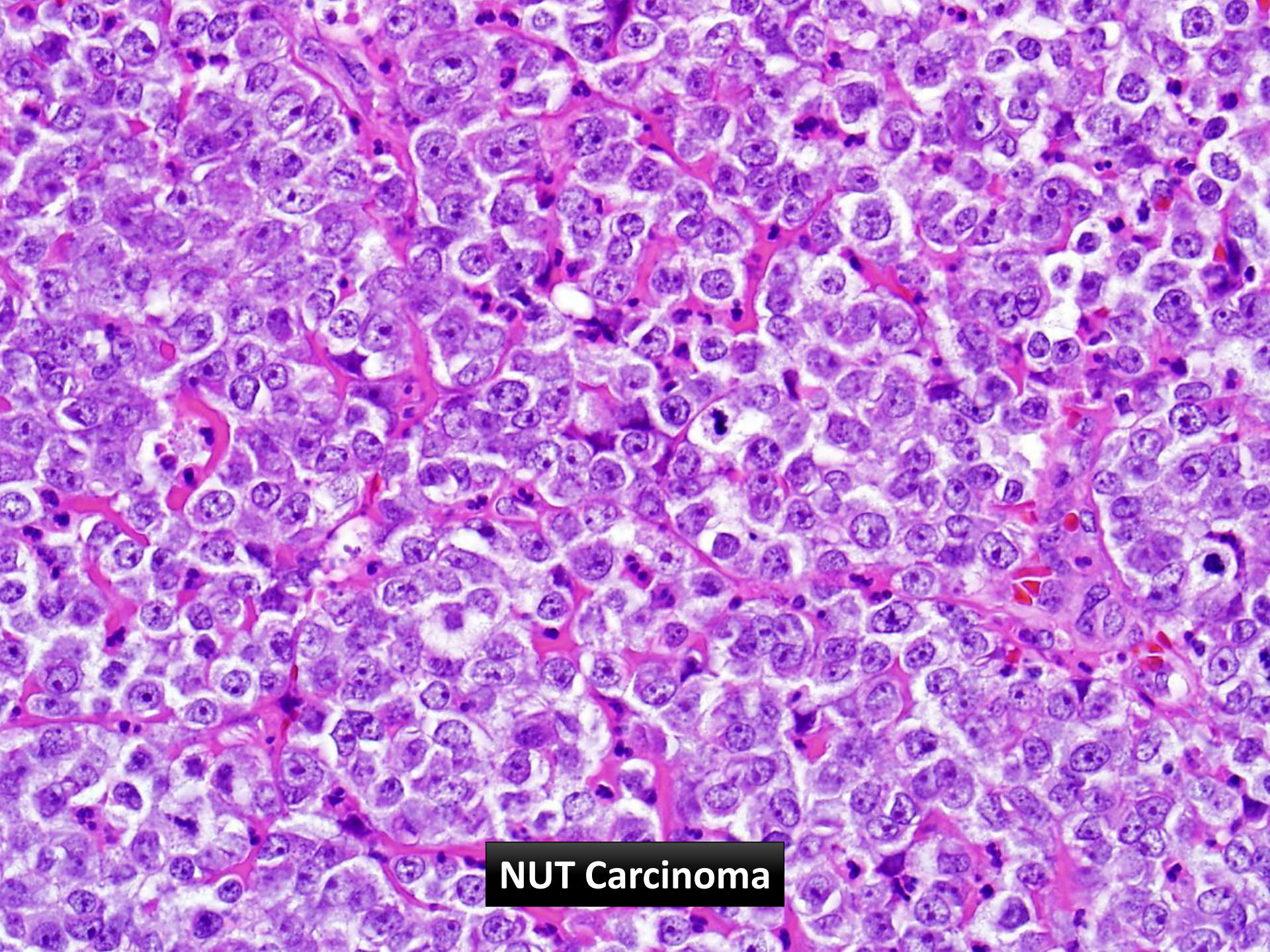
NUT Carcinoma

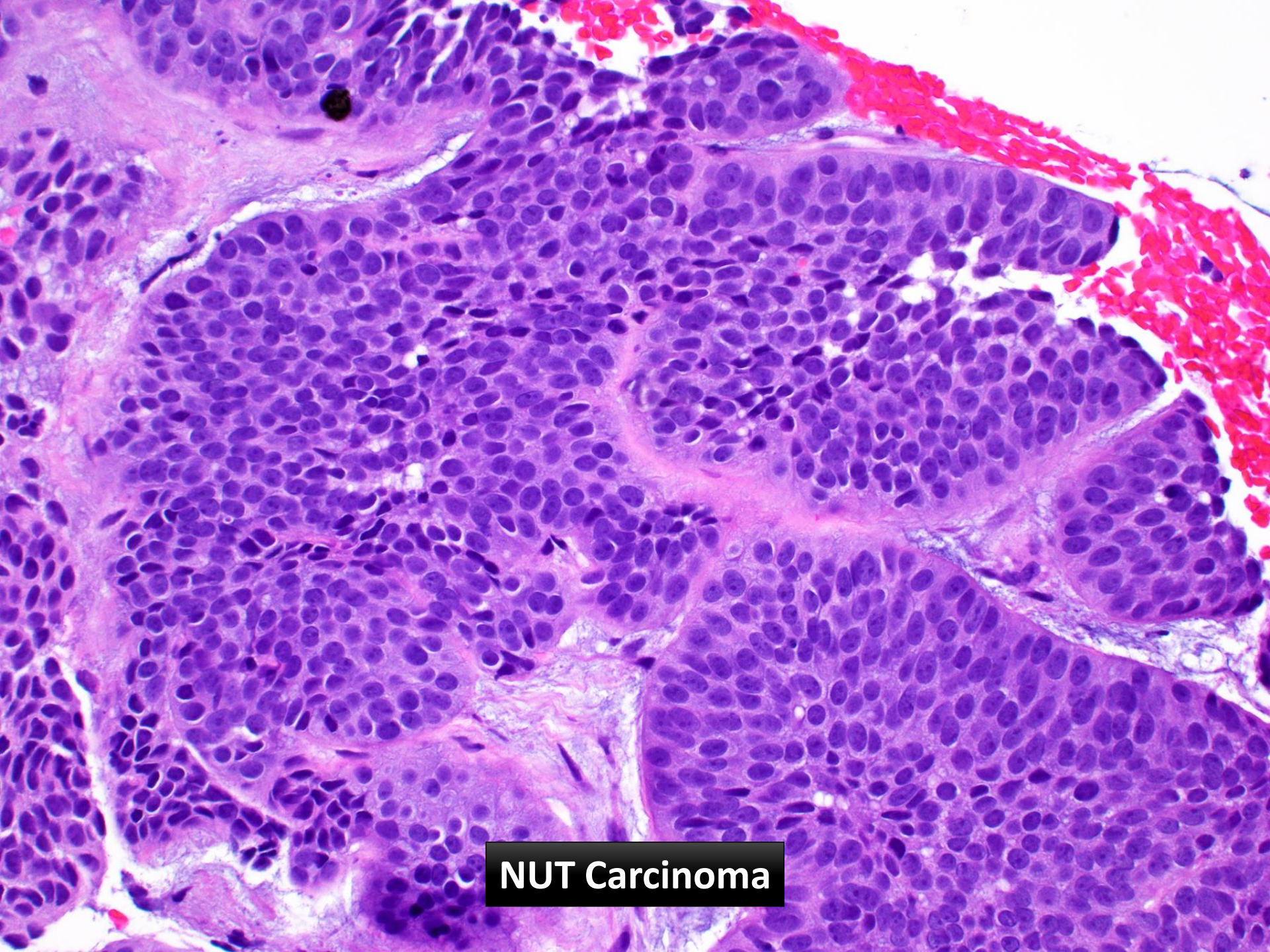
NUT Carcinoma

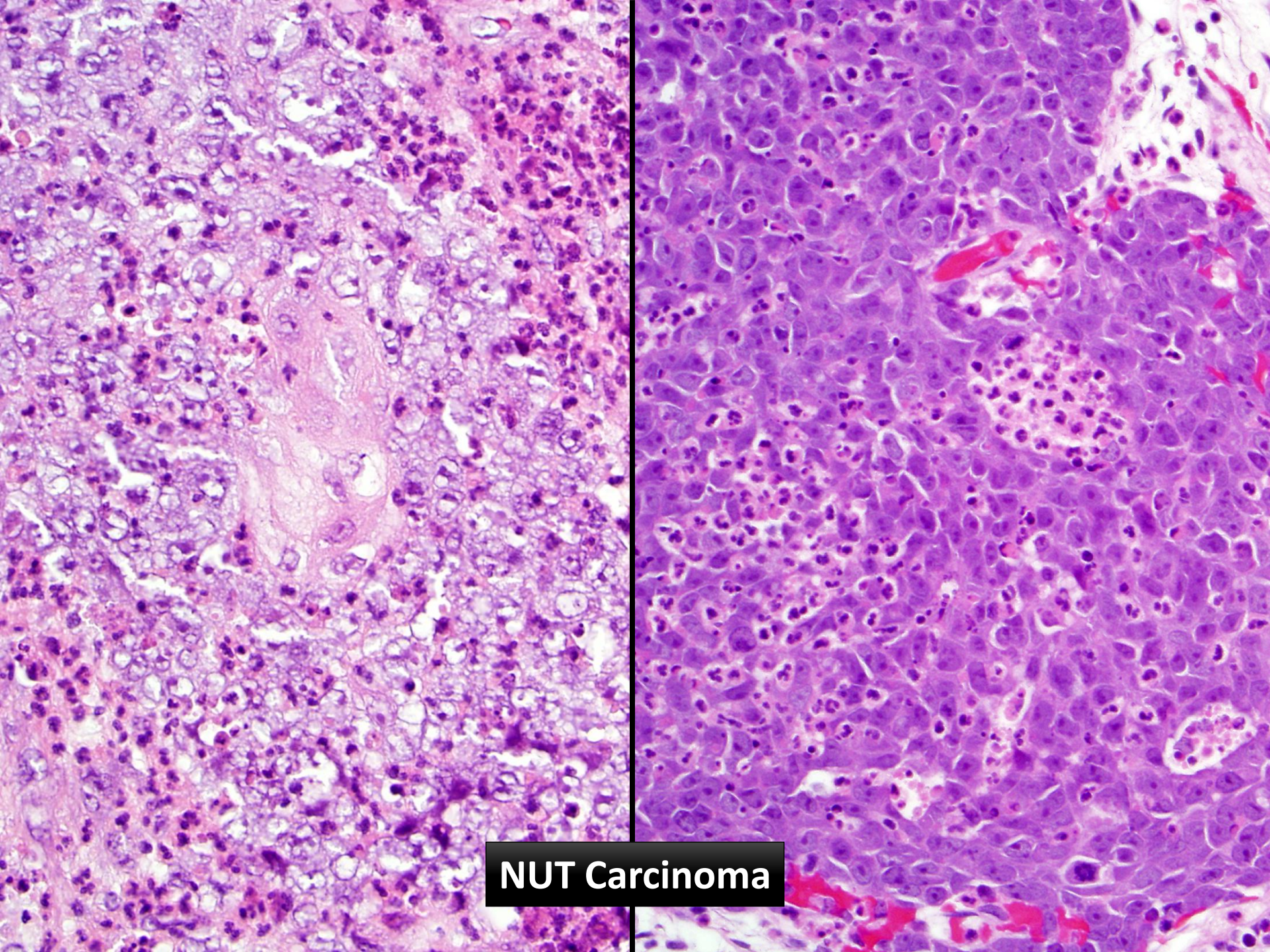
NUT Carcinoma

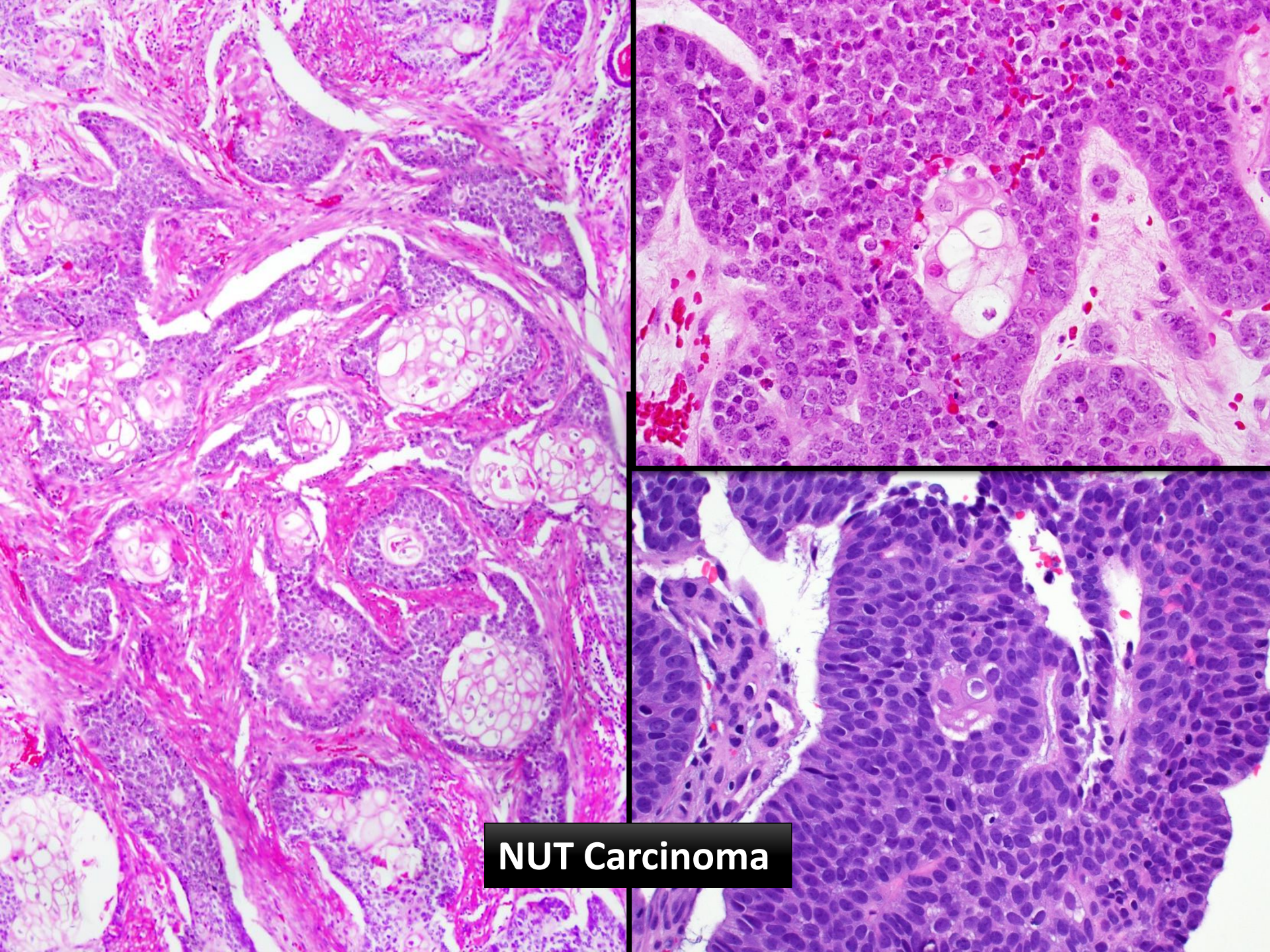
NUT Carcinoma

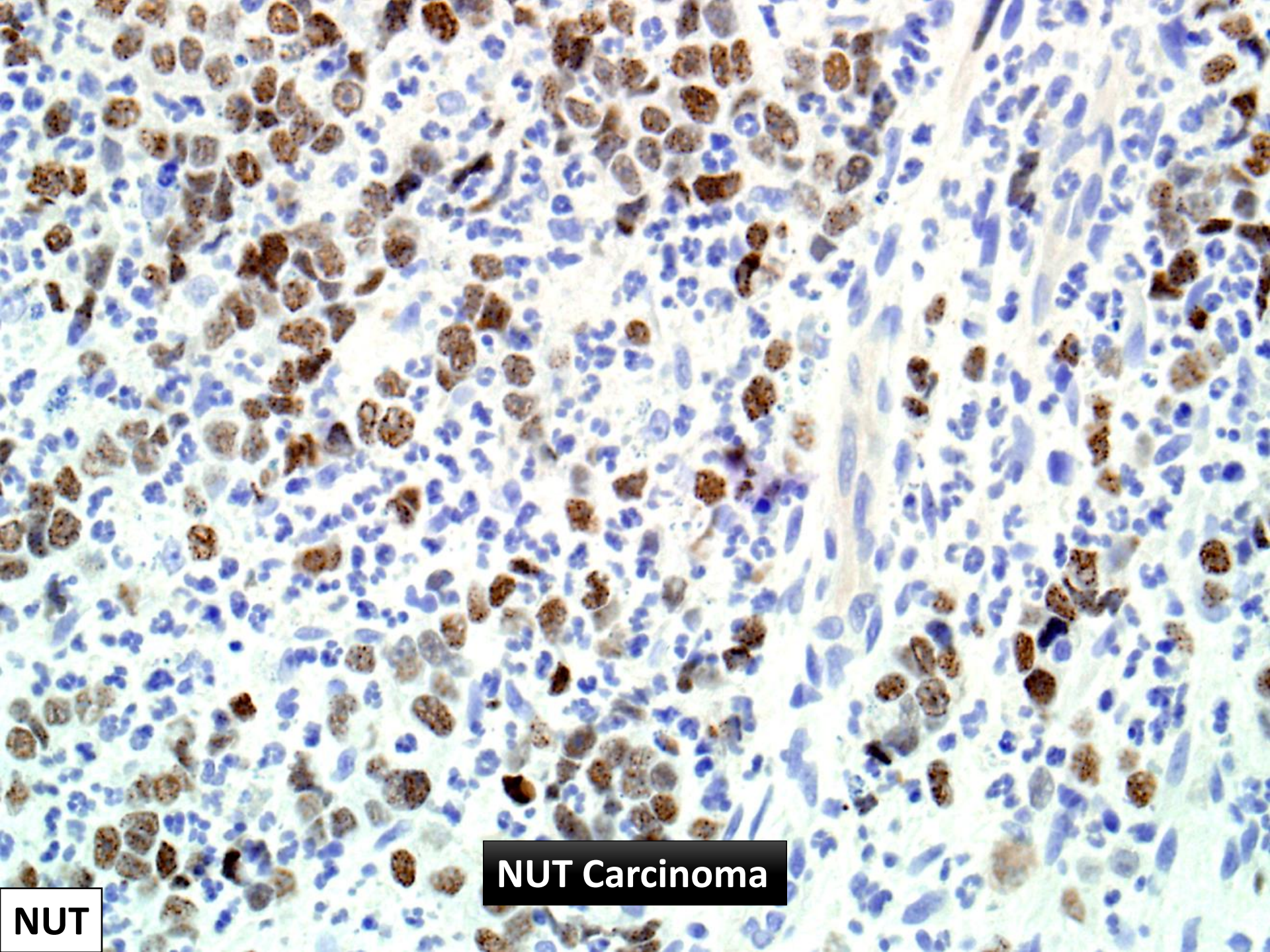
NUT Carcinoma
NUT

Adamantinoma-like Ewing sarcoma

- Rare, but not super-rare
- H&N is, by far, the most common site
- Salivary glands (most common), sinonasal, thyroid gland, orbit, soft tissues
- Can affect children, but usually adults, up to 77 y.o. (mean ~42)
- Relatively indolent, optimal treatment unclear
- Soft tissue folks split on whether it's "really" Ewing

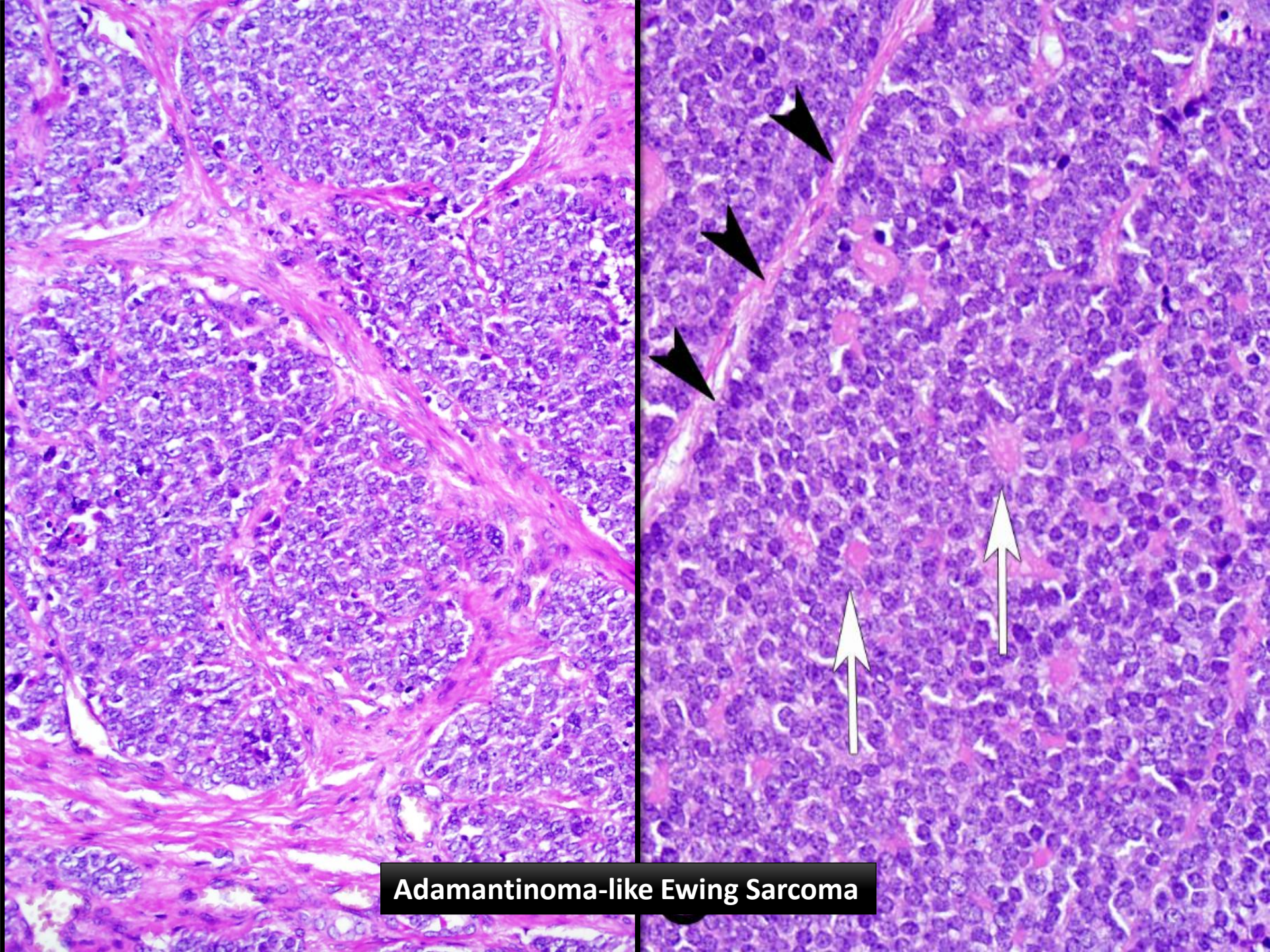
Adamantinoma-like Ewing Sarcoma

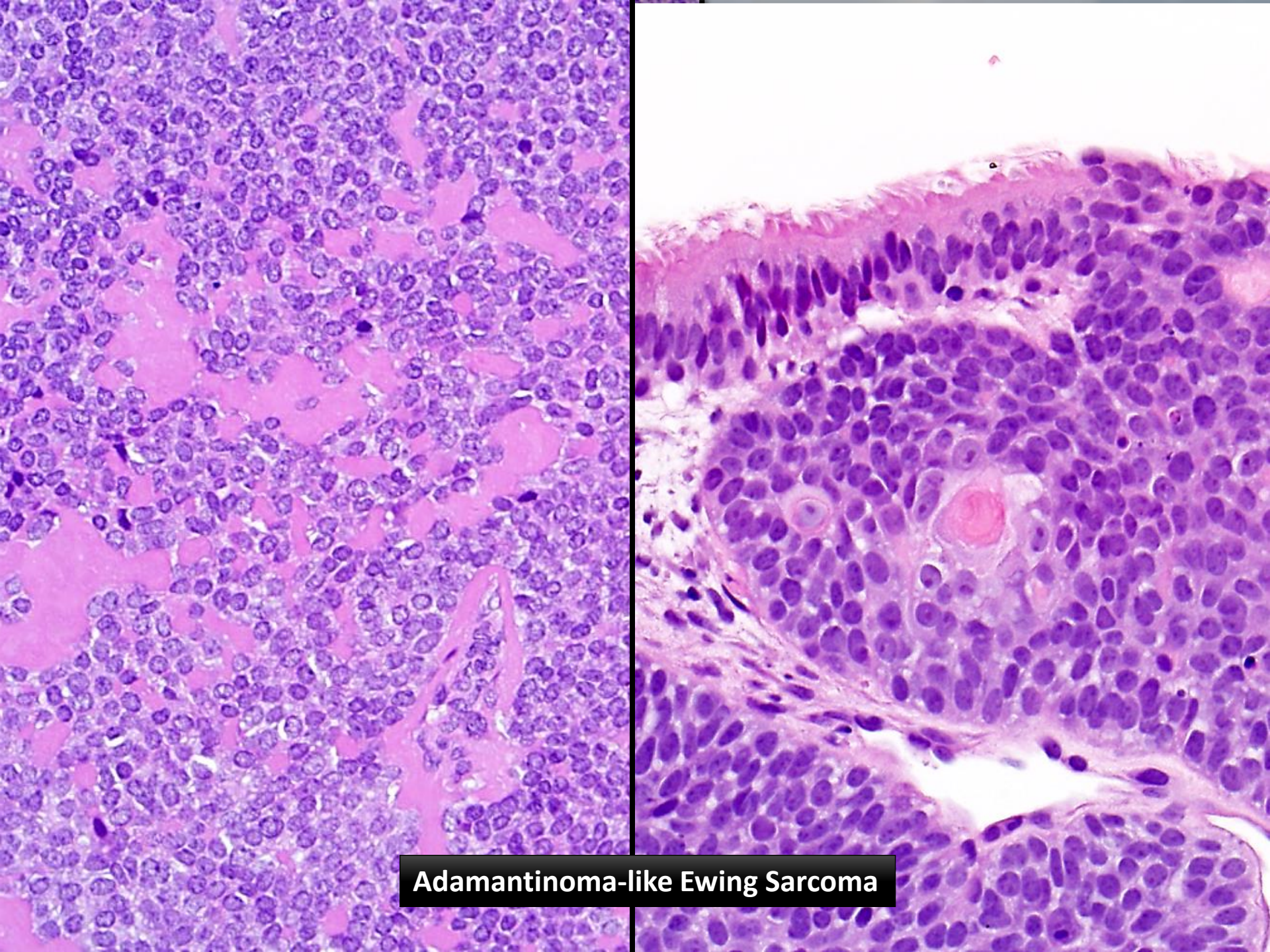

Adamantinoma-like Ewing Sarcoma

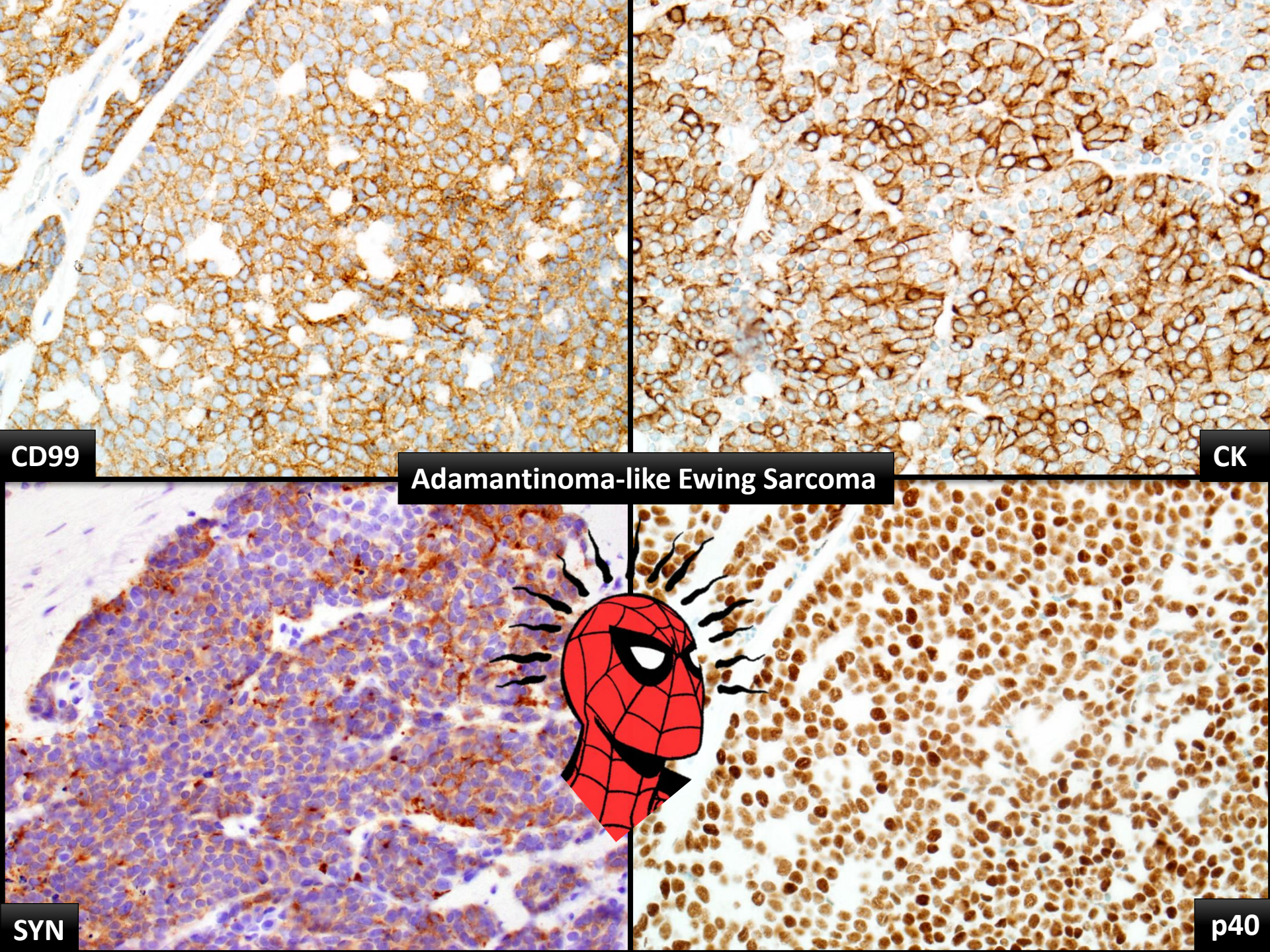
CD99
CK
Adamantinoma-like Ewing Sarcoma
SYN
p40

DEK::AFF2 Carcinoma

Published in final edited form as:
Nat Med. 2019 May ; 25(5): 767–775. doi:10.1038/s41591-019-0434-2.

The histology of the primary tumor prior to treatment was consistent with squamous cell carcinoma (Fig. 1c) and was negative for all (n = 28) human papillomavirus (HPV) serotypes tested by RNA *in situ* hybridization (Supplementary Fig. 1). The tumor microenvironment demonstrated low immune cell infiltration (Supplementary Fig. 2), most of which were $CD3^+$ $CD8^+$ T cells (Fig. 1d, e). The primary tumor and a lung metastasis were both negative for PD-L1 staining (Fig. 1f, Supplementary Figure 2). Whole genome sequencing of DNA from a frozen sample of the primary tumor (obtained prior to immunotherapy) revealed a low nonsynonymous mutation rate (0.47 mutations/MB; 14 single nucleotide variants (SNVs) in 12 genes), and a novel in-frame *DEK-AFF2* gene fusion (Fig. 1g–h; Supplementary Table 1).

[2]Immunogenomics and Precision Oncology Platform, Memorial Sloan Kettering Cancer Center, New York, NY 10065, USA.

DEK::AFF2 Carcinoma

ORIGINAL ARTICLE

Middle Ear and Temporal Bone Nonkeratinizing Squamous Cell Carcinomas With *DEK-AFF2* Fusion

An Emerging Entity

Emilija Todorovic, MD,† Tra Truong, MD,†‡ Antoine Eskander, MD,§ Vincent Lin, MD,§ David Swanson, PhD,†‖ Brendan C. Dickson, MD,†‖ and Ilan Weinreb, MD, FRCPC*†*

Abstract: Primary squamous cell carcinomas (SCCs) of the middle ear and temporal bone are rare and usually keratinizing by morphology. Nonkeratinizing, basaloid SCCs arising in this

Key Words: DEK-AFF2, DEK,
cell carcinoma

(*Am J Surg Pathol* 2020;00:000

Nonkeratinizing Squamous Cell Carcinoma of the Sinonasal Tract With *DEK-AFF2*

Further Solidifying an Emerging Entity

To the Editor:

We read with great interest the recent publication by Todorovic et al[1]

ORIGINAL ARTICLE

DEK-AFF2 Carcinoma of the Sinonasal Region and Skull Base

Detailed Clinicopathologic Characterization of a Distinctive Entity

Lisa M. Rooper, MD,† Abbas Agaimy, MD,‡ Brendan C. Dickson, MD, MSc,§‖ Julie C. Dueber, MD,¶ Charles G. Eberhart, MD, PhD,*†# Jeffrey Gagan, MD, PhD,** Arndt Hartmann, MD,‡ Armen Kharatjian, MD, MBA,†† Nyall R. London, MD, PhD,‡‡ Christina M. MacMillan, MD,§‖ Doreen N. Palsgrove, MD,** J. Stephen Nix, MD,* Robert Stoehr, PhD,‡ Tra Truong, MD,§‖‖ Ilan Weinreb, MD,§¶¶ and Justin A. Bishop, MD***

...ently reported in 4 ... the sinonasal re-... ional response to pearls, (4) monotonous nuclei, and (5) prominent tumor-infiltrating neutrophils or stromal lymphocytes. This appearance not only overlaps with high-grade basaloid sinonasal carcinomas but also with benign papillomas and tumors reported as low-

Modern Pathology
https://doi.org/10.1038/s41379-021-00846-2

ARTICLE

DEK-AFF2 fusion-associated papillary squamous cell carcinoma of the sinonasal tract: clinicopathologic characterization of seven cases with deceptively bland morphology

Ying-Ju Kuo[1,2] · James S. Lewis Jr.[3,4] · Changwen Zhai[5] · Yun-An Chen[6] · Rebecca D. Chernock[7] · Min-Shu Hsieh[8,9] · Ming-Ying Lan[2,10] · Chien-Kuan Lee[11] · Ilan Weinreb[12,13] · Jen-Fan Hang[1,2]

DEK::AFF2 Carcinoma

Case No.	Age (y)	Sex	Site and Extension	Size (cm)	Clinical Course	Treatment	Status
1	68	Male	Temporal bone and middle ear with extension into nasopharynx and nasal cavity	NA	Local disease only at presentation	Surgery; additional treatment pending	NA
2	47	Male	Middle ear and temporal bone	NA	Cervical lymph node metastasis of unknown primary at presentation; inoperable primary tumor and lung metastases found at 12 mo	Palliative XRT	AWD at 12 mo
3	28	Female	Right lateral nasal wall and medial canthus	NA	Rapid local recurrence after initial excision; lung metastases at 8 mo	Surgery; chemo; immunotherapy	AWD at 10 mo
4	66	Female	Right nasal cavity (centered on posterior middle turbinate)	2.9	Extensive bone metastases at 7 mo	Surgery, XRT, chemo	DOD at 9 mo
5	28	Male	Left nasal cavity (attached at posterior middle turbinate below frontal recess) with extension into sphenoid sinus	5.6	Multiple local recurrences starting at 18 mo	Surgery, XRT	NED at 66 mo
6	56	Female	Left nasal cavity with extension to maxillary sinus, ethmoid sinus, and nasopharynx	7	Inoperable primary tumor and cervical lymph node metastasis at presentation	Chemo, XRT	AWD at 3 mo
7	79	Female	Lacrimal sac/nasolacrimal duct with orbital invasion	3.6	Local recurrence at 8 mo	Surgery	NED at 12 mo
8	59	Female	Nasopharynx with extension into Eustachian tube and middle ear	NA	Cervical lymph node metastasis at presentation	Surgery; additional treatment pending	NA
9	64	Female	Left nasal cavity (attached to posterior middle turbinate) with extension into ethmoid sinus	6.9	Local disease only at presentation	Surgery; additional treatment pending	NA
10	18	Male	Right nasal cavity (centered over posterior middle turbinate)	1.8	Brain metastases and cervical lymph node metastasis at presentation; local recurrence with leptomeningeal spread at 28 mo	Surgery; XRT; chemo; immunotherapy	DOD at 29 mo
11	23	Female	Nasal septum	NA	Prior biopsy reportedly called inverted sinonasal papilloma, recurrence at 8 mo	Surgery; additional treatment pending	NA
12	78	Male	Middle nasal turbinate	NA	Local disease only at presentation with no recurrence or metastasis	Surgery	NED at 15 mo
13	53	Female	Nasal cavity	NA	NA	Surgery; additional treatment pending	NA

Am J Surg Pathol. 2021. 45(12):1682-1693.

DEK::AFF2 Carcinoma

Table 2 Clinical features of *DEK-AFF2* fusion-associated papillary squamous cell carcinoma with deceptively bland morphology.

Case no.	Age	Sex	Primary location	Original diagnosis	Clinical course	Follow-up
1	61	F	NP & nasal cavity	Inverted SP with dysplasia	Local recurrence x 1 (NP, sphenoid sinus & skull base); treatment: local excision with CCRT	AWD 7 m
2	79	F	Nasal cavity	Inverted SP with dysplasia	Local recurrence x 3 (NP & nasal cavity); treatment: local excision without adjuvant therapy; newly diagnosed lung adenocarcinoma, s/p lobectomy, chemotherapy, and clinical trial for EGFR inhibitor	AWD 58 m
3	28	M	Ethmoid & frontal sinus	Inverted SP with CIS	Local recurrence x 1 (frontal sinus & nasal cavity); treatment: local excision with CCRT	AWD 26 m
4	47	F	Nasal cavity	Fungiform SP	Local recurrence >10 (nasal cavity, lacrimal sac, cheek, orbital & submandibular lymph nodes), nodal metastases at recurrence; treatment: multiple radical surgery with CCRT	DOD 18 y
5	64	M	Nasal cavity	Oncocytic SP with CIS	Local recurrence x 2 (frontal sinus & orbital wall); treatment: local excision without adjuvant therapy	NED 10 m
6	53	F	Nasal cavity, sphenoid sinus, NP, middle ear, and skull base	SP	Local recurrence x 2 (sinonasal tract & skull base), nodal metastases at last recurrence; treatment: local excision with radiotherapy	AWD 18 m
7	51	F	Nasal cavity	Exophytic SP	Local recurrence x 2 (nasal cavity); treatment: local excision with radiotherapy	NED 30 m

Mod Pathol. Oct;34(10):1820-1830.


SNUC
Lymphoepithelial CA
CHD4::AFF2
?
DEK::AFF2
Adamantinoma-like Ewing sarcoma
Neuroendocrine carcinoma
Adenocarcinoma
NUT Carcinoma
HPV+ Carcinoma (incl. HMSC)
Squamous Cell Carcinoma
Teratocarcinosarcoma

Sinonasal Undifferentiated Carcinoma

- Rare, ***and getting rarer***
- Nasal cavity and ethmoid > maxillary
- Very fast-growing, large, and aggressive
- Lacks any specific differentiation
- A diagnosis of exclusion

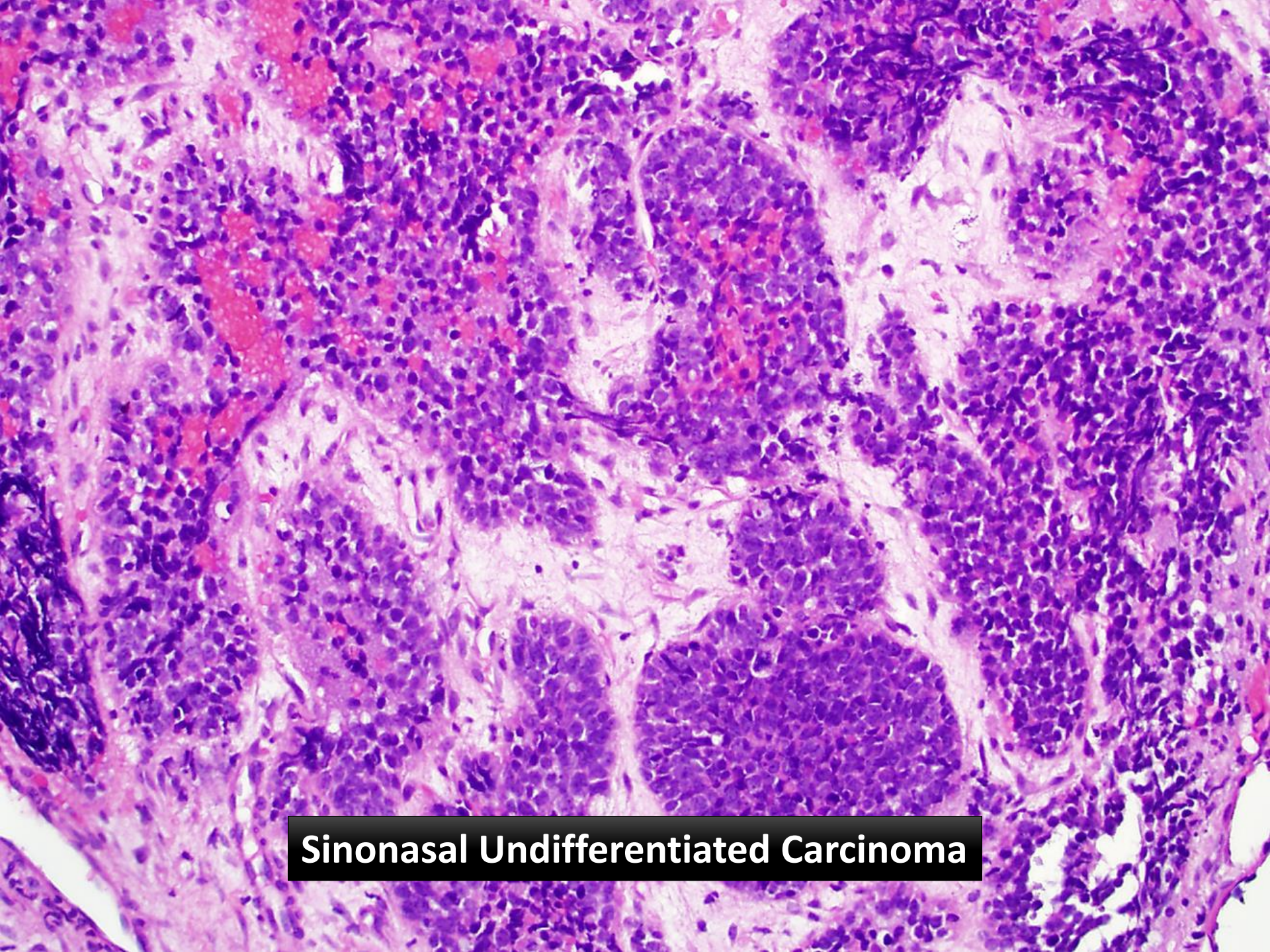
Sinonasal Undifferentiated Carcinoma

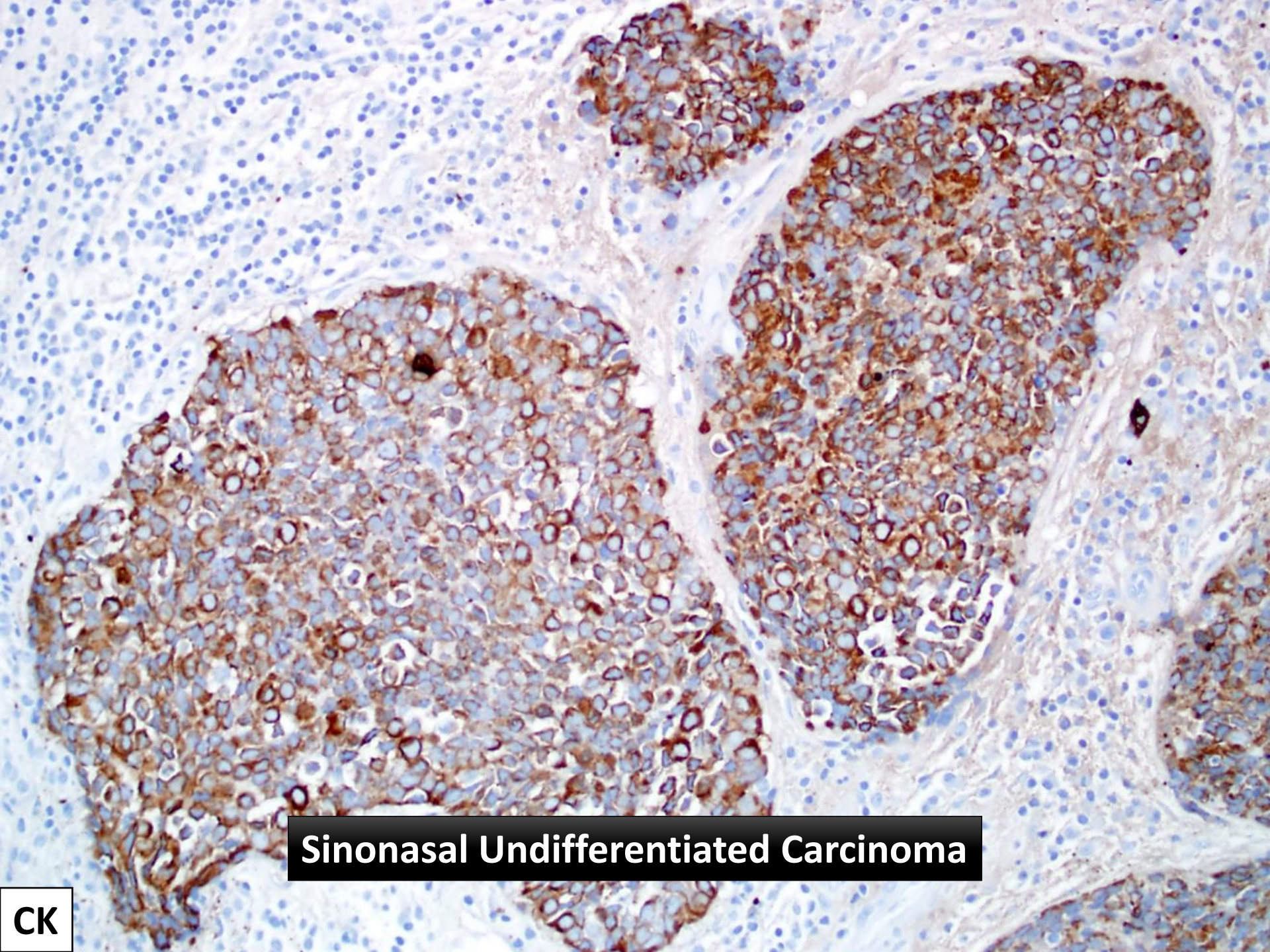
Sinonasal Undifferentiated Carcinoma
CK

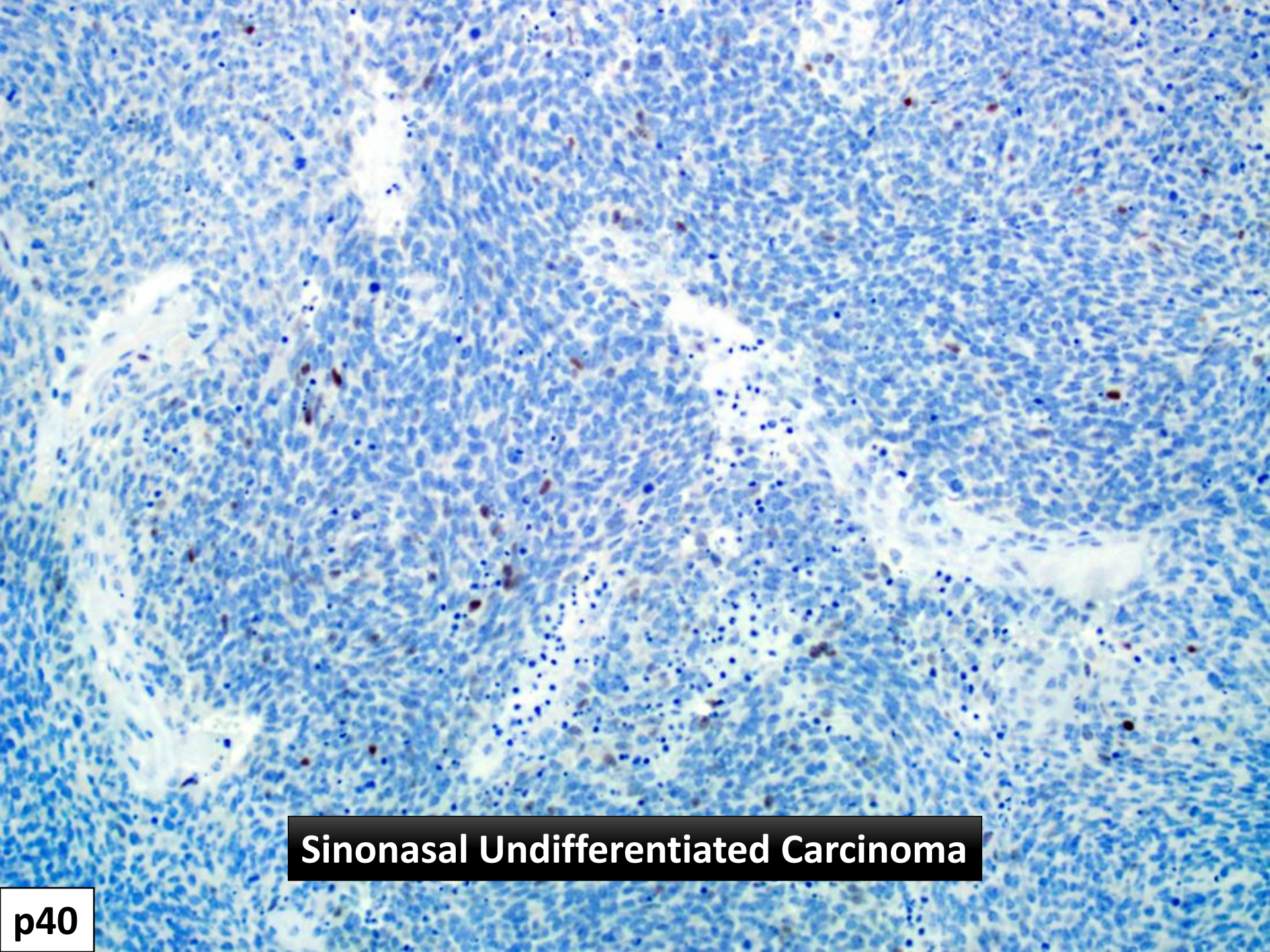
Sinonasal Undifferentiated Carcinoma
p40

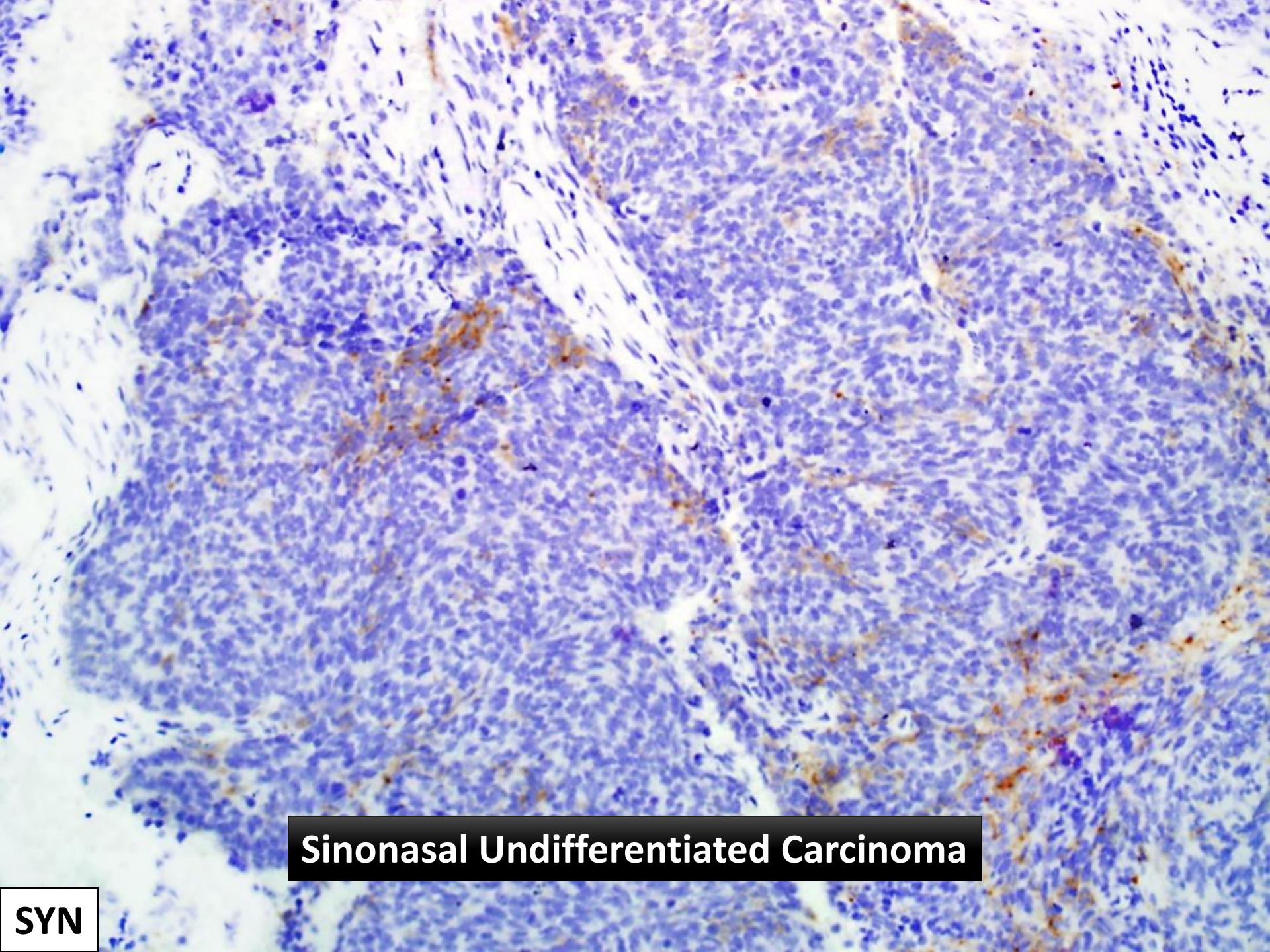
Sinonasal Undifferentiated Carcinoma
SYN


SNUC

SMARCB1-deficient sinonasal carcinoma

- SMARCB1 is part of SWI/SNF chromatin remodeling complex, expressed in nuclei of normal tissues.
- Inactivation seen in diverse group of malignant neoplasms (e.g., rhabdoid tumor, epithelioid sarcoma, etc.)
- Included as a provisional entity in 2017 WHO classification, now fully fledged.

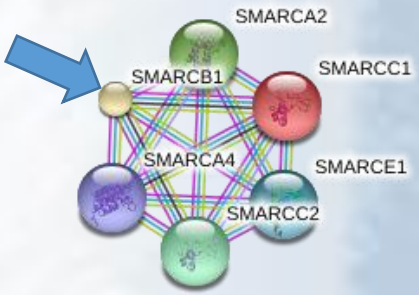

SMARCB1-Deficient Sinonasal Carcinoma

- Wide age range (19 to 89 years, mean 52) with a slight male predominance
- Paranasal sinuses (especially ethmoid) and nasal cavity, often with extension into orbit
- Obstruction, pain, eye symptoms
- Most cases (21 of 27) harbor mutations in SMARCB1 gene on chromosome 22q11.2.
- Present at high stage, 56% died of disease (mean, 15 months).

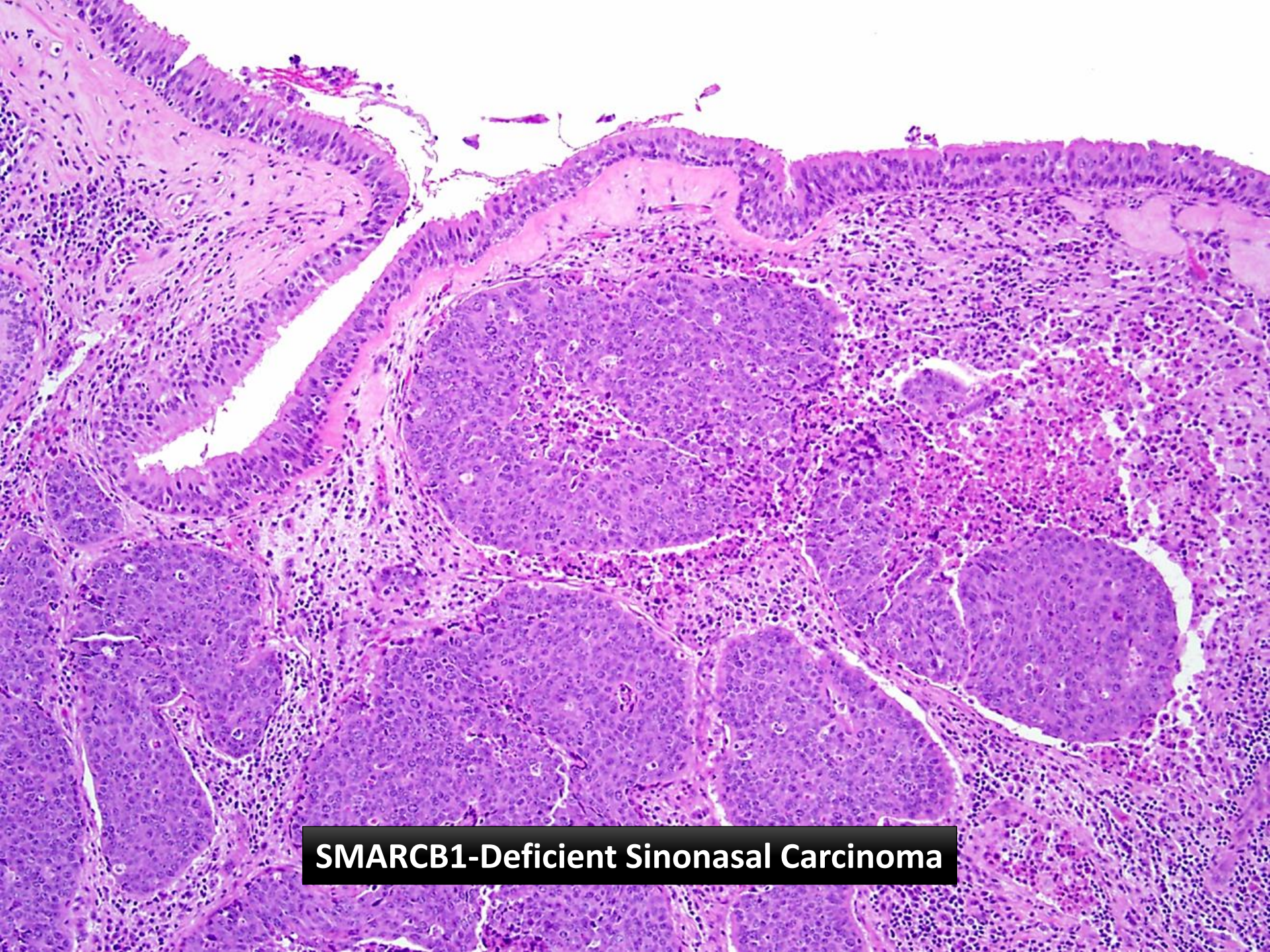
SMARCB1-Deficient Sinonasal Carcinoma

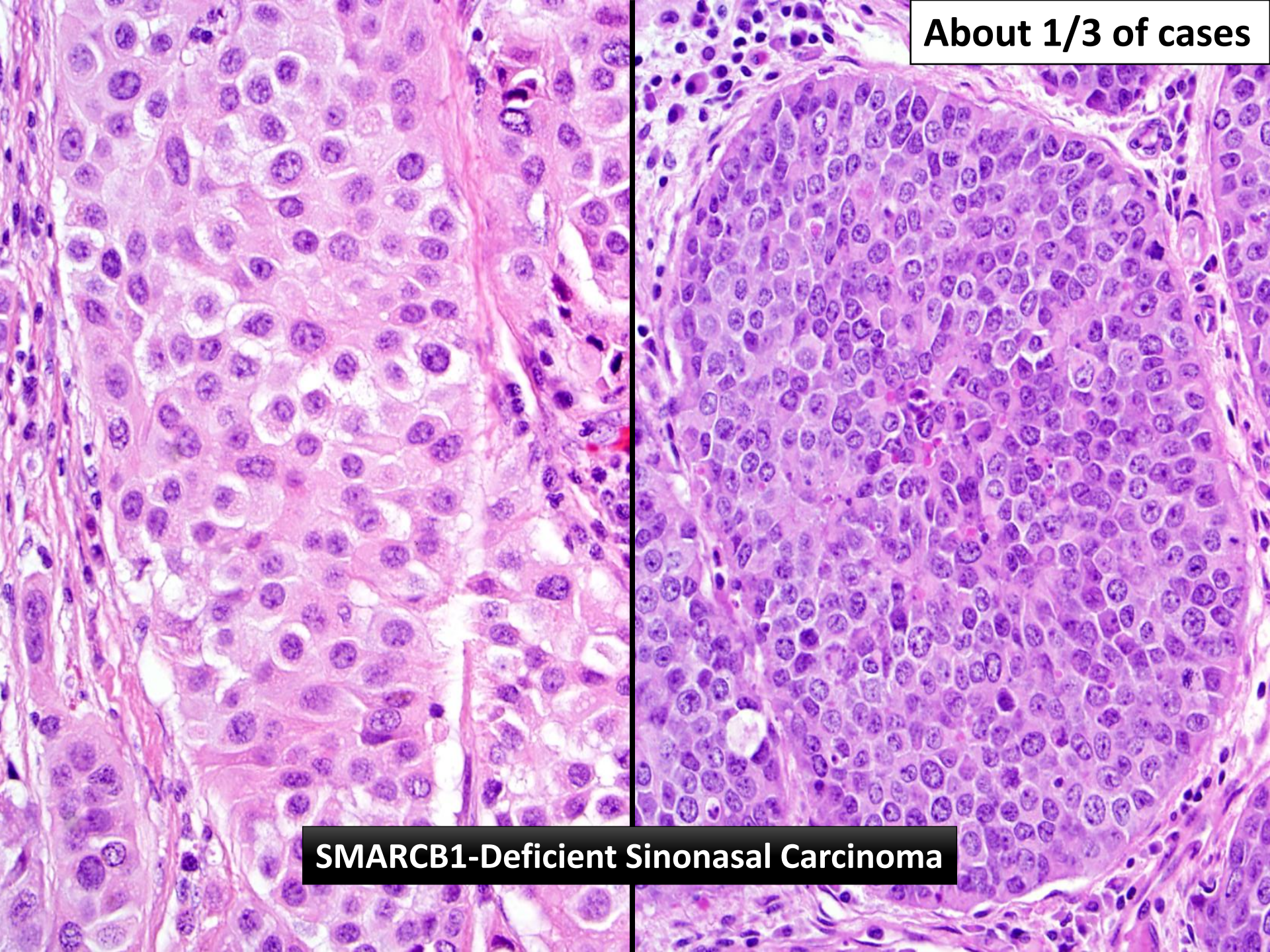
About 1/3 of cases
SMARCB1-Deficient Sinonasal Carcinoma

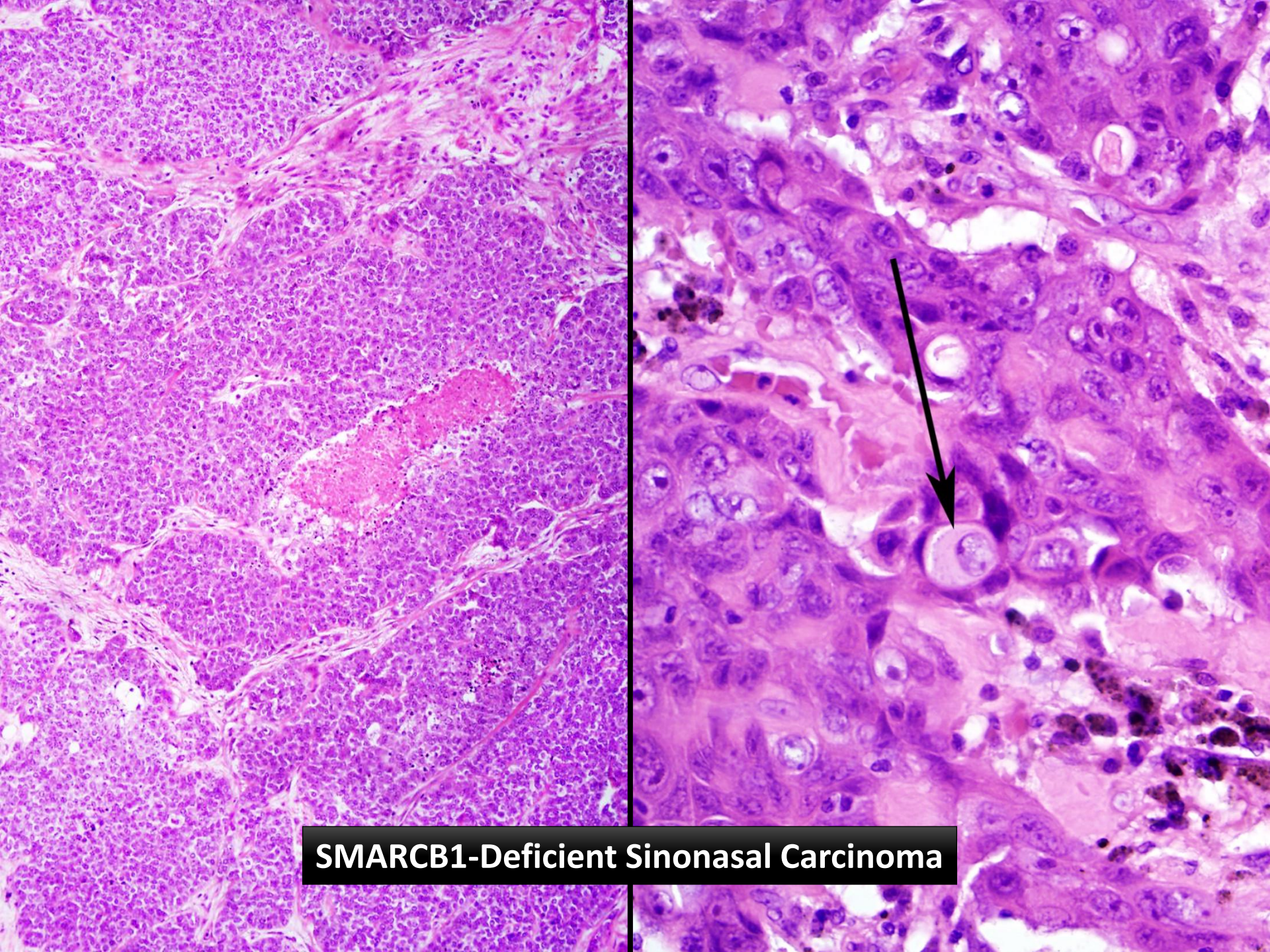
SMARCB1-Deficient Sinonasal Carcinoma

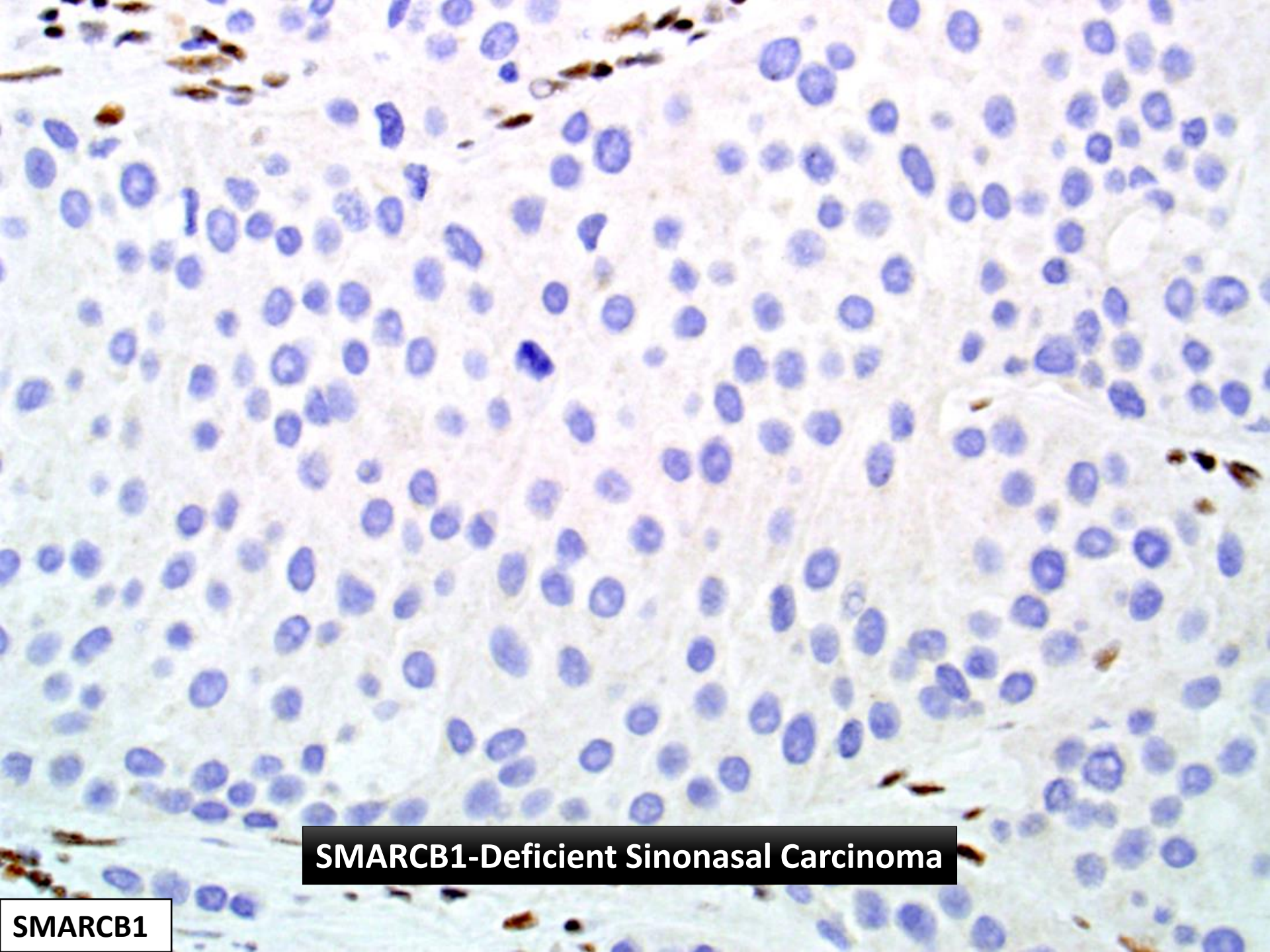
SMARCB1-Deficient Sinonasal Carcinoma
SMARCB1

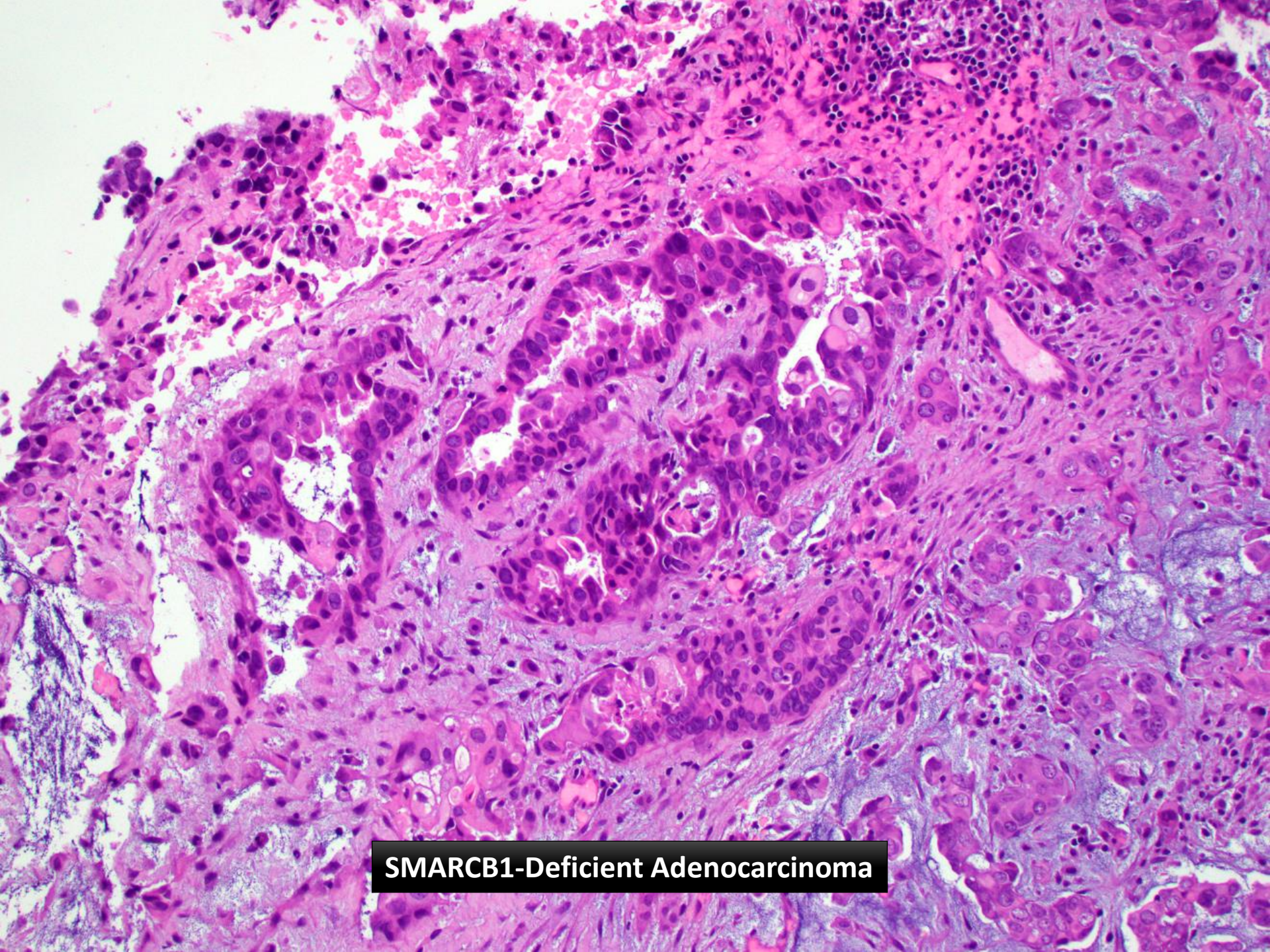
SMARCB1-Deficient Adenocarcinoma

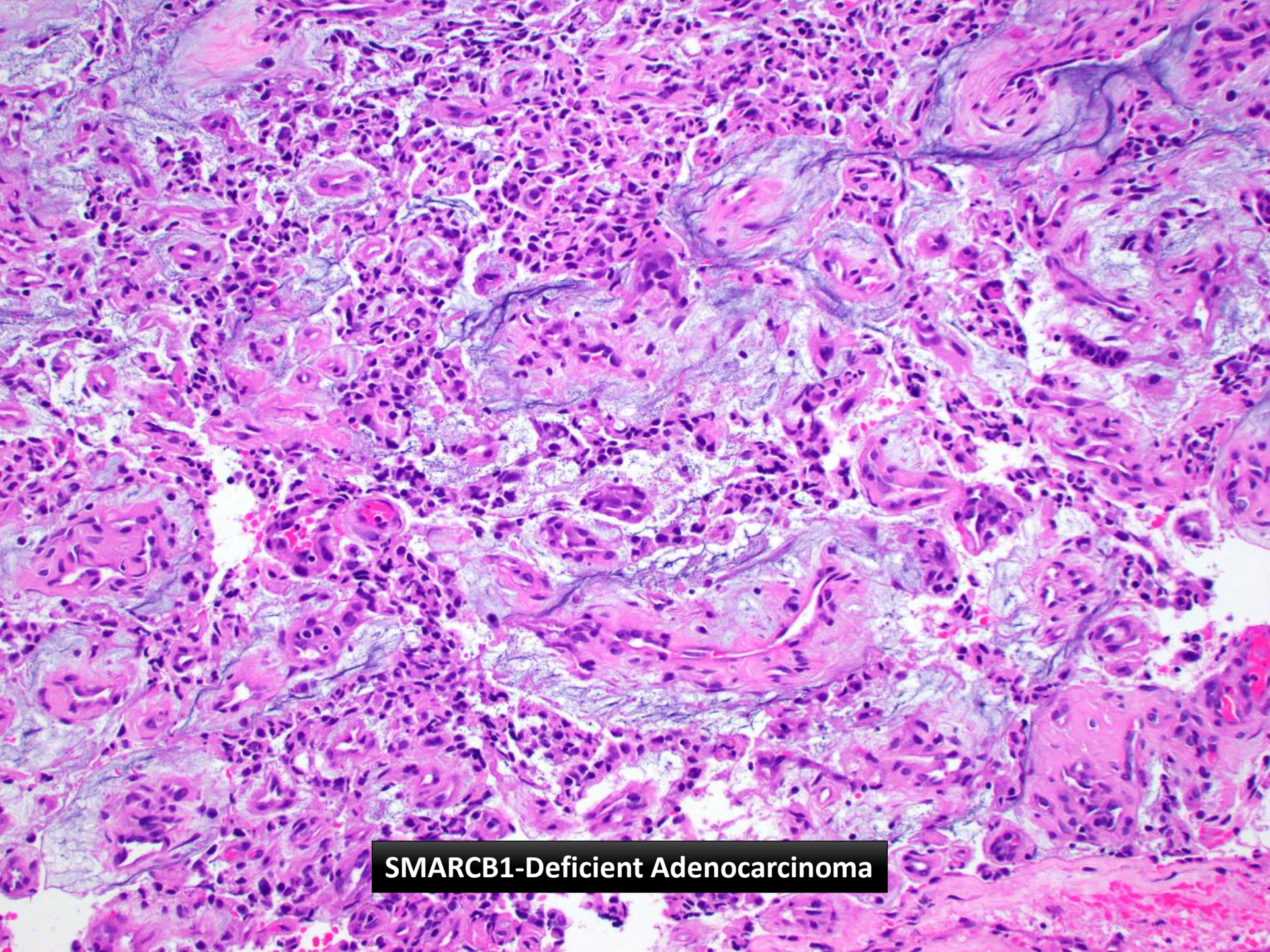
SMARCB1-Deficient Adenocarcinoma

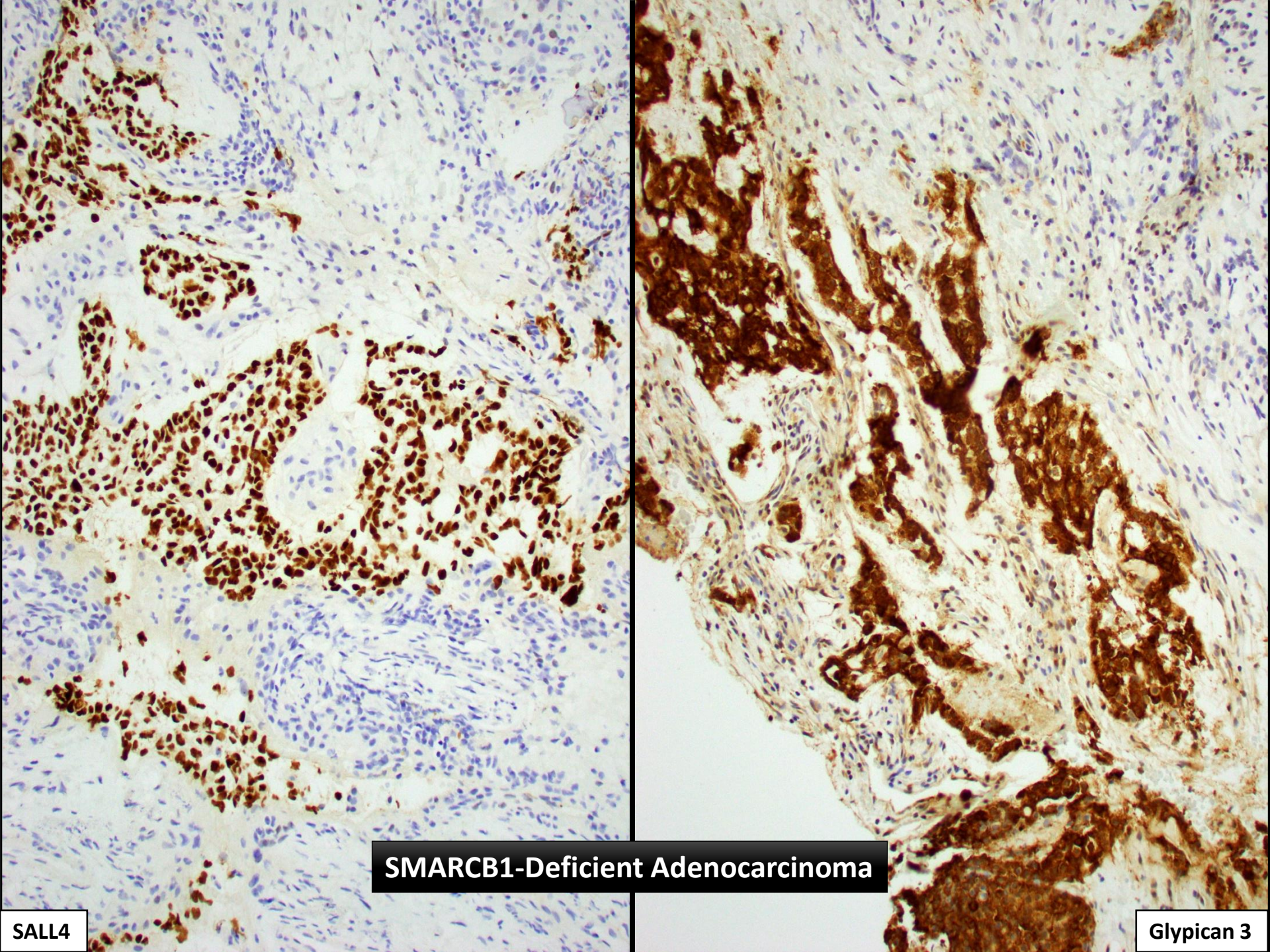
SMARCB1-Deficient Adenocarcinoma
SALL4
Glypican 3

SMARCA4 Deficient Sinonasal Carcinoma

- SMARCA4-deficient family of tumors includes undifferentiated thoracic carcinomas/sarcomas, uterine sarcomas, small cell carcinoma of ovary (hypercalcemic type)
  - Also a small subset of normally SMARCB1-deficient tumors
- Rare published sinonasal cases, but increasingly recognized
- Most cases more closely resemble neuroendocrine carcinoma than SMARCB1-deficient carcinoma

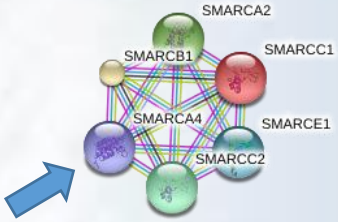

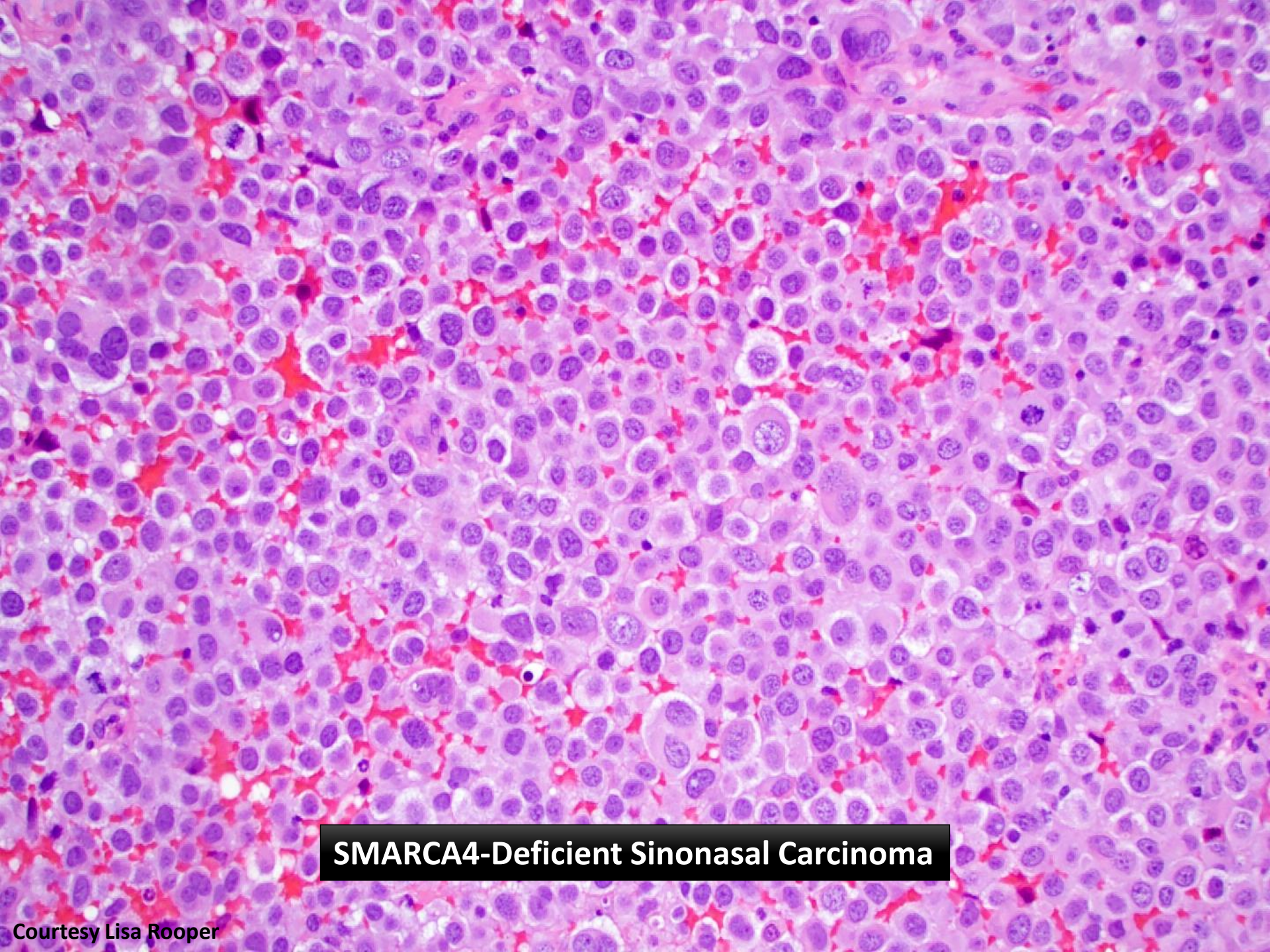
SMARCA4-Deficient Sinonasal Carcinoma
Courtesy Lisa Rooper

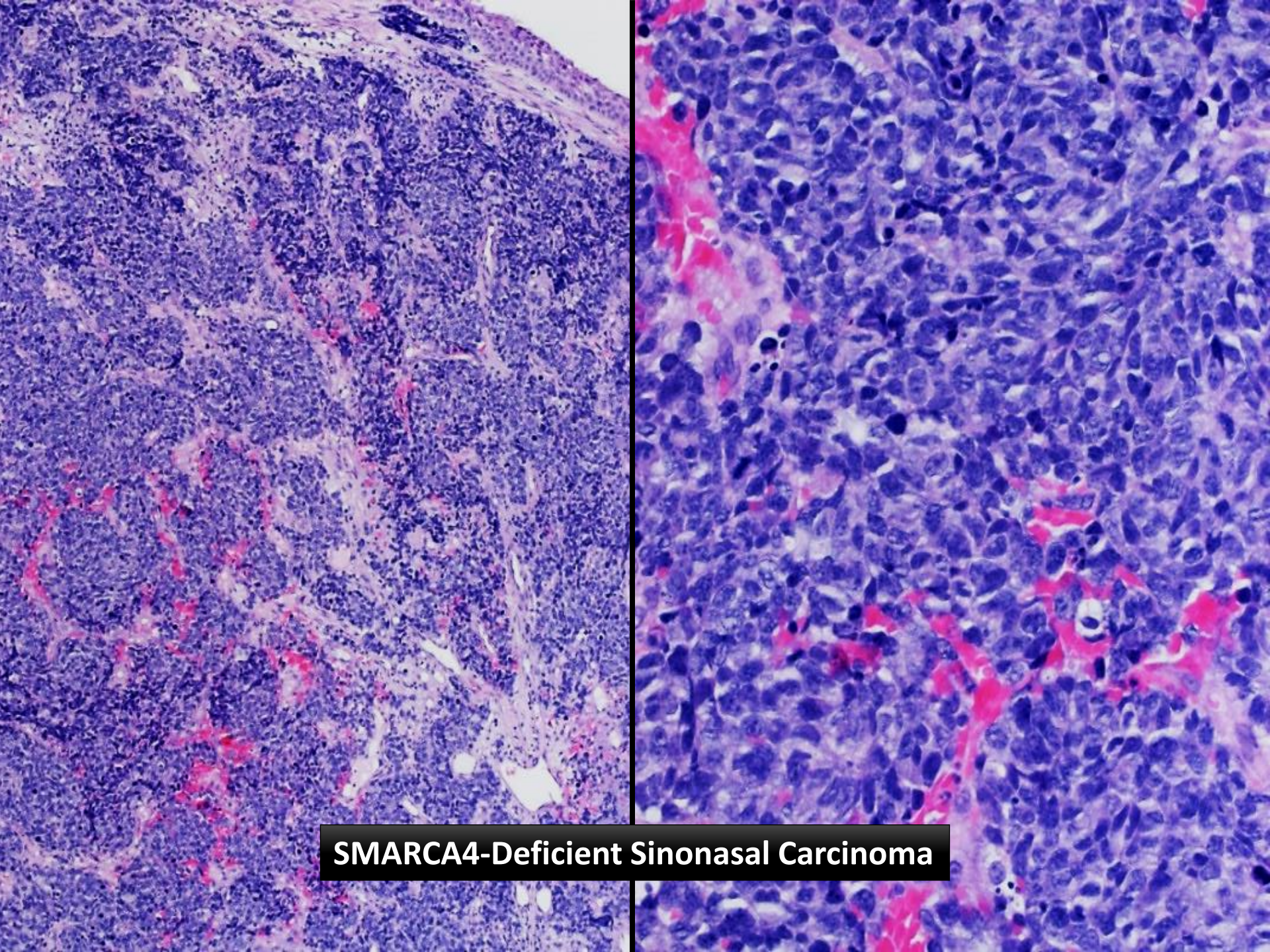
SMARCA4-Deficient Sinonasal Carcinoma

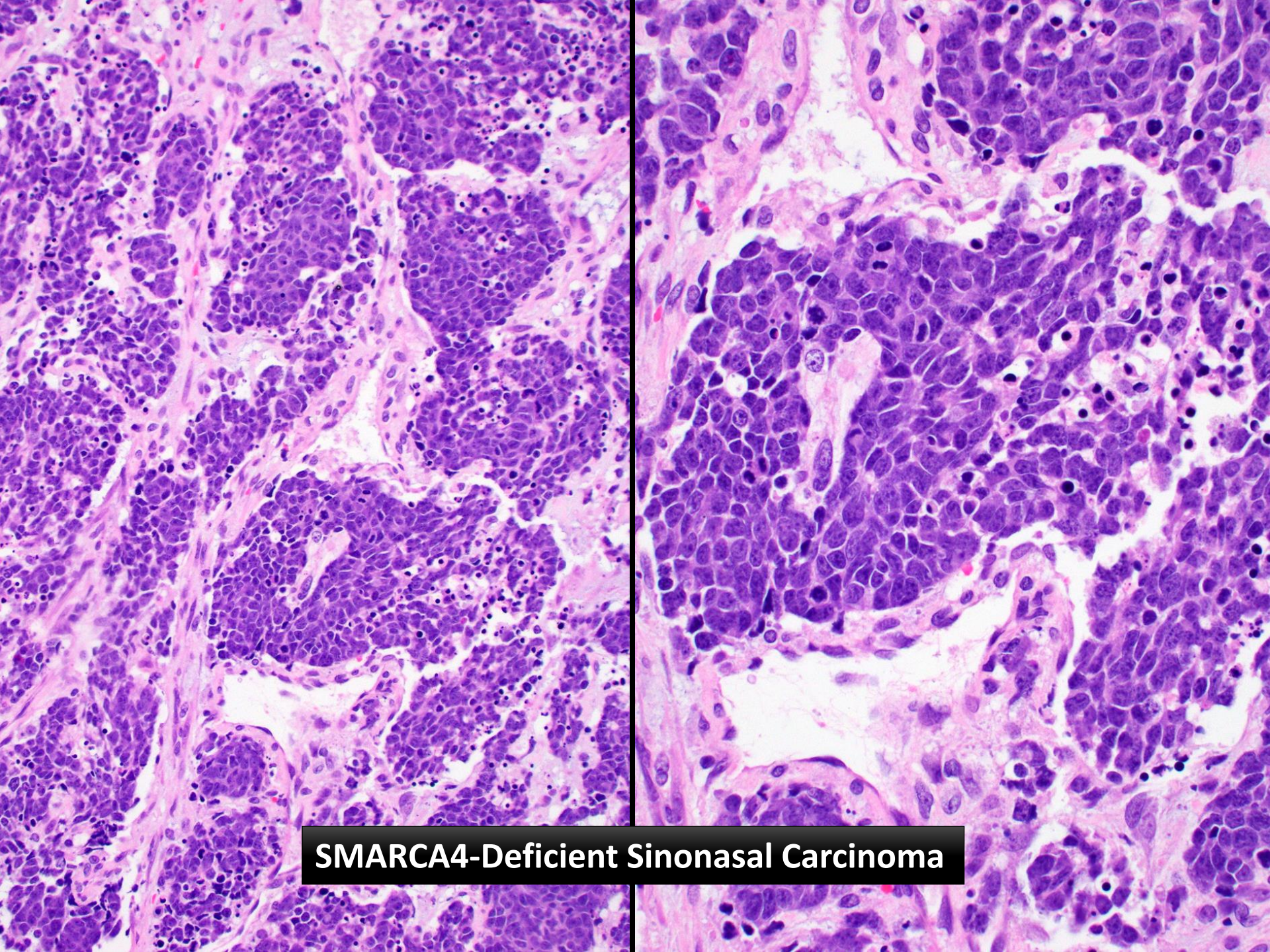
SMARCA4-Deficient Sinonasal Carcinoma

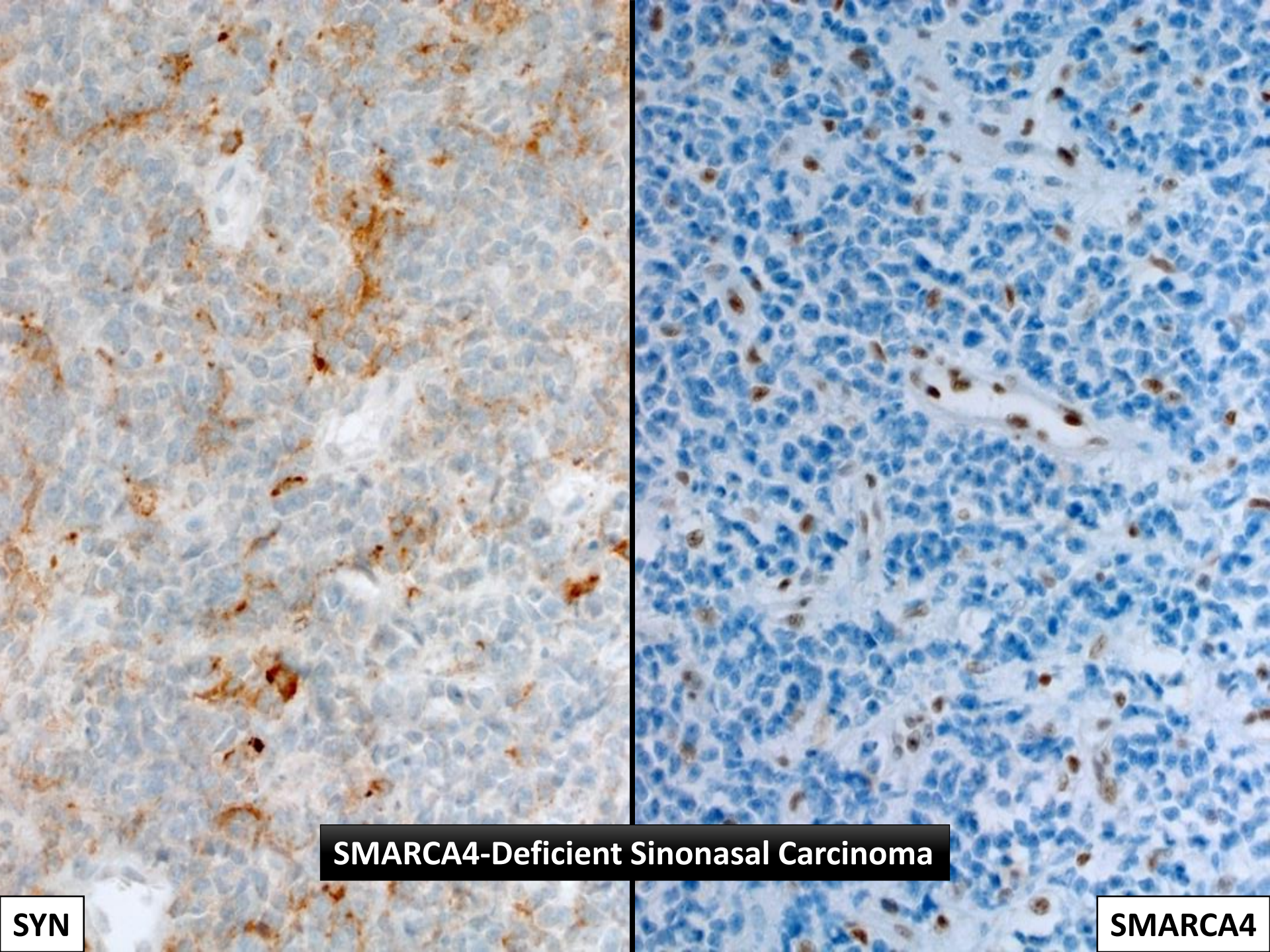
SMARCA4-Deficient Sinonasal Carcinoma
SYN
SMARCA4

IDH-mutated sinonasal carcinoma

- Subset of SNUCs harbor *IDH* mutations. (*IDH2* R172T most commonly)
- Classified as SNUC, HG NEC, or HG non-intestinal adeno, or simply carcinoma NOS
- When excluding other entities, as many as 80% of "true SNUC" harbor mutations
- Less aggressive than other SNUC-like carcinomas
- Potentially targetable

Modern Pathology (2017), 1–10

Recurrent *IDH2* R172X mutations in sinonasal undifferentiated carcinoma

Vickie Y Jo[1], Nicole G Chau[2], Jason L Hornick[1], Jeffrey F Krane[1] and Lynette M Sholl[1,3]

[1]Department of Pathology, Brigham and Women's Hospital and Harvard Medical School, Boston, MA, USA; [2]Department of Medical Oncology, Dana Farber Cancer Institute and Harvard Medical School, Boston, MA, USA and [3]Center for Advanced Molecular Diagnostics, Brigham and Women's Hospital and Harvard Medical School, Boston, MA, USA

J Pathol. 2017 Aug;242(4):400-408. doi: 10.1002/path.4915. Epub 2017 Jun 9.

Frequent IDH2 R172 mutations in undifferentiated and poorly-differentiated sinonasal carcinomas

Snjezana Dogan [1], Deborah J Chute [2], Bin Xu [3], Ryan N Ptashkin [1], Raghu Chandramohan [1], Jacklyn Casanova-Murphy [1], Khedoudja Nafa [1], Justin A Bishop [4], Simion I Chiosea [5], Edward B Stelow [6], Ian Ganly [7], David G Pfister [8], Nora Katabi [1], Ronald A Ghossein [1], Michael F Berger [1 9]

Multicenter Study Am J Surg Pathol. 2018 Aug;42(8):1067-1075.
doi: 10.1097/PAS.0000000000001064.

Immunohistochemical Detection and Molecular Characterization of IDH-mutant Sinonasal Undifferentiated Carcinomas

Jeffrey K Mito [1], Justin A Bishop [2], Peter M Sadow [3], Edward B Stelow [4], William C Faquin [3], Stacey E Mills [4], Jeffrey F Krane [1], Christopher A French [1], Christopher D M Fletcher [1], Jason L Hornick [1], Lynette M Sholl [1 5], Vickie Y Jo [1]

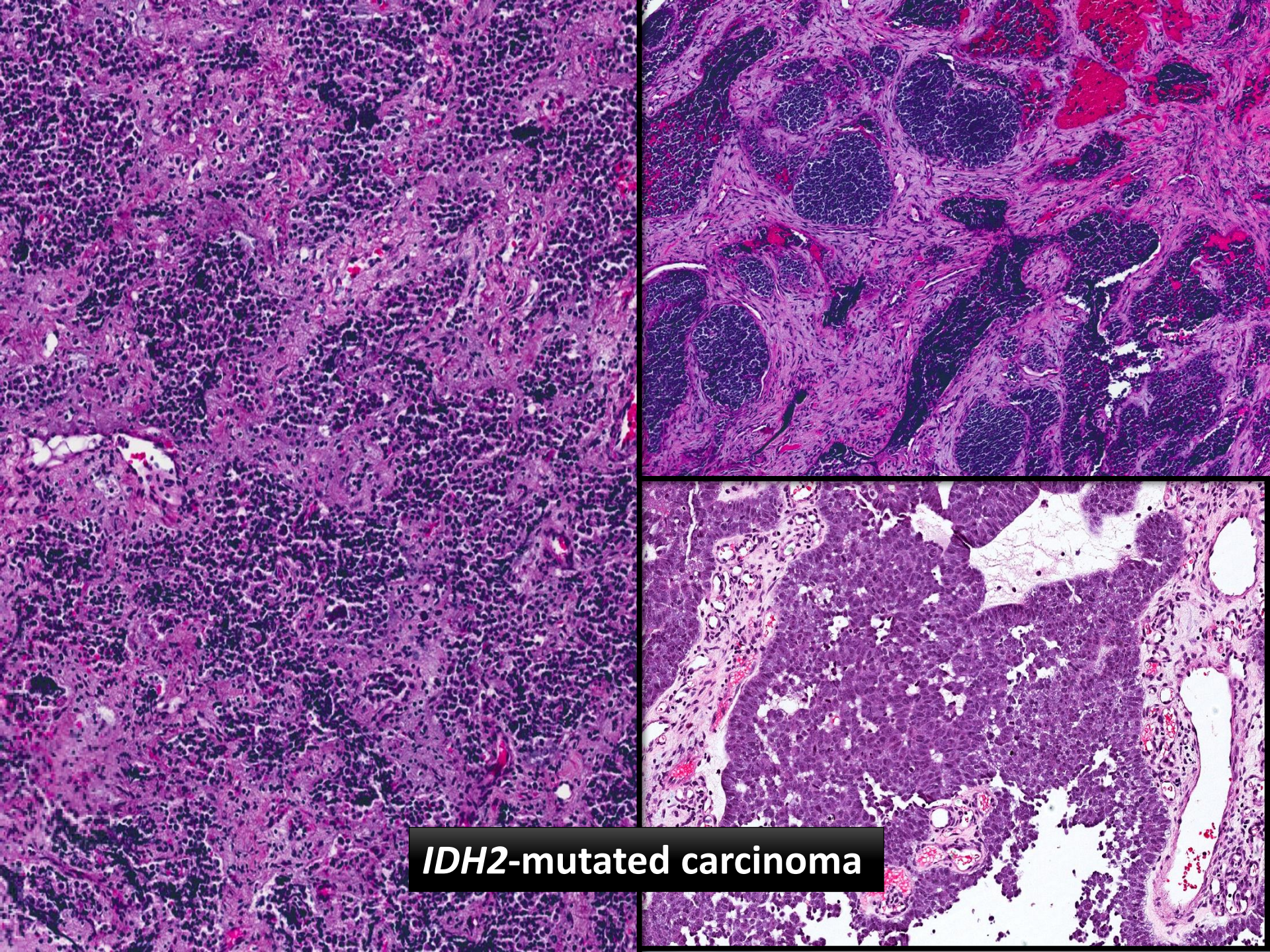
IDH2-mutated carcinoma

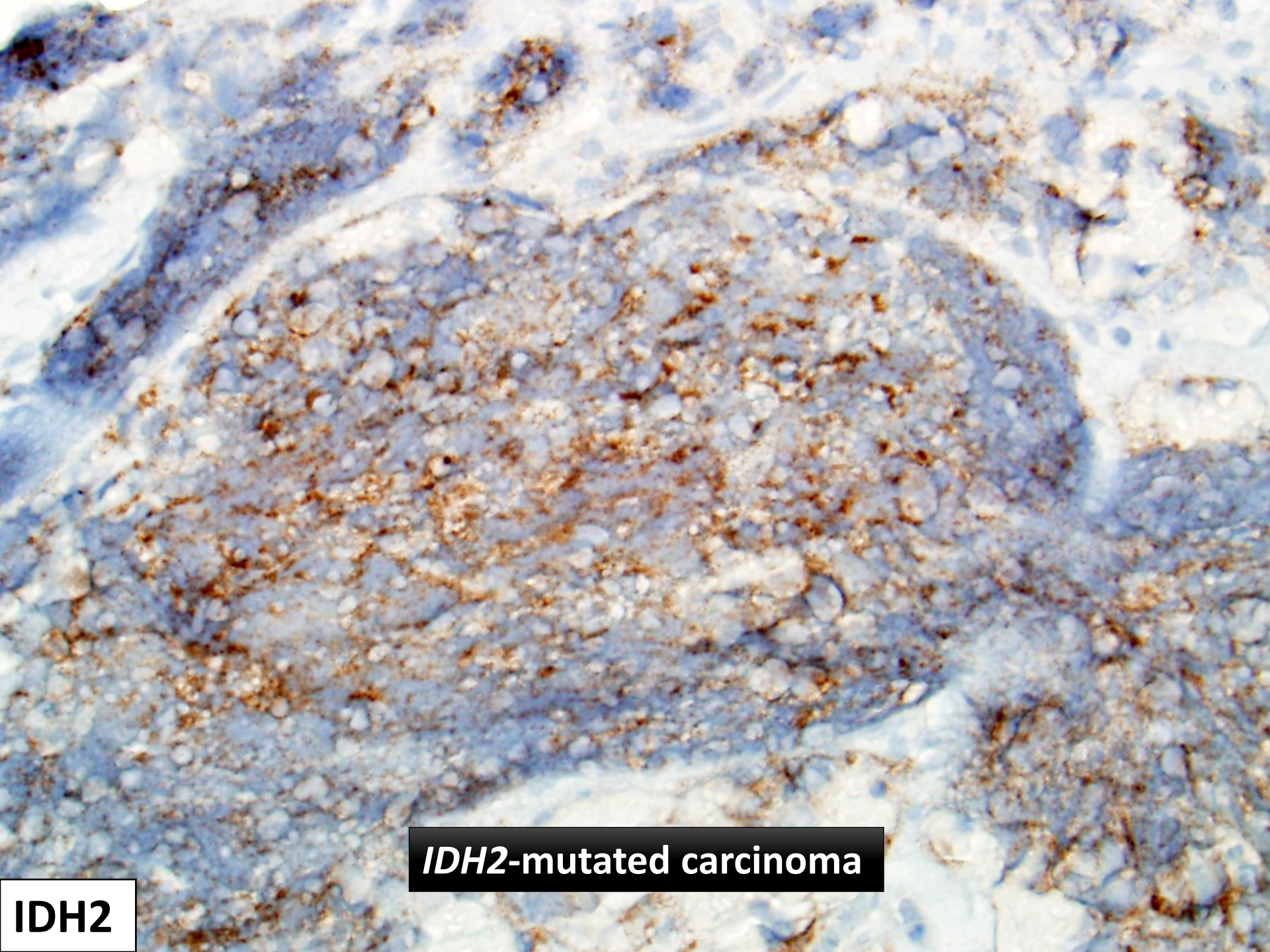
IDH2-mutated carcinoma
IDH2

Sinonasal Neuroendocrine Carcinomas

Neuroendocrine Carcinoma

- Rare
- Ethmoid > nasal cavity > maxillary
- Conceptually identical to neuroendocrine carcinomas of the lung and other sites.
  - Small cell carcinoma
  - Large cell neuroendocrine carcinoma
- Very aggressive

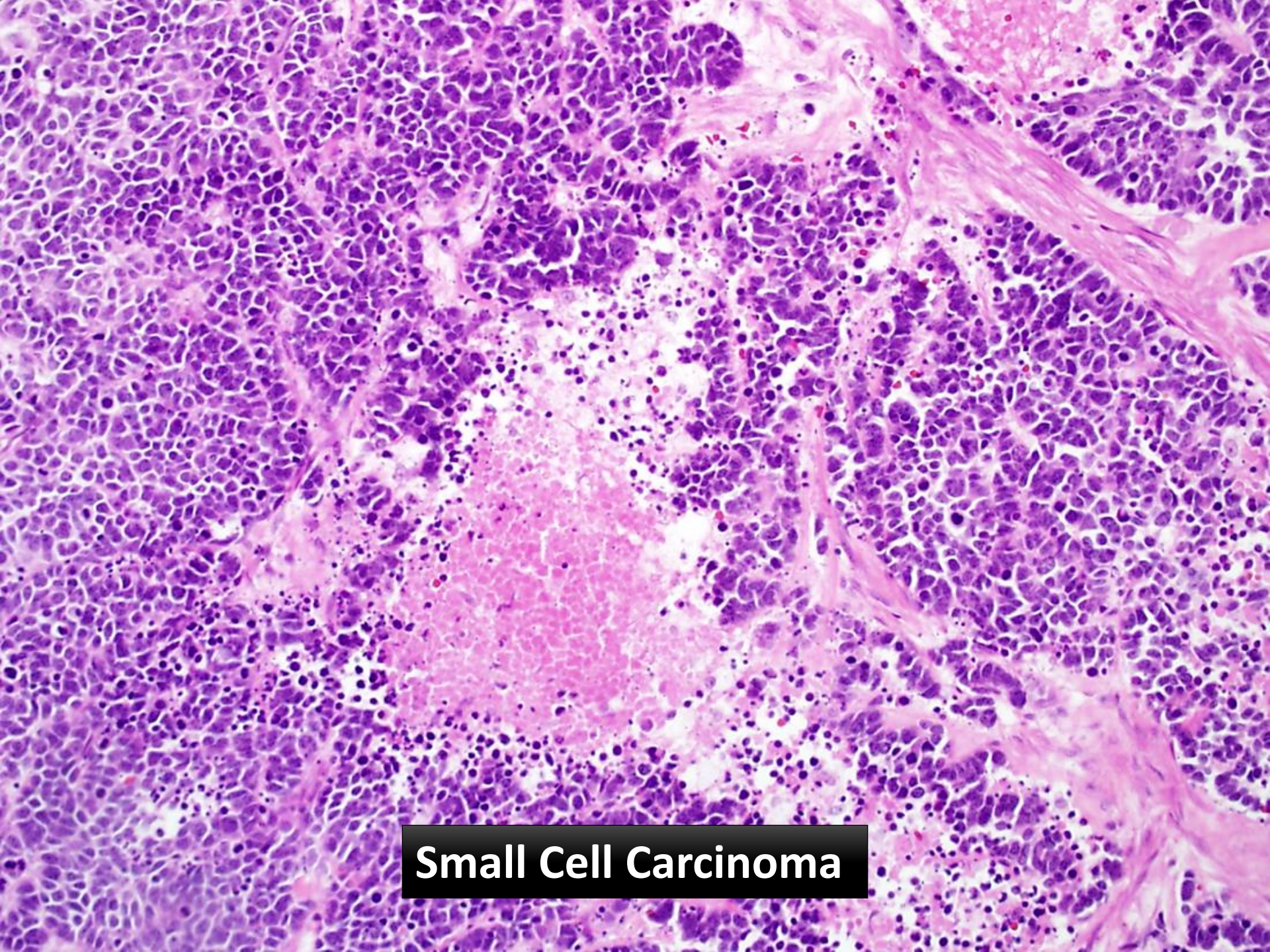
Small Cell Carcinoma

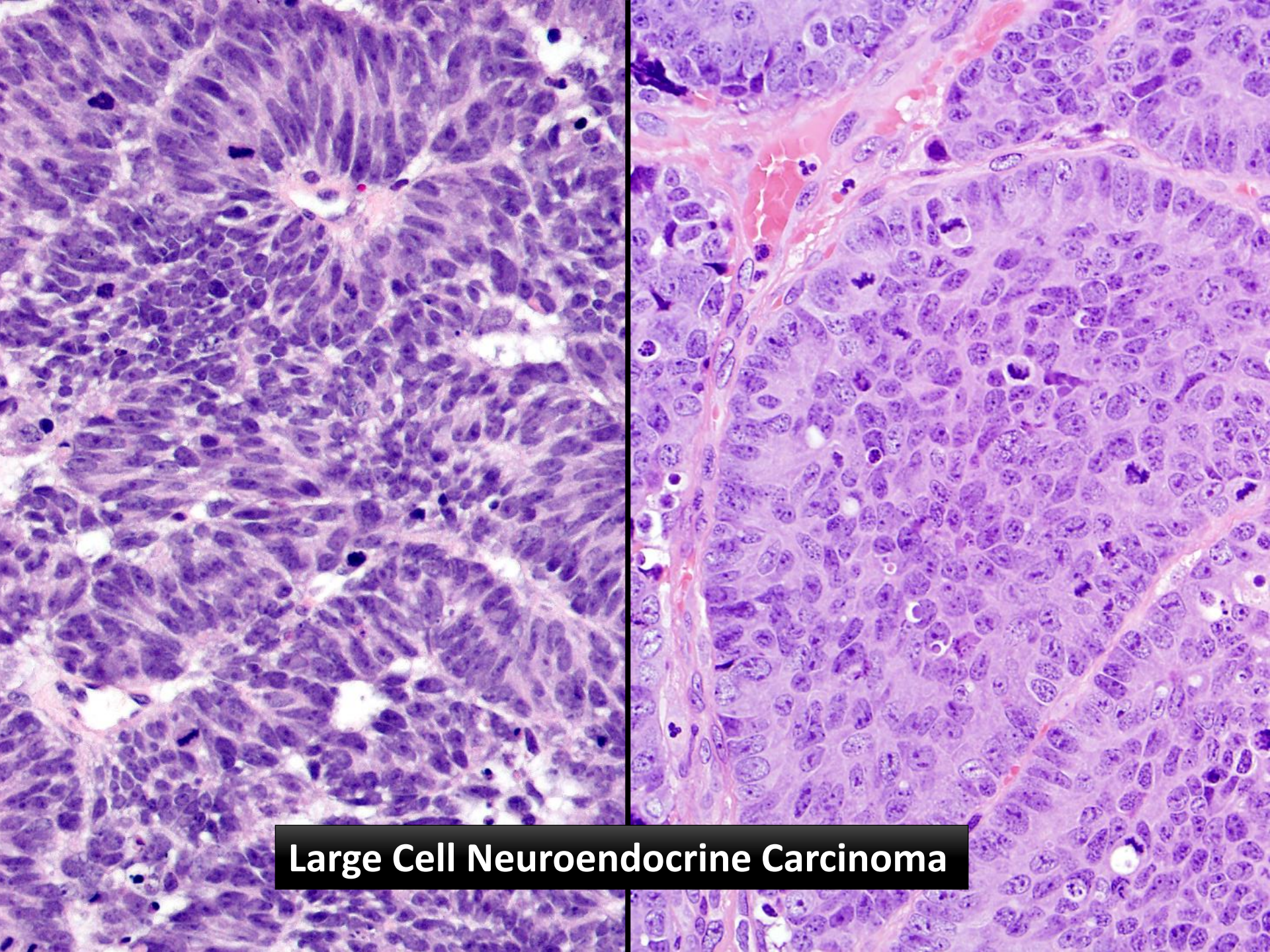
Large Cell Neuroendocrine Carcinoma

Sinonasal Neuroendocrine Carcinomas

- Taken out of the sinonasal section into a new "neuroendocrine" section
- However, sinonasal neuroendocrine carcinomas are unique
  - Pure small cell or LCNEC very rare, and usually HPV+

16. Neuroendocrine neoplasms and paraganglioma

- Introduction
- **Neuroendocrine neoplasms**
  - *Neuroendocrine tumours*
    - Neuroendocrine tumour
    - Ectopic or invasive PitNET/adenoma
  - *Neuroendocrine carcinoma*
    - Small cell neuroendocrine carcinoma
    - Large cell neuroendocrine carcinoma
    - Merkel cell carcinoma
- **Paraganglion tumours**
  - Head and neck paraganglioma

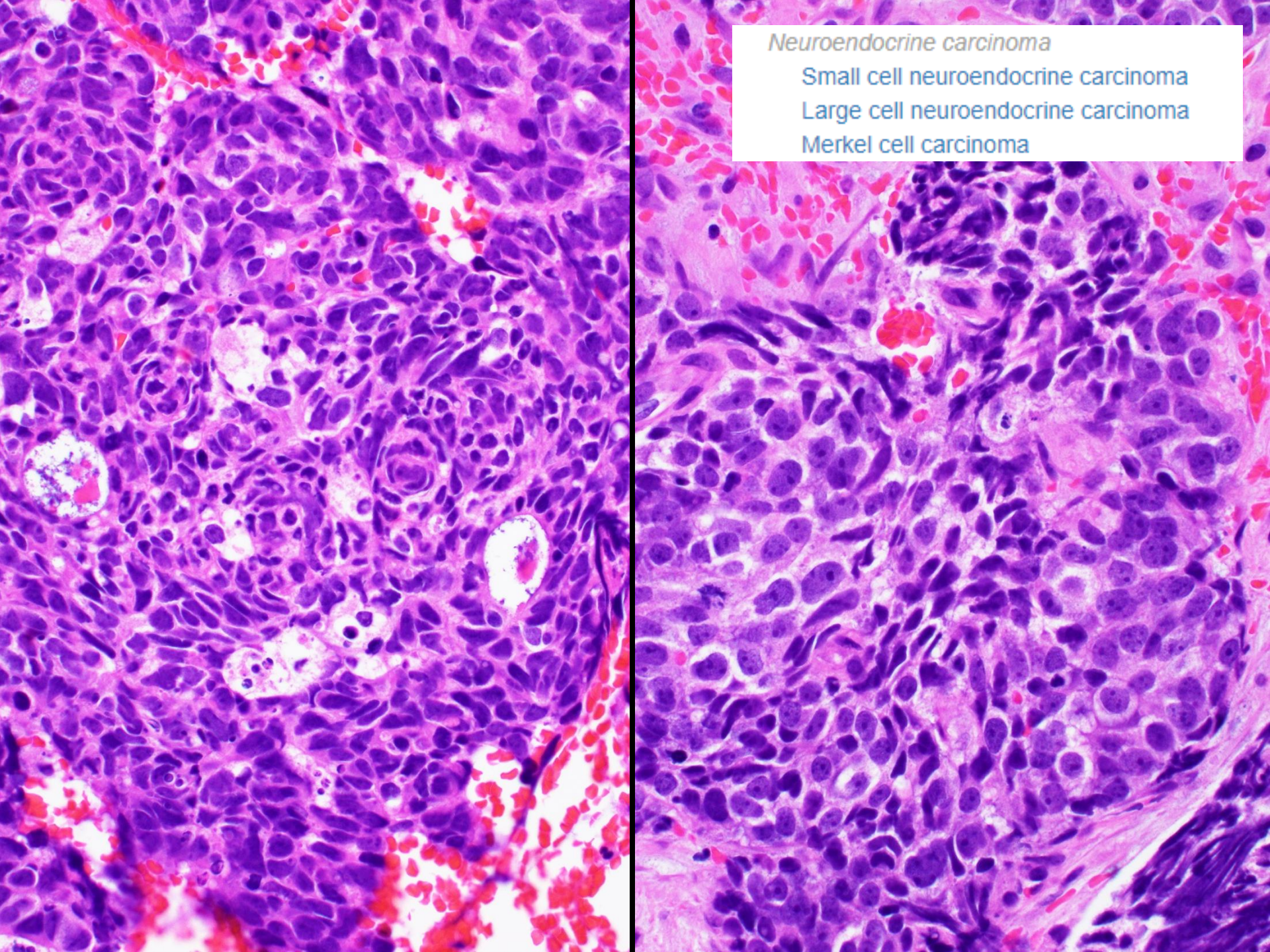
Neuroendocrine carcinoma
Small cell neuroendocrine carcinoma
Large cell neuroendocrine carcinoma
Merkel cell carcinoma

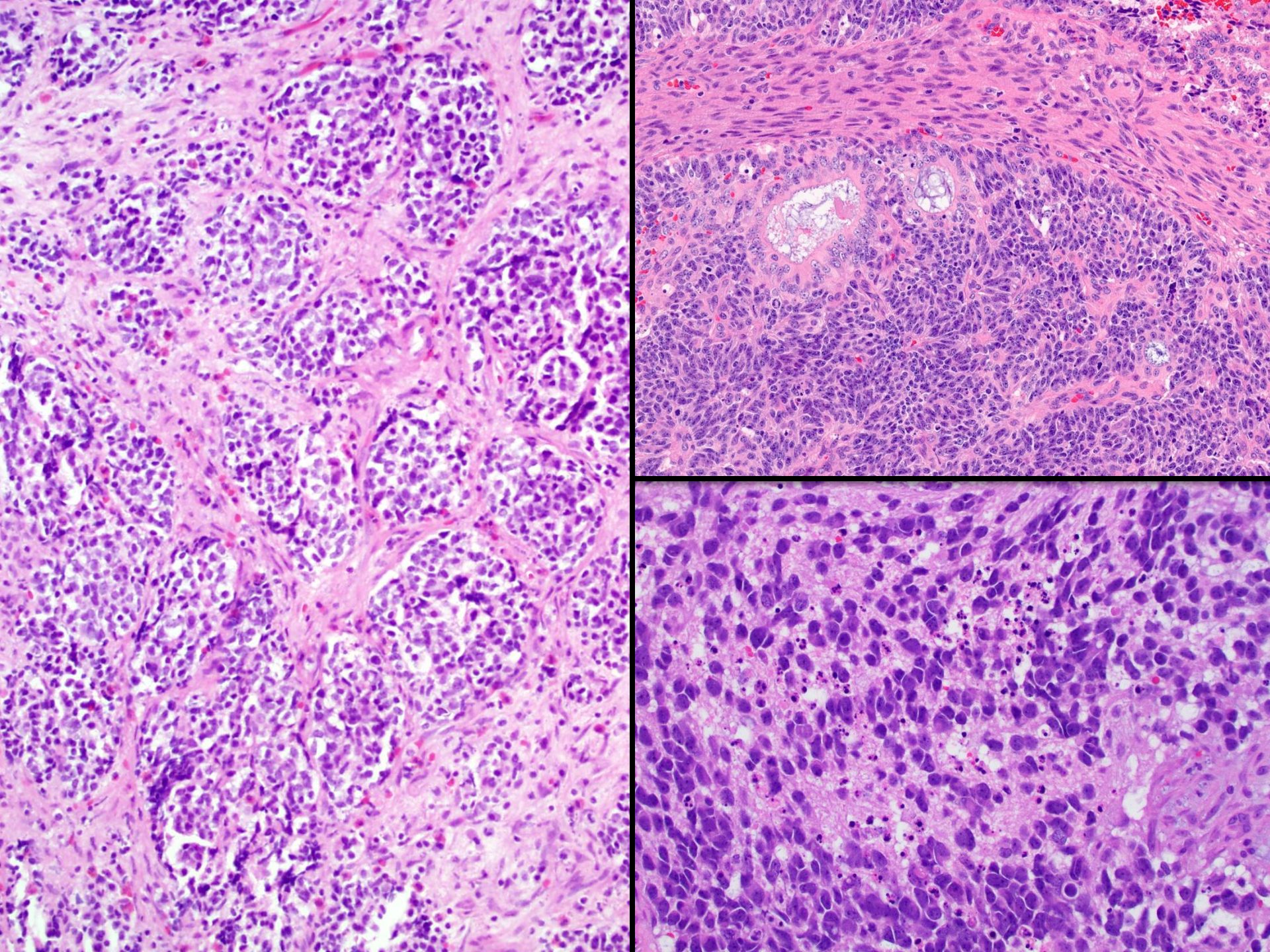

Neuroendocrine carcinoma

- Small cell neuroendocrine carcinoma
- Large cell neuroendocrine carcinoma
- Merkel cell carcinoma

tern. Up to one-third of ONB may react focally for pancytokeratin { 11904342 ; 21792956 }. Rarely, cases can be more diffusely positive with epithelial structures, blurring the distinction between ONB and neuroendocrine carcinoma or non-intestinal adenocarcinoma { 28168398 }. Ki-

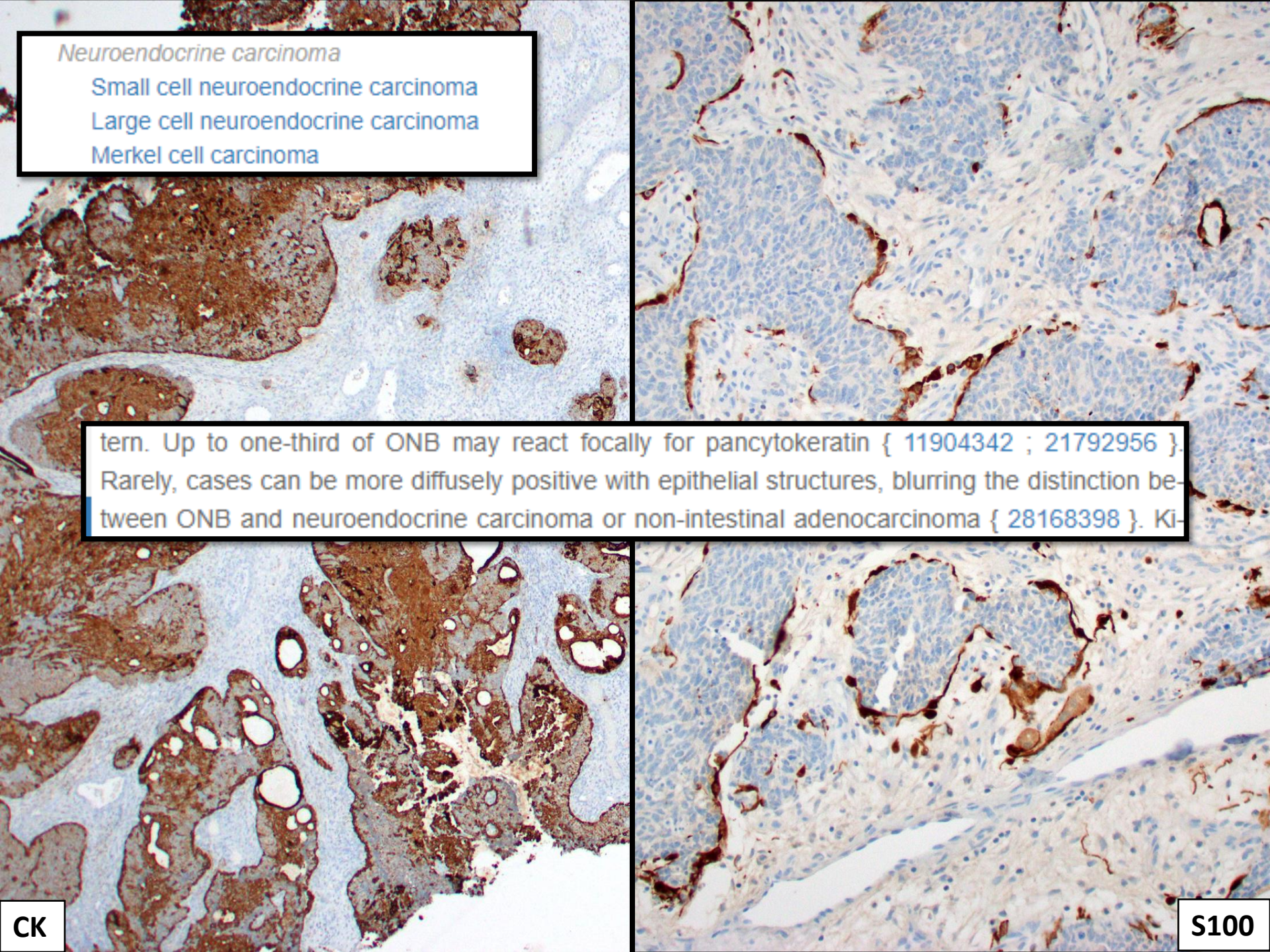

Sinonasal Tumors With Neuroepithelial Differentiation (Olfactory Carcinoma)

Delineation of Their Pathologic and Clinical Features With Insights into Their Relationship to Olfactory Neuroblastoma and Sinonasal Carcinoma

Lisa M. Rooper, MD,† Justin A. Bishop, MD,‡ William C. Faquin, MD, PhD,§ Robert D. Foss, DDS,‖¶ Gary L. Gallia, MD, PhD,†#** Vickie Y. Jo, MD,†† James S. Lewis Jr, MD,‡‡§§ Michiya Nishino, MD, PhD,‖‖ Edward B. Stelow, MD,¶¶ Lester D.R. Thompson, MD,## Bruce M. Wenig, MD,*** and William H. Westra, MD†††*

Abstract: Olfactory carcinoma is one of many names applied to sinonasal malignancies with histologic similarity to olfactory neuroblastoma (ONB) but cytokeratin expression or gland formation. It is unclear whether these neuroepithelial tumors represent a unified category and if they are separate from ONB and currently-recognized sinonasal carcinomas. This study aims to explore their clinicopathologic characteristics based on a large collective experience. A total of 53 sinonasal tumors with neuroepithelial differentiation were identified affecting 41 men and 12 women, median age 47 years (range: 12 to 82 y). The vast majority arose in the superior nasal cavity and presented at the high Kadish-Morita stage. Frequent histologic findings included (1) lobulated and solid growth, (2) rosettes and/or neurofibrillary stroma, (3) high-grade cytology, (4) complex, often ciliated glands, (5) nonfocal pancytokeratin expression, (6) neuroendocrine pos +itivity, and (7) variable S100-positive sustentacular cells. Twelve patients with available follow-up (48%) developed progressive disease at a median 8 months (range: 0 to 114 mo to progression), and 7 (28%) died of disease. Despite disparate historical terminology, neuroepithelial differentiation is a recurrent and recognizable histologic pattern that is associated with aggressive behavior in sinonasal tumors. While tumors with this phenotype may originate from olfactory mucosa, well-developed epithelial features warrant separation from conventional ONB and neural elements distinguish them from most sinonasal carcinomas. Although their full histogenesis remains uncertain and some heterogeneity may exist, we propose that this pattern is sufficiently distinctive to merit separate recognition as olfactory carcinoma. Use of consistent nomenclature may facilitate greater recognition of tumors with this phenotype and understanding of their pathogenesis and classification.

Key Words: nasal neoplasms, olfactory neuroblastoma, olfactory carcinoma, neuroendocrine carcinoma, adenocarcinoma, teratocarcinosarcoma, immunohistochemistry

(*Am J Surg Pathol* 2022;00:000–000)

From the Departments of *Pathology; †Oncology; ‖Dermatology; **Otolaryngology—Head and Neck Surgery; #Neurosurgery, The Johns Hopkins University School of Medicine, Baltimore, MD;

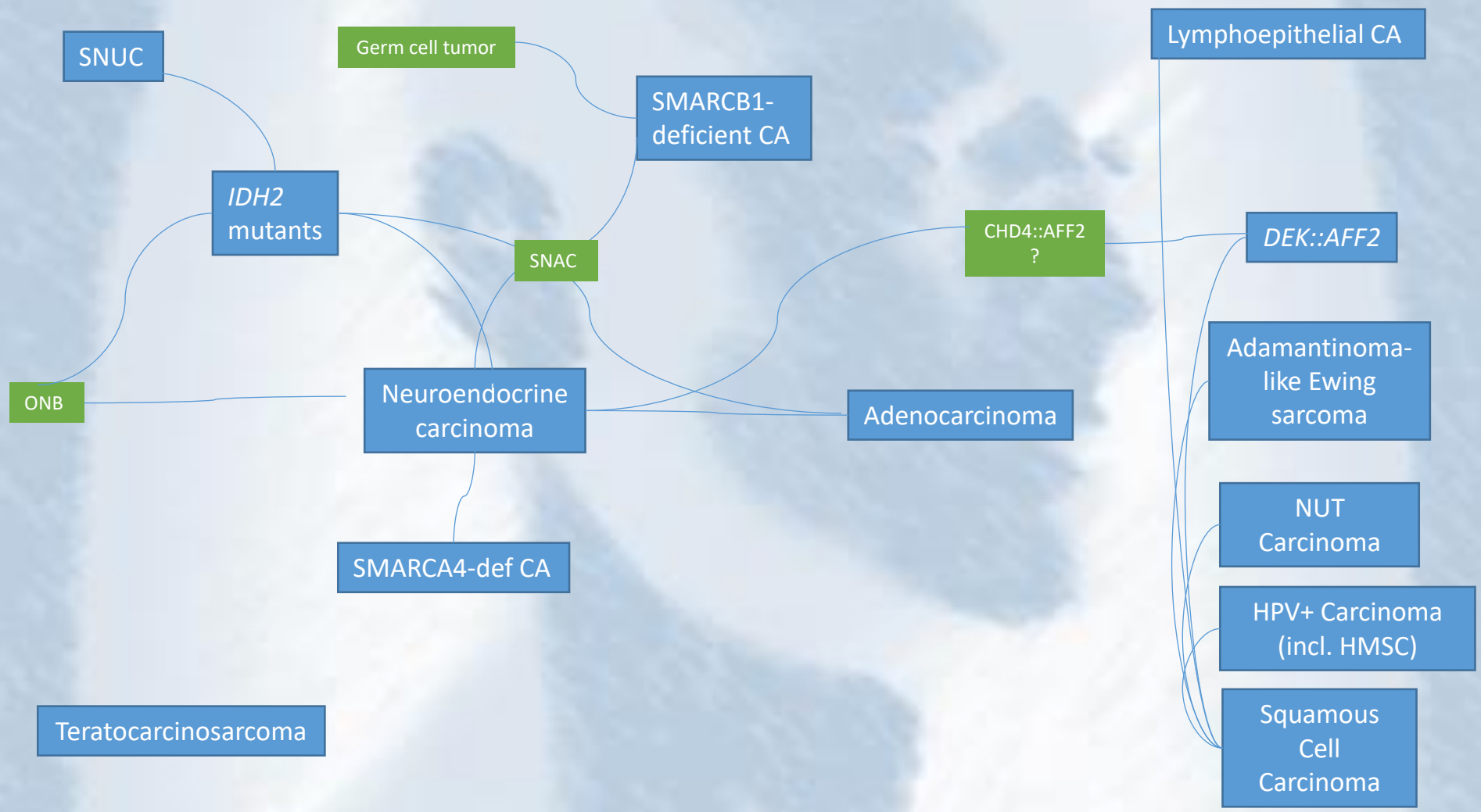
SNUC
Germ cell tumor
SMARCB1-deficient CA
Lymphoepithelial CA
IDH2 mutants
SNAC
CHD4::AFF2 ?
DEK::AFF2
Adamantinoma-like Ewing sarcoma
ONB
Neuroendocrine carcinoma
Adenocarcinoma
NUT Carcinoma
SMARCA4-def CA
HPV+ Carcinoma (incl. HMSC)
Squamous Cell Carcinoma
Teratocarcinosarcoma

Back to the case

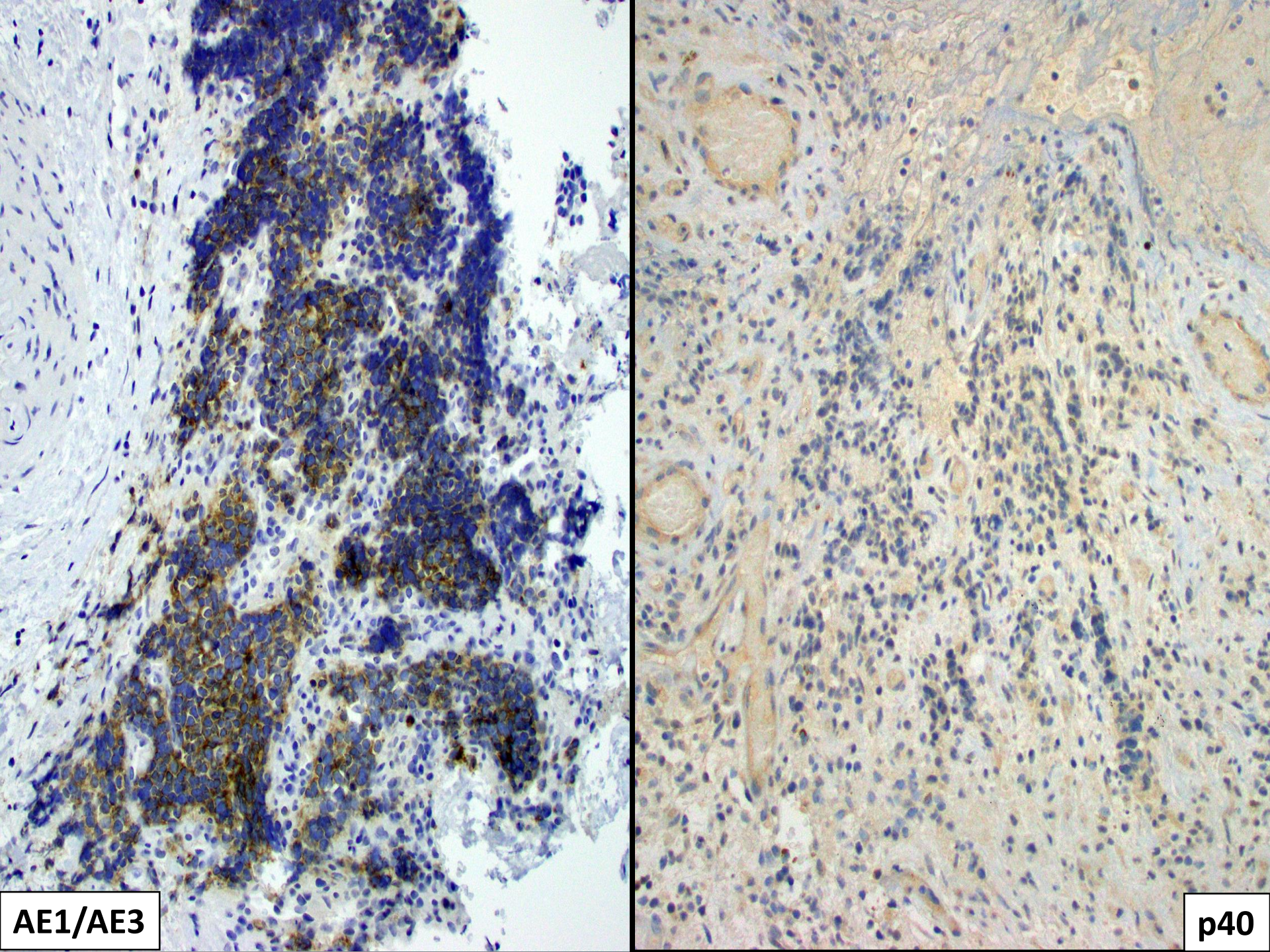
AE1/AE3
p40

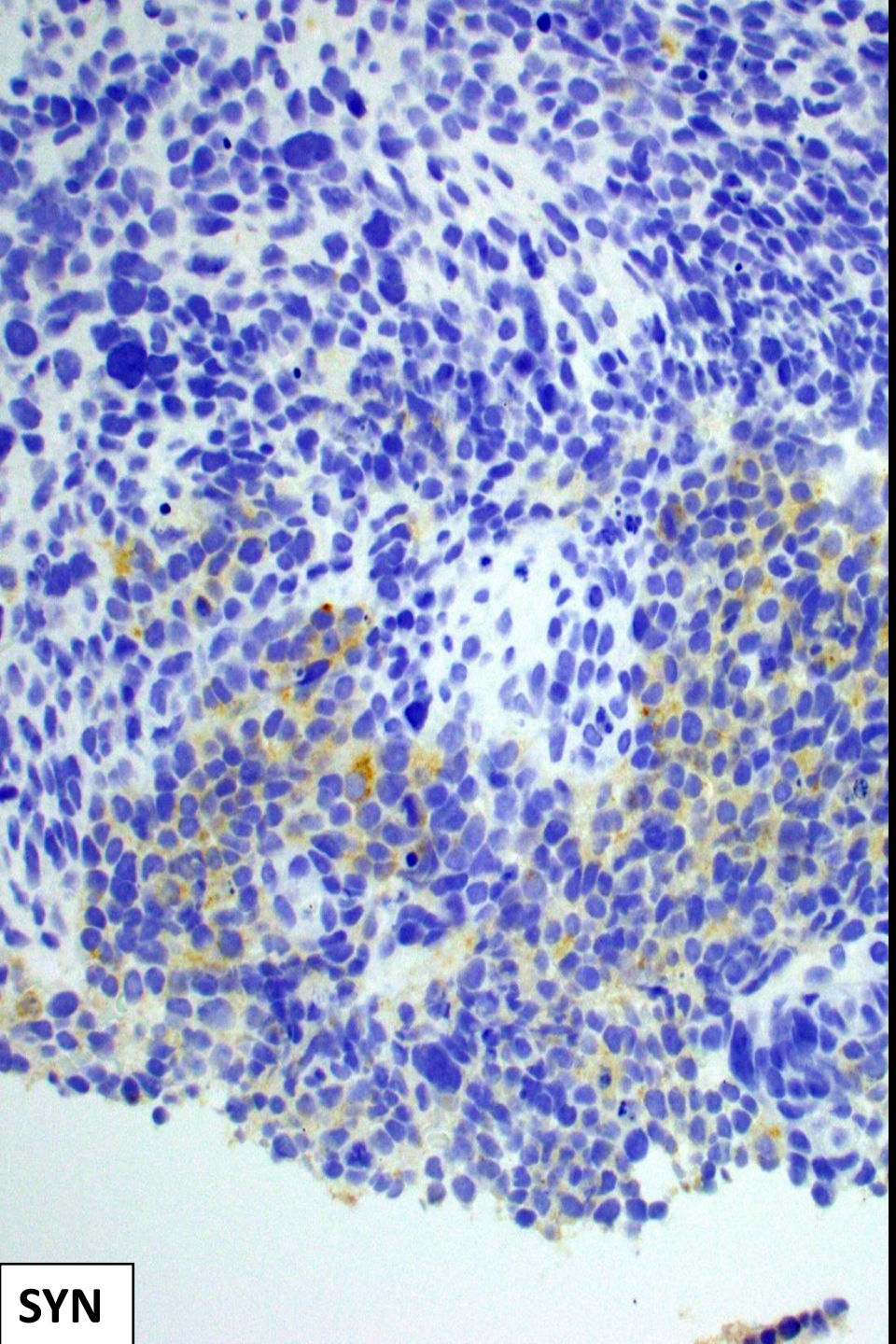
SYN

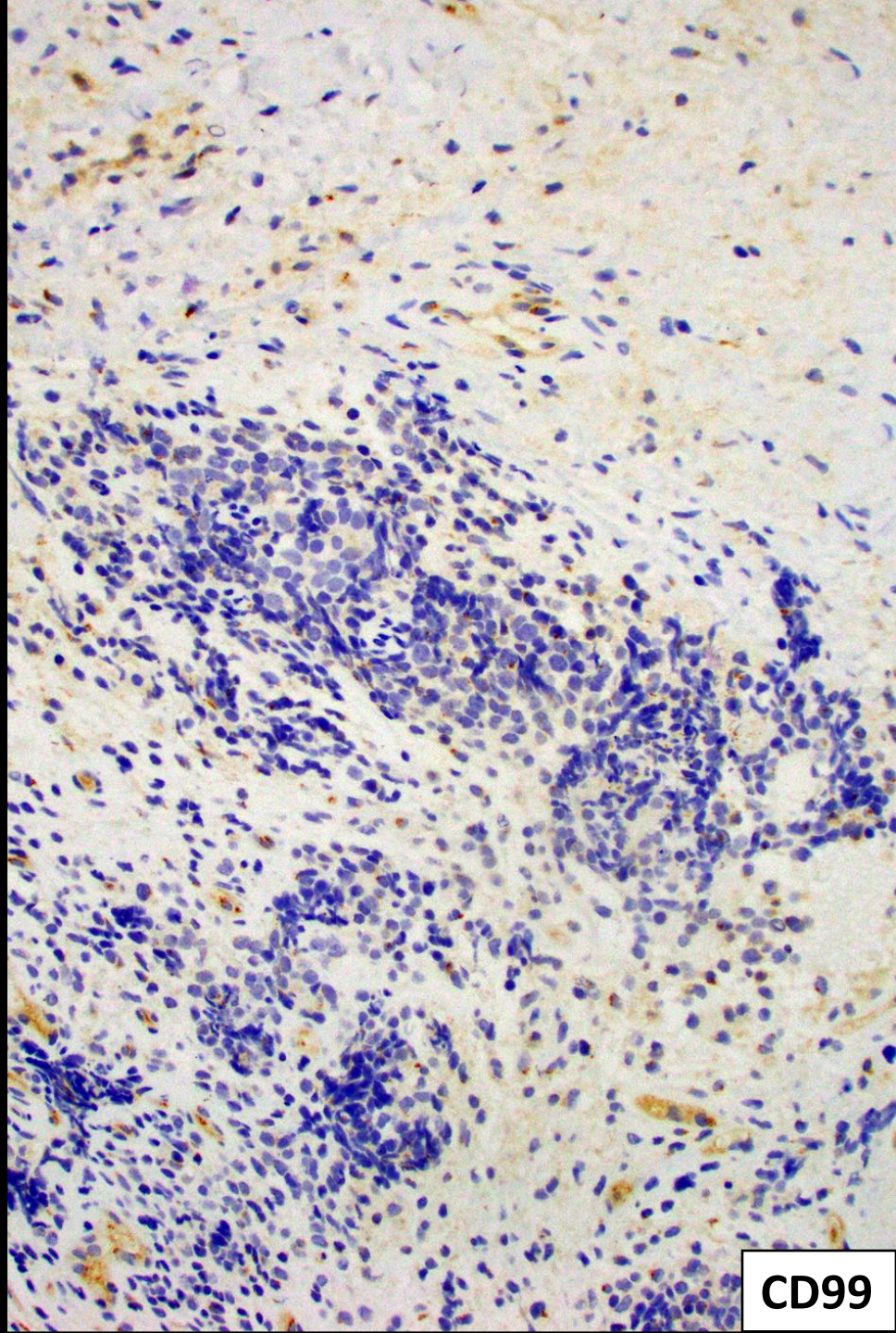
CD99

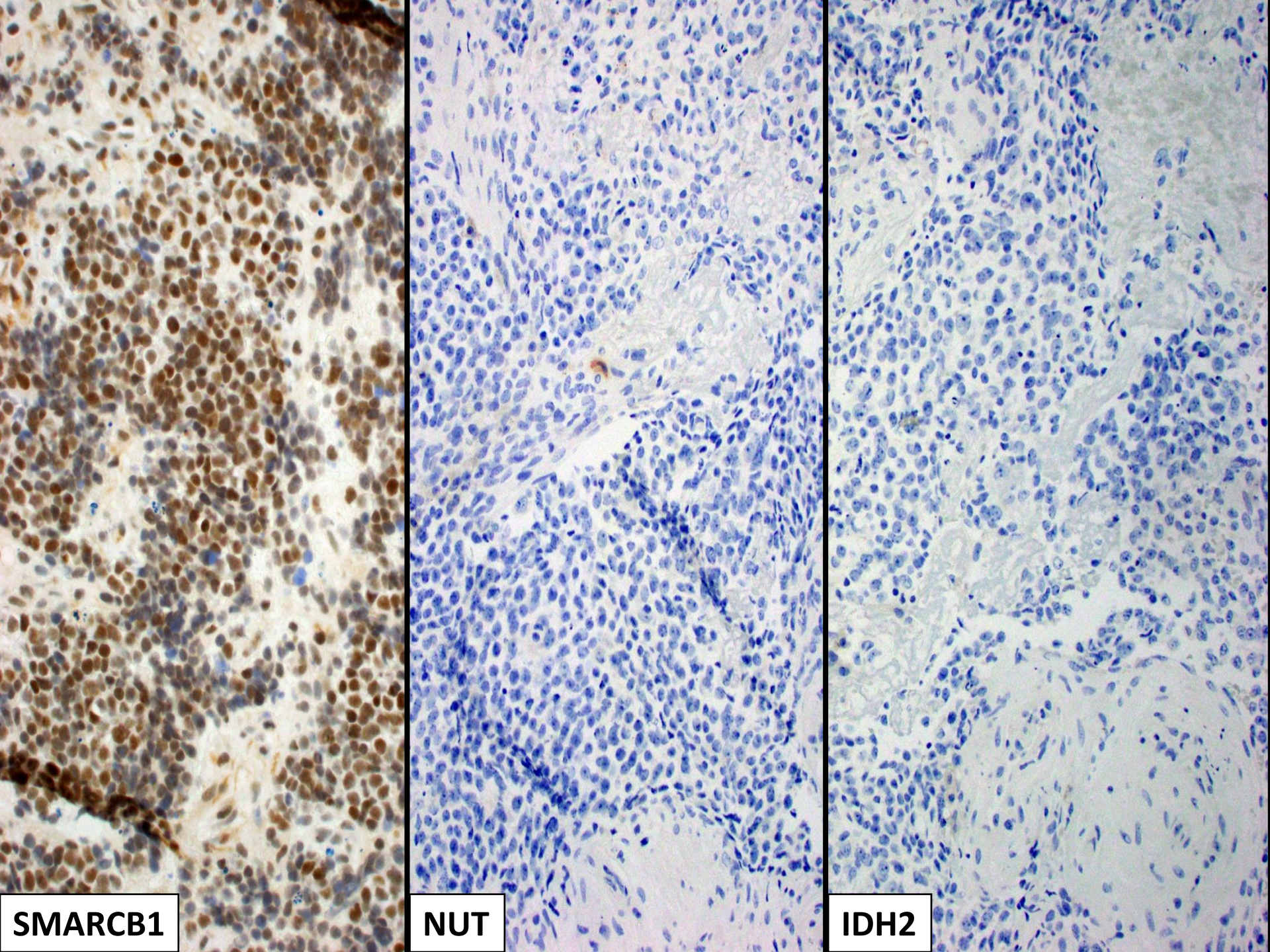
SMARCB1
NUT
IDH2

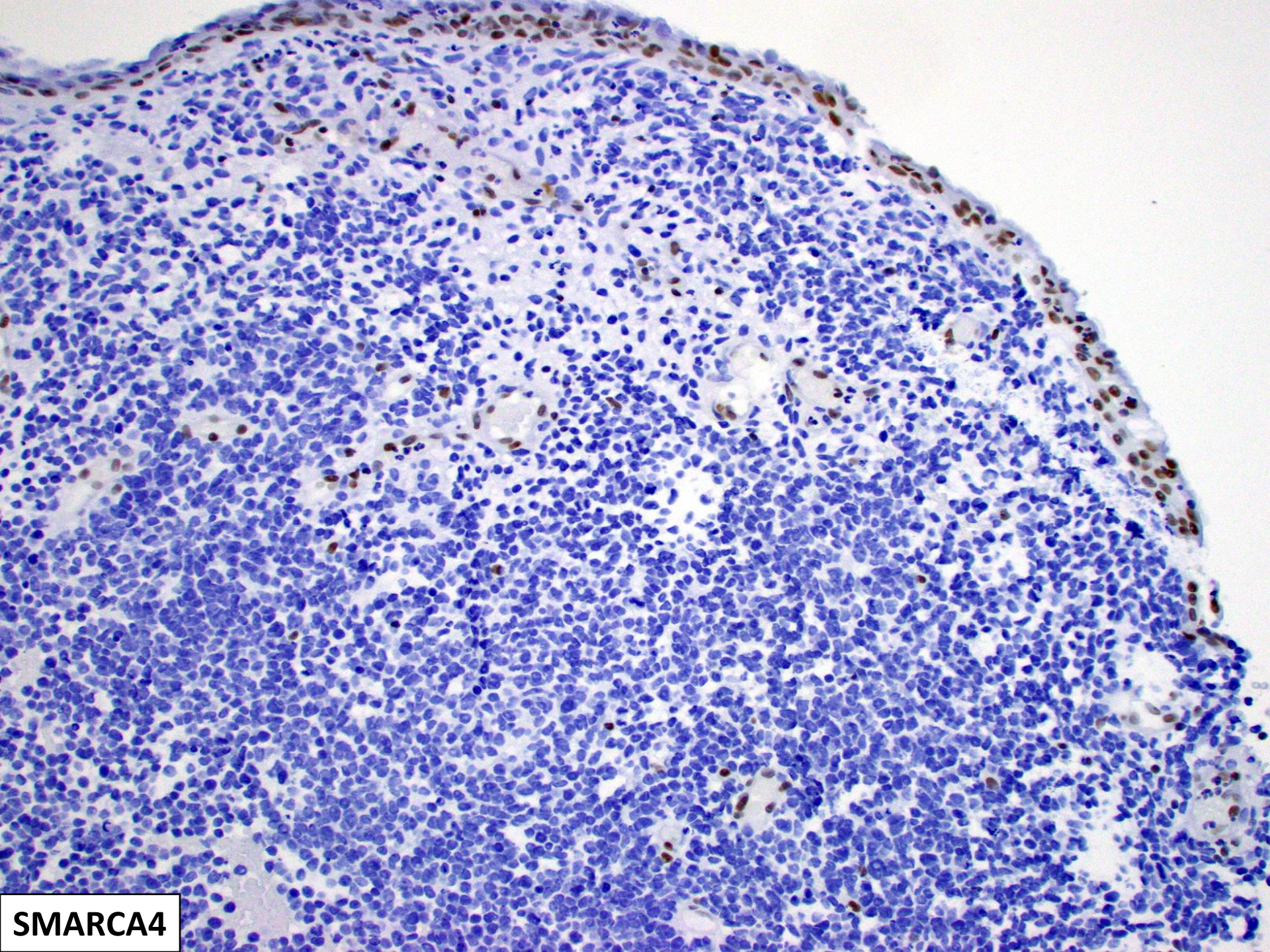
SMARCA4

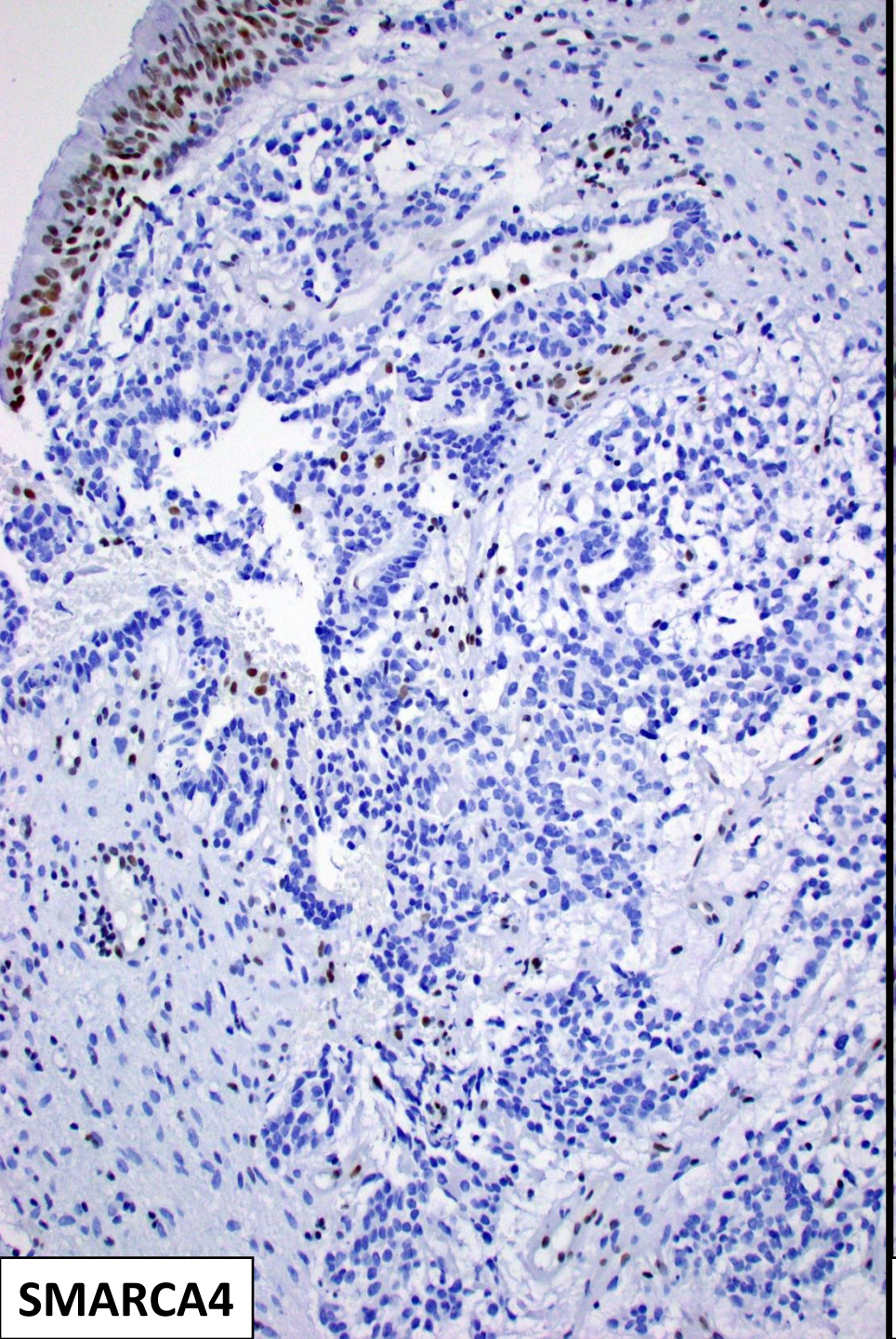
SMARCA4

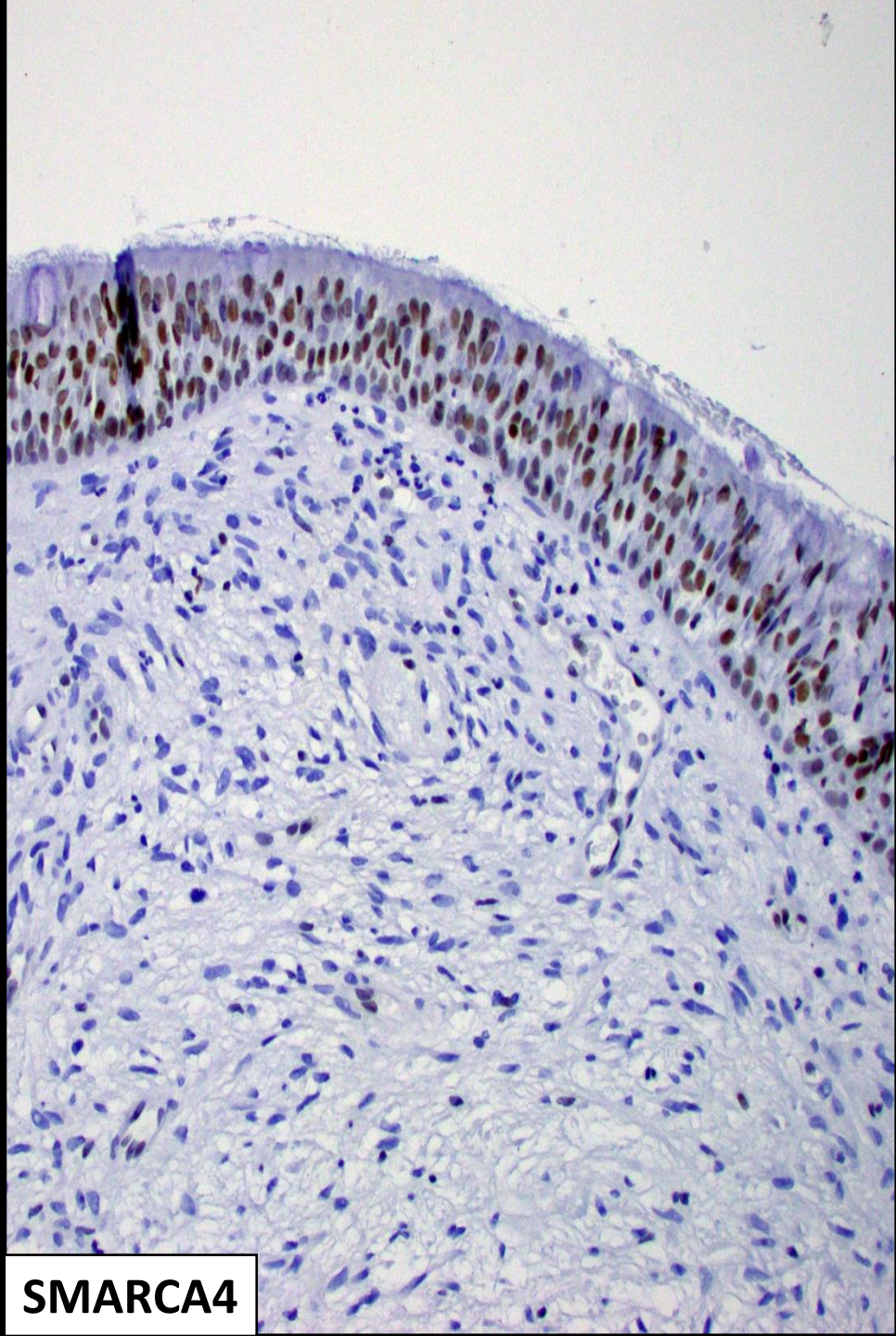
SMARCA4

Final Diagnosis

- Sinonasal teratocarcinosarcoma

Sinonasal Teratocarcinosarcoma

- Rare (but not as rare as previously thought)
- Nasal cavity > ethmoid > maxillary
- Unclear histogenesis:
  - ? Germ cell
  - ? Olfactory neuroepithelium
- Traditionally thought to be aggressive, though not as much as initially reported

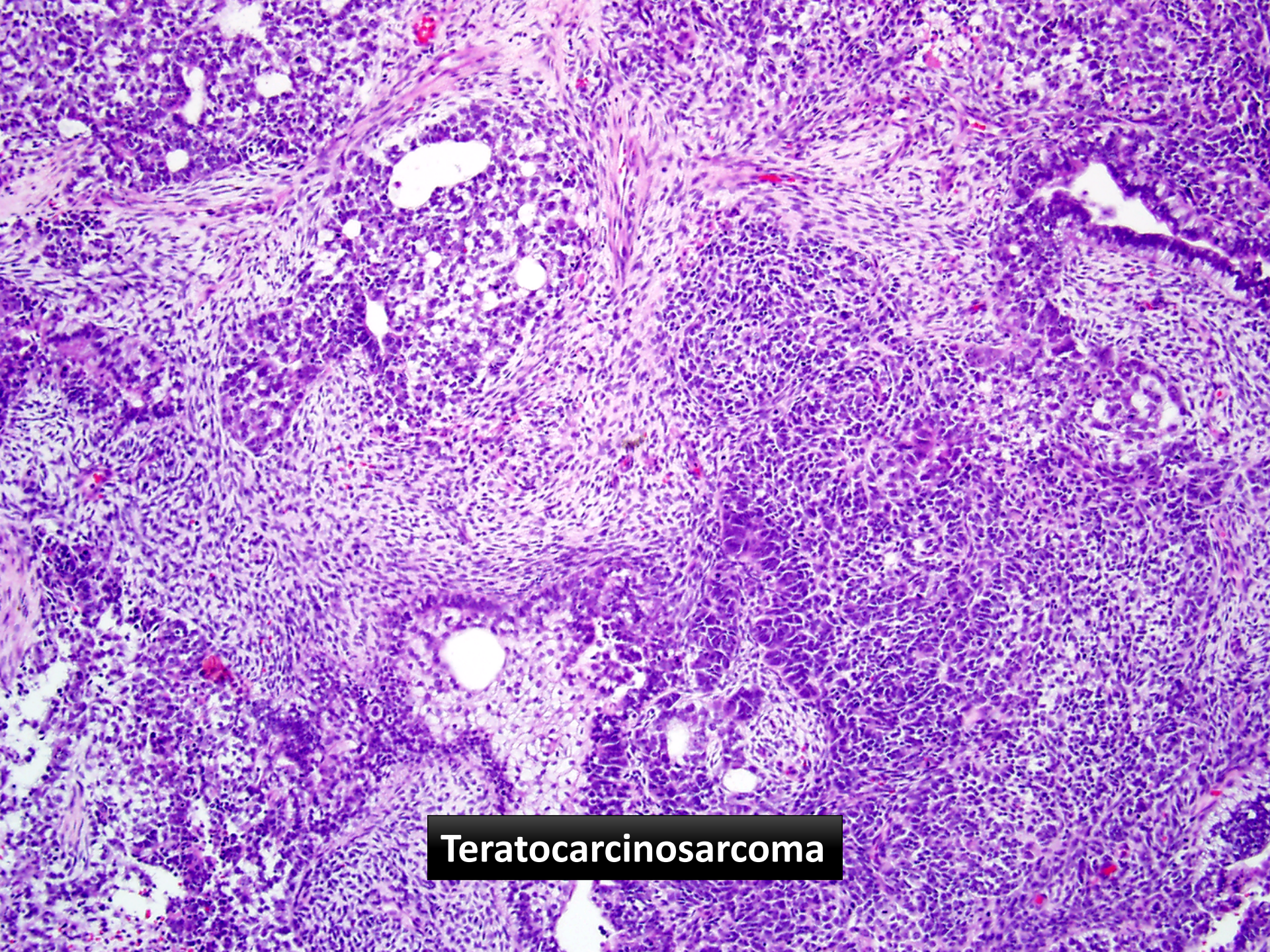
Teratocarcinosarcoma

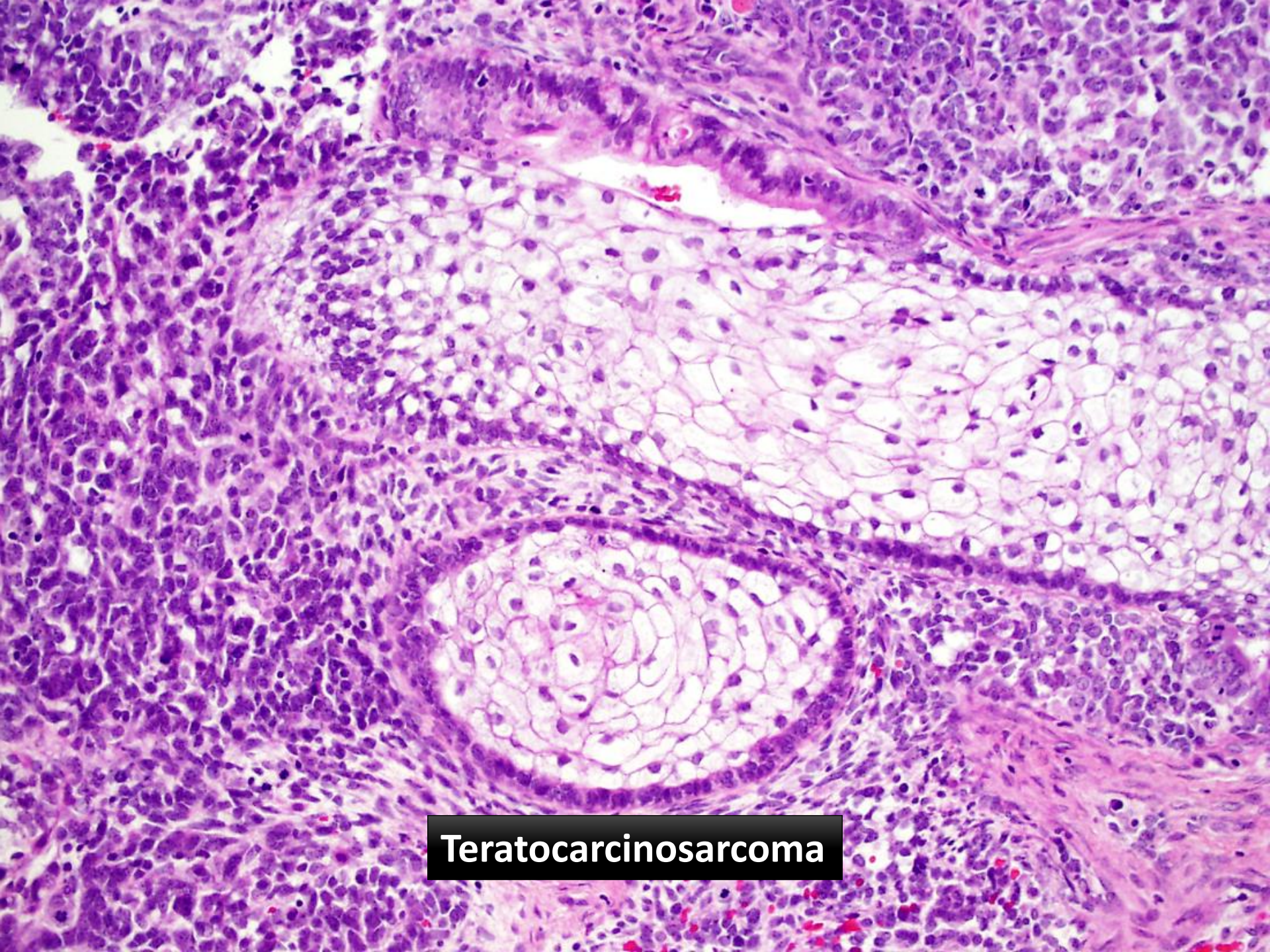
Teratocarcinosarcoma

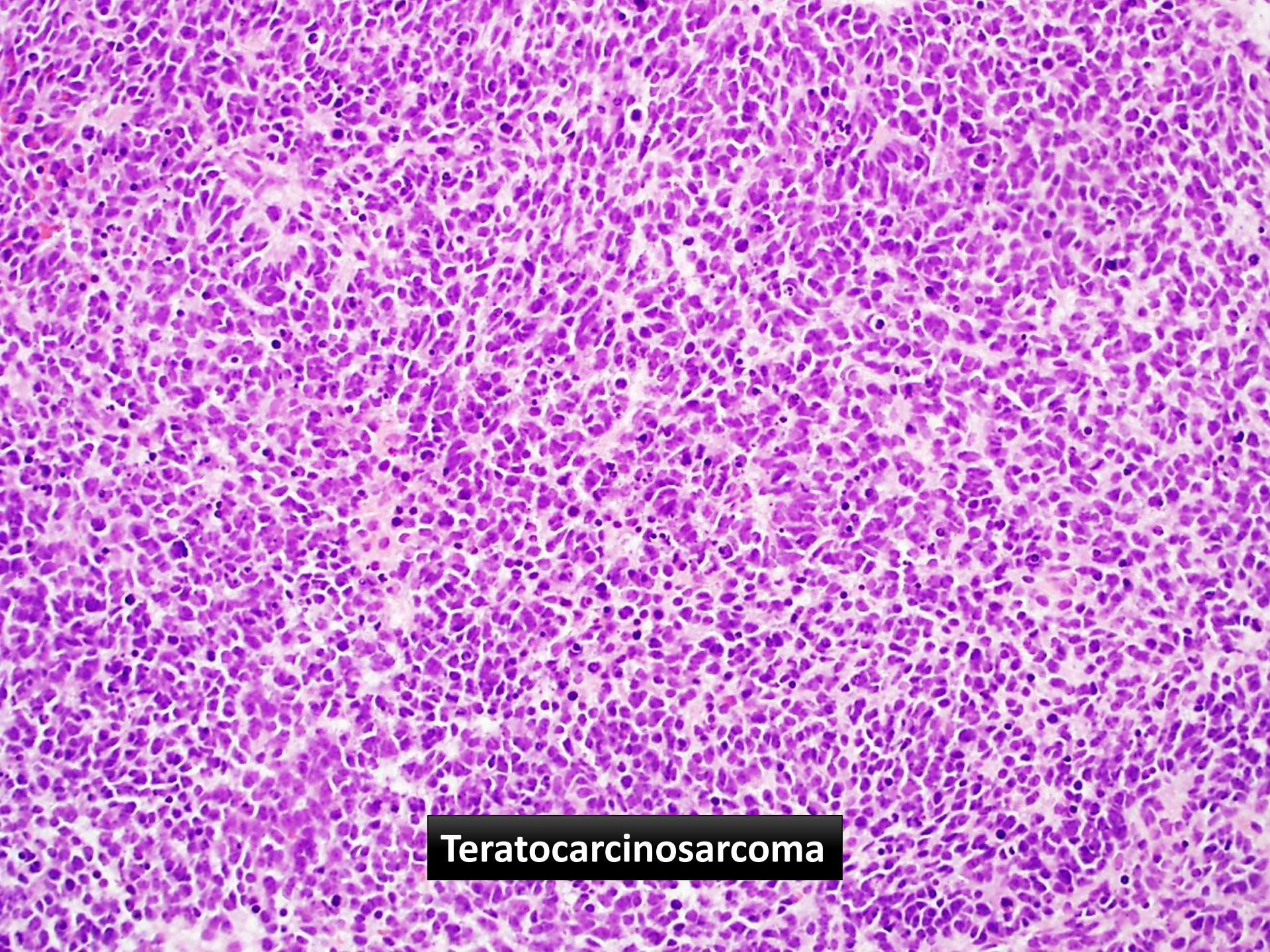
Teratocarcinosarcoma

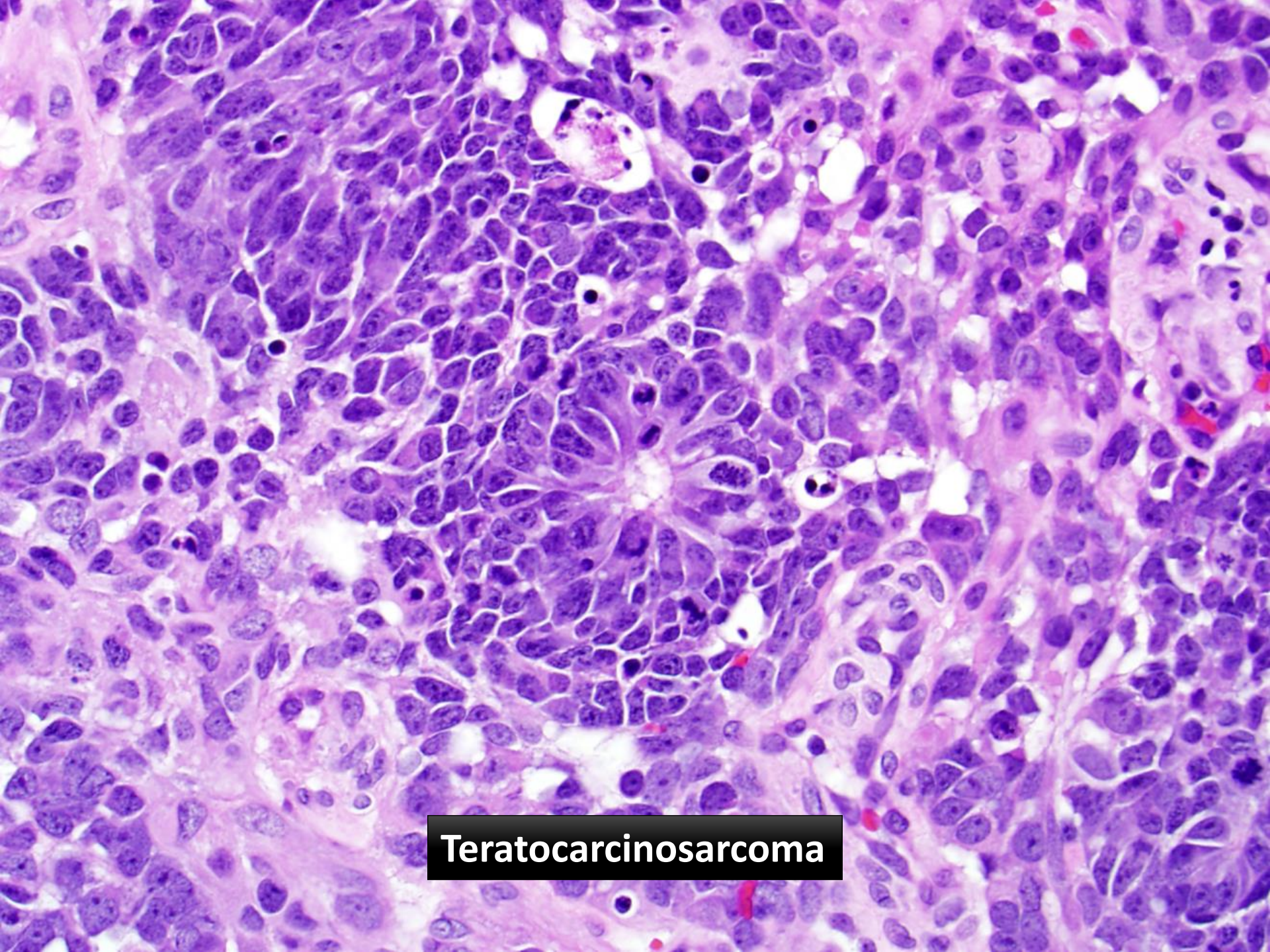
Teratocarcinosarcoma

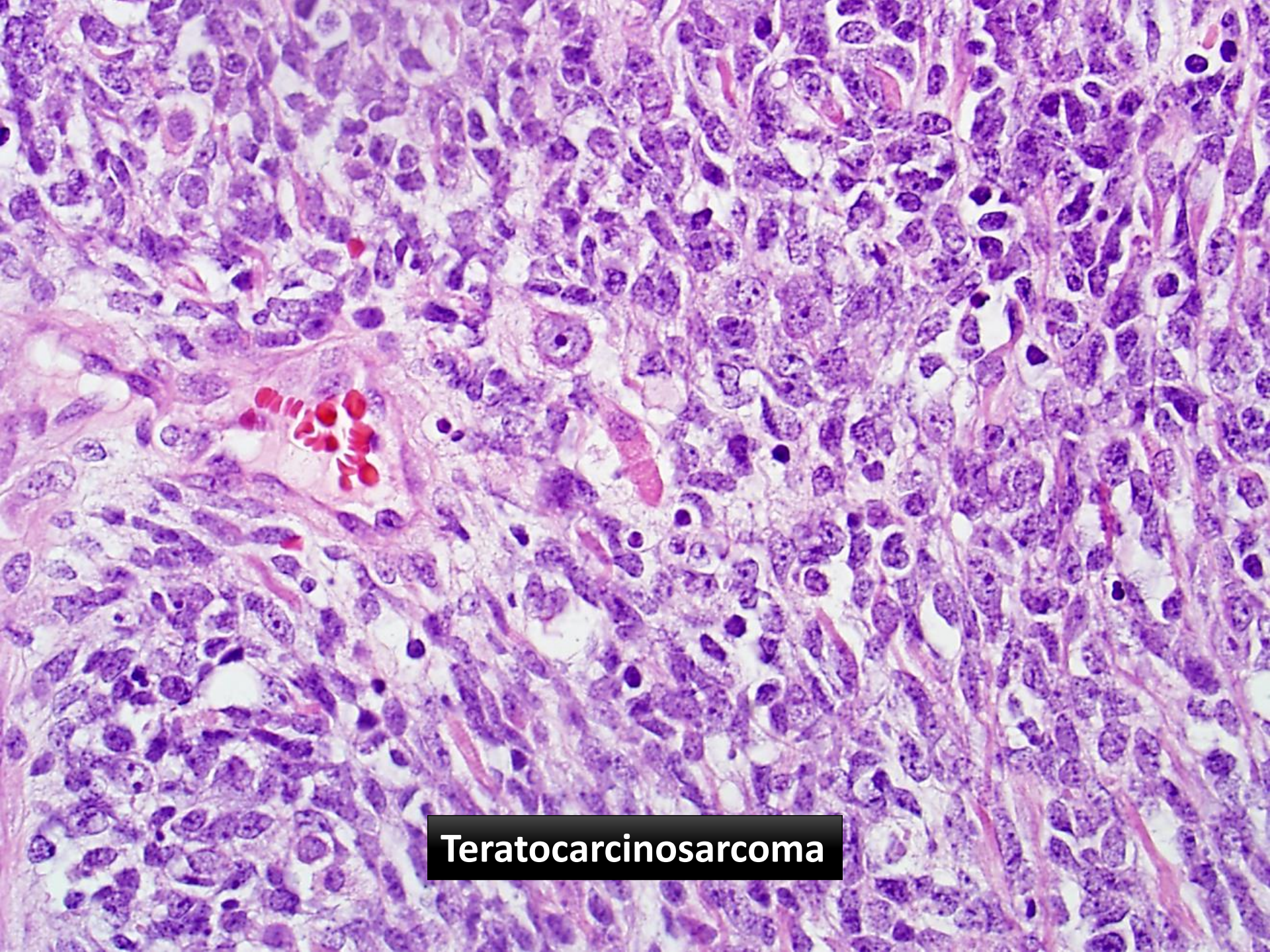
Teratocarcinosarcoma

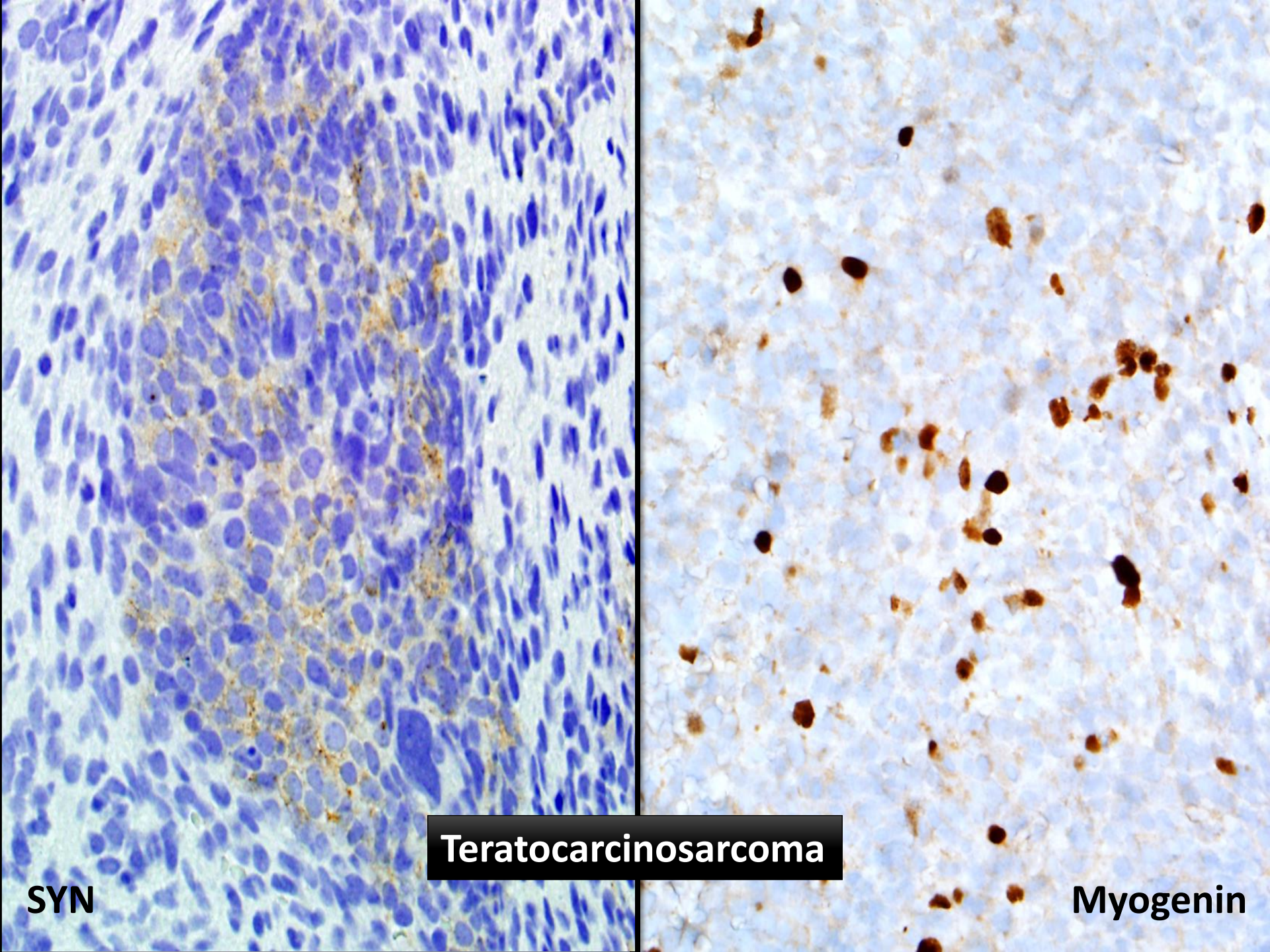
Teratocarcinosarcoma
SYN
Myogenin

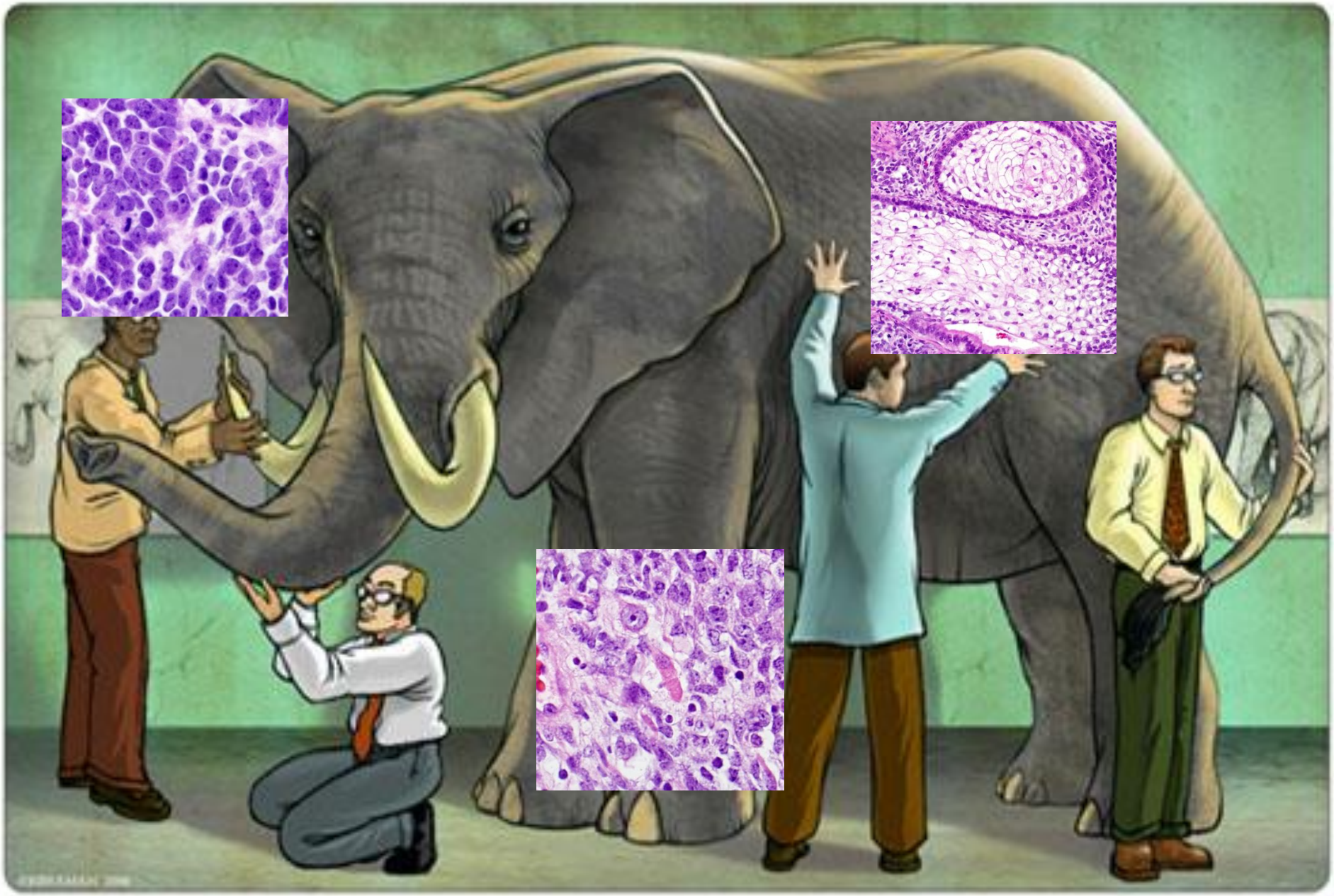

Sinonasal Teratocarcinosarcoma Genetics

- Rooper, et al. AJSP 2020; 44:1331-9:
  - 82% of cases have complete or partial SMARCA4 loss by IHC
  - Among other SN tumors, only other SWI/SNF tumors showed loss
- Rooper, et al. AJSP in press:
  - 71% with *SMARCA4* mutations
  - 35% with *CTNNB1* mutations (not mutually exclusive with *SMARCA4* mutations)
  - Abnormal IHC expression does not always correlate with mutational status

22 of 30 have some loss of SMARCA4

- 4 partial
- 18 complete
- Mutation confirmed in 11 of 14

Beta catenin+ in of 14 of 21

- Mutation confirmed in 4 of 8

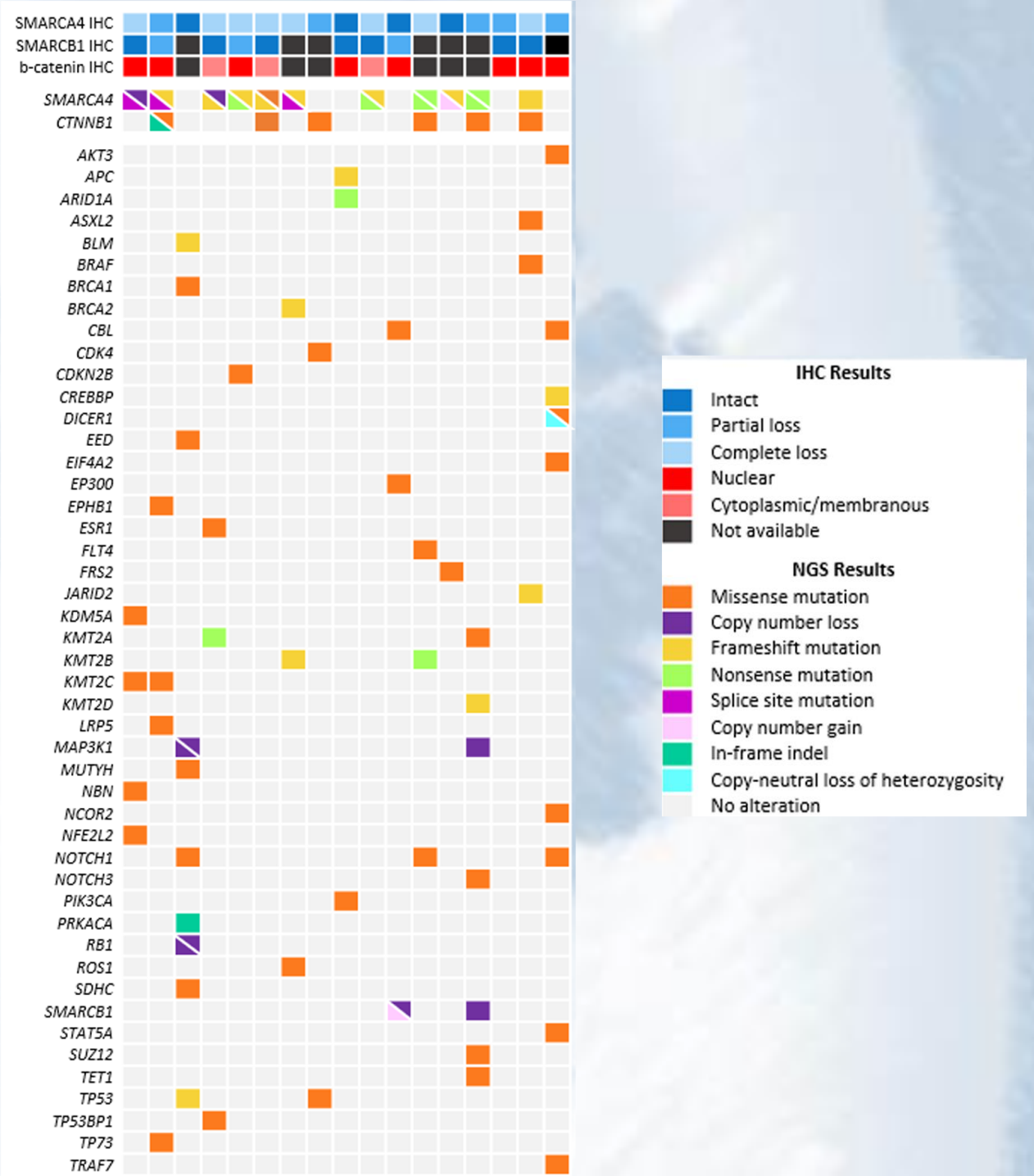

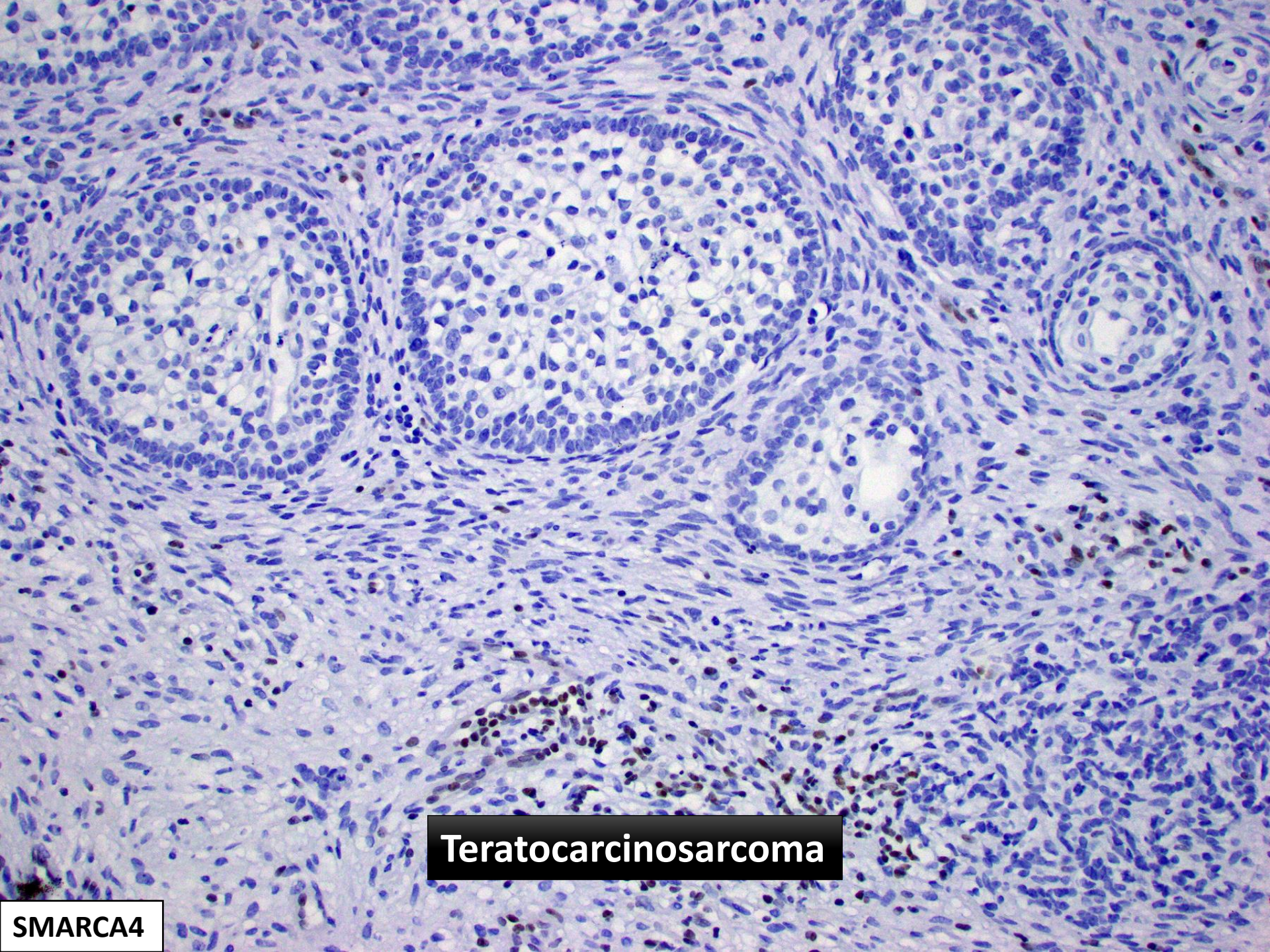
Teratocarcinosarcoma
SMARCA4

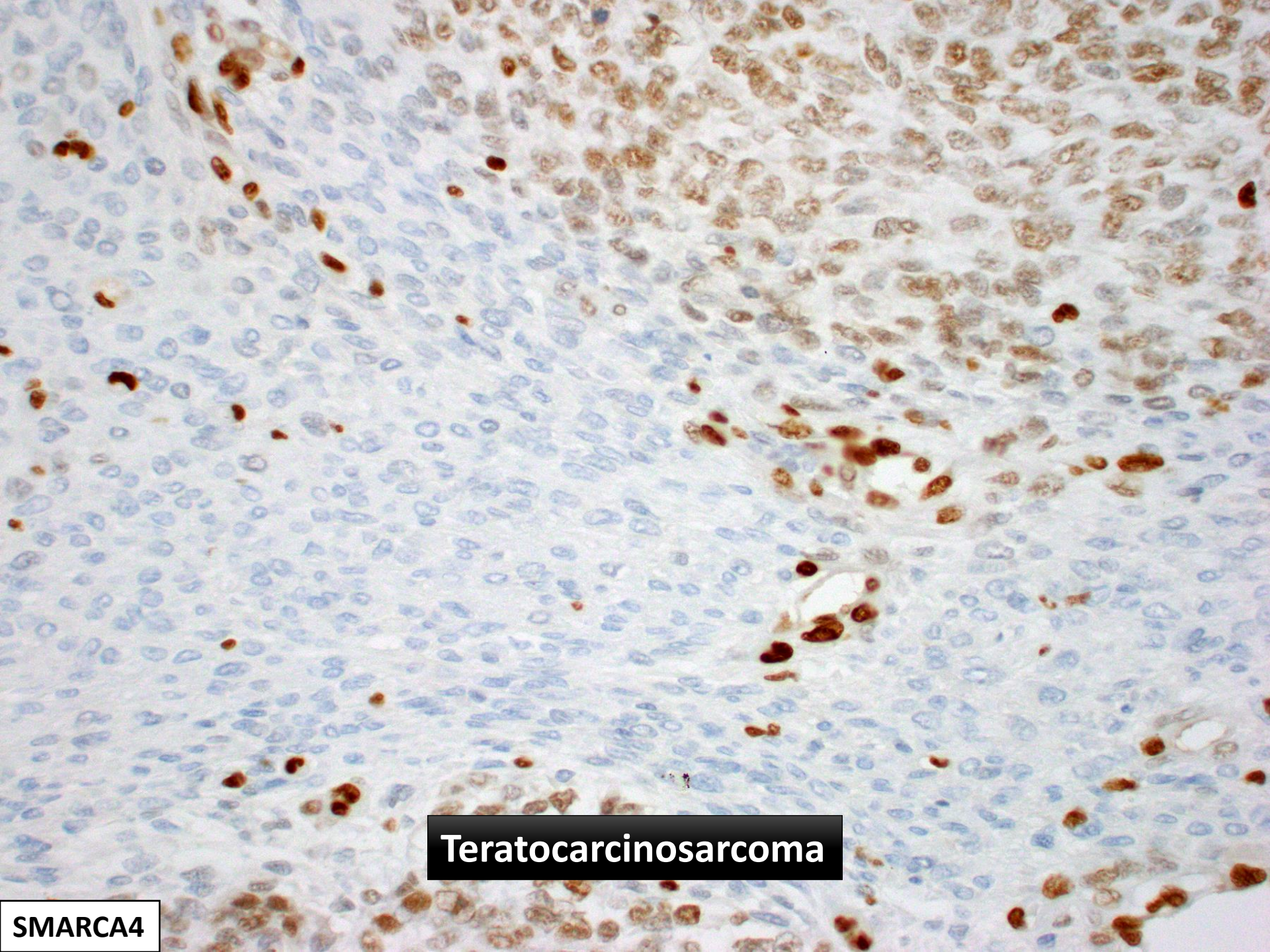
Teratocarcinosarcoma
SMARCA4

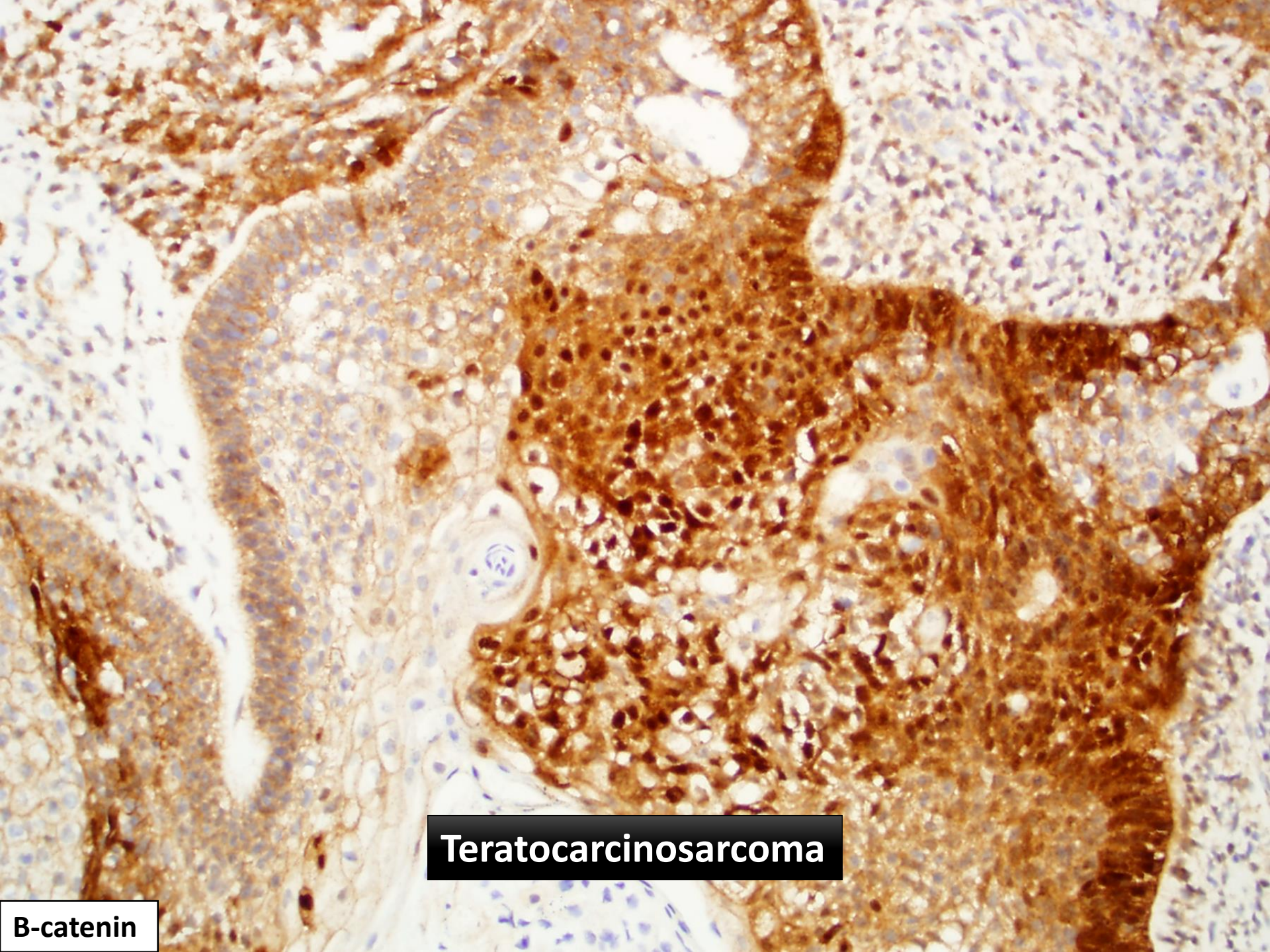
Teratocarcinosarcoma
B-catenin


SINONASAL
PATHOLOGY

SNUC

Lymphoepithelial CA

Neuroendocrine carcinoma

Adenocarcinoma

Teratocarcinosarcoma

Squamous Cell Carcinoma

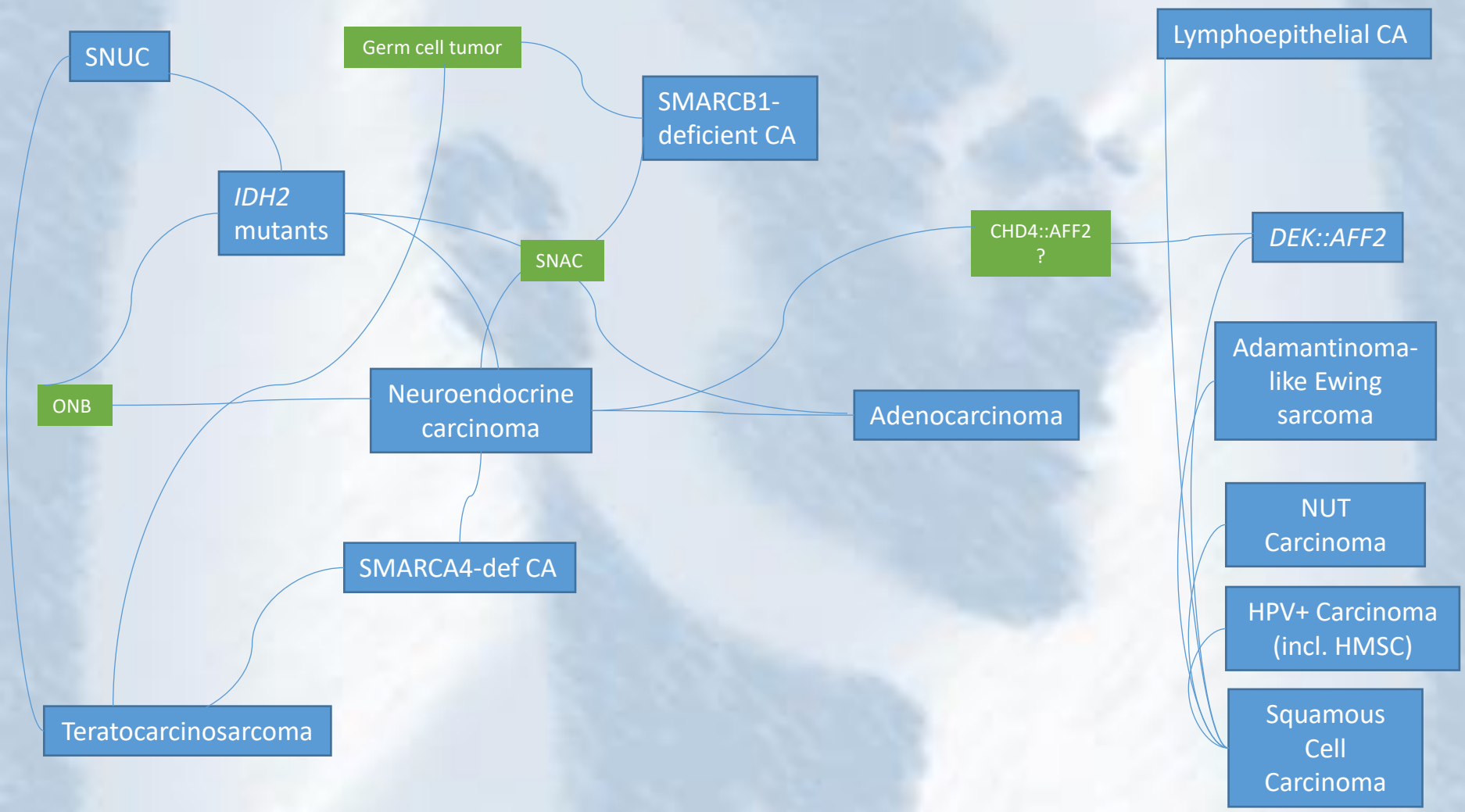
SNUC
Germ cell tumor
SMARCB1-deficient CA
Lymphoepithelial CA
IDH2 mutants
SNAC
CHD4::AFF2 ?
DEK::AFF2
ONB
Neuroendocrine carcinoma
Adenocarcinoma
Adamantinoma-like Ewing sarcoma
NUT Carcinoma
SMARCA4-def CA
HPV+ Carcinoma (incl. HMSC)
Squamous Cell Carcinoma
Teratocarcinosarcoma

Thank you!