INSTITUT BERGONIÉ
229 cours de l'Argonne
CS 61283 - 33076 Bordeaux cedex
www.bergonie.org
CENTRE RÉGIONAL DE LUTTE CONTRE LE CANCER DE BORDEAUX ET DU SUD-OUEST

UNICANCER
MEMBRE DU GROUPE

université de BORDEAUX

CARREFOUR PATHOLOGIE 2022
HISTOSEMINAIRE Pr C Guettier

CAS 5

François LE LOARER, MD, PhD

Université de Bordeaux & CLCC Bordeaux

Mail f.le-loarer@bordeaux.unicancer.fr

Déclaration d'intérêts

- Je déclare ne pas avoir de conflits d'intérêt

CAS 5

- Patient de 51 ans. Tumeur LID de 4cm
- Tabagique
- Pièce de résection

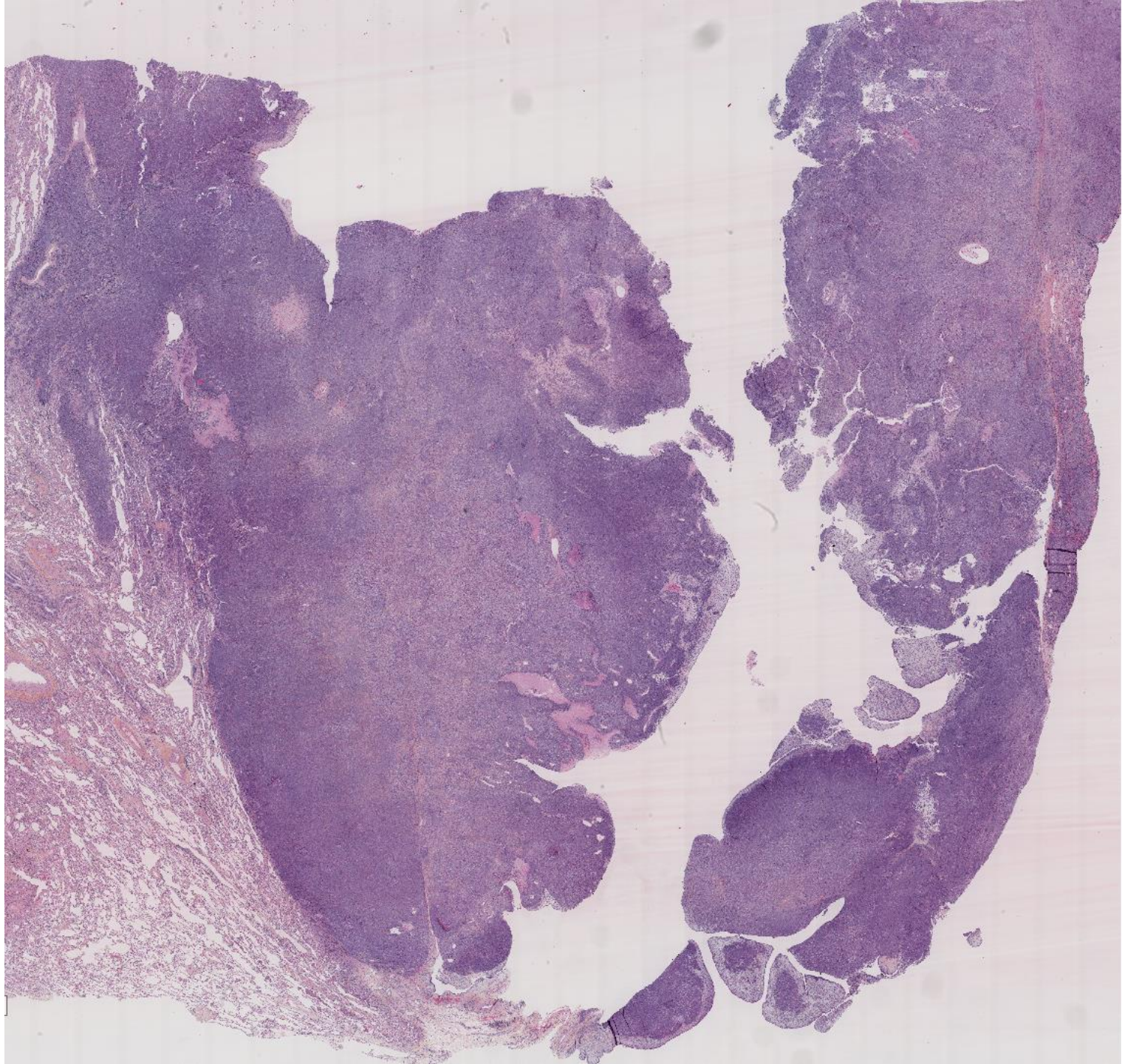

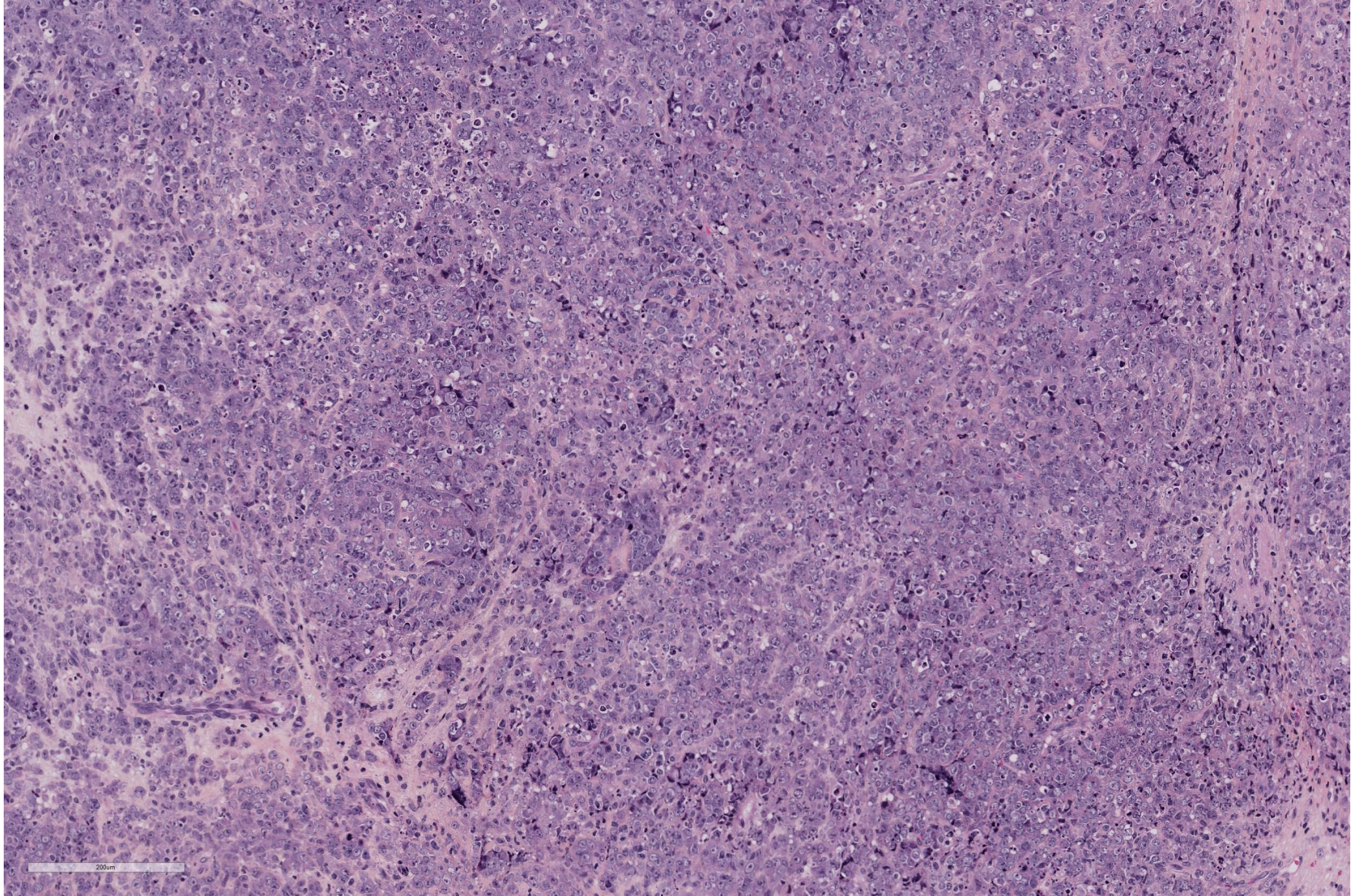
200um

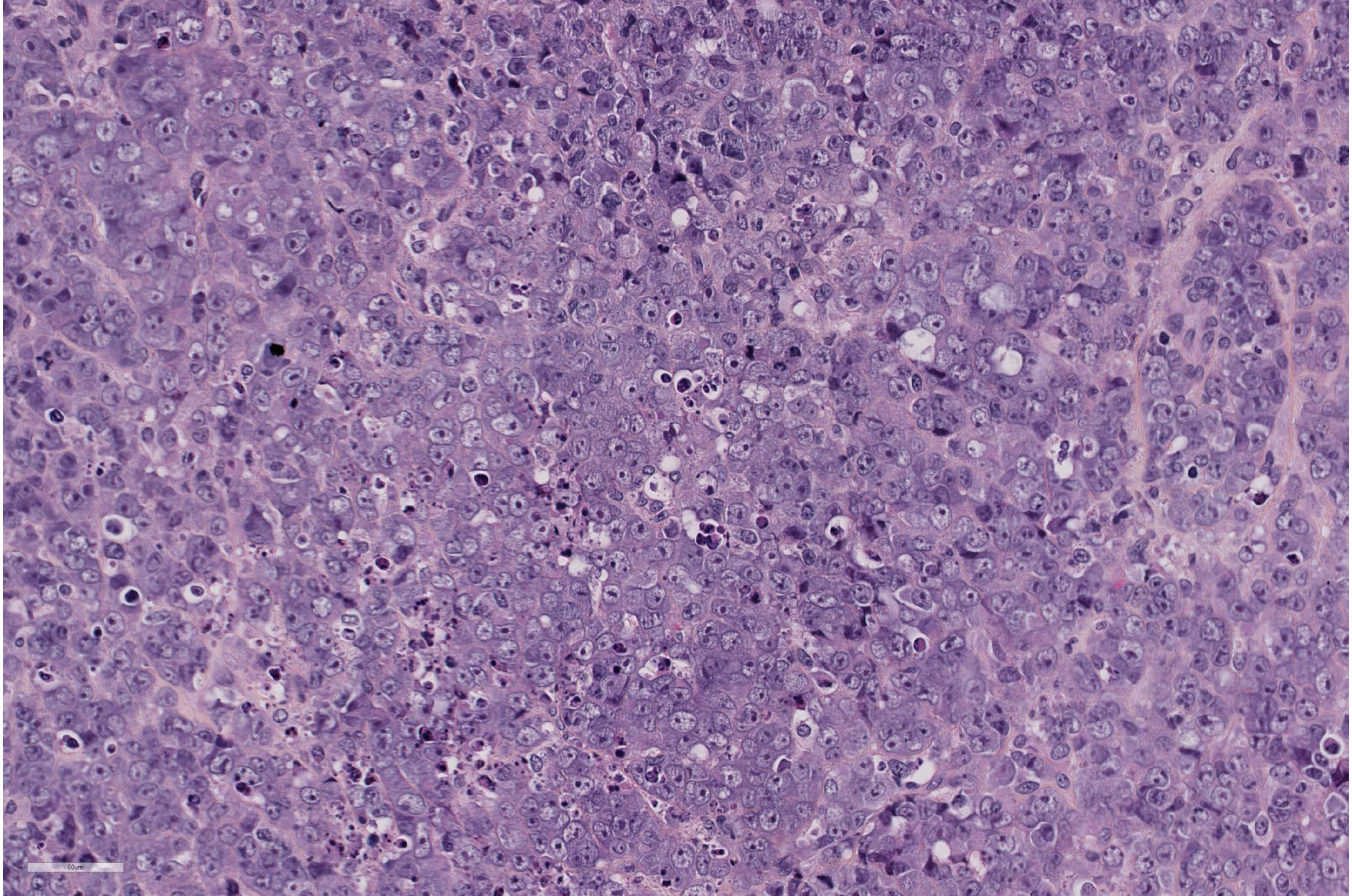
50um

QCM CAS CLINIQUE 5

- Quelles hypothèses morphologiques sont les plus probables?

A Carcinome NUT

B rhabdomyosarcome pléomorphe

C Tumeur maligne rhabdoide

D Carcinome indifférencié

E angiosarcome

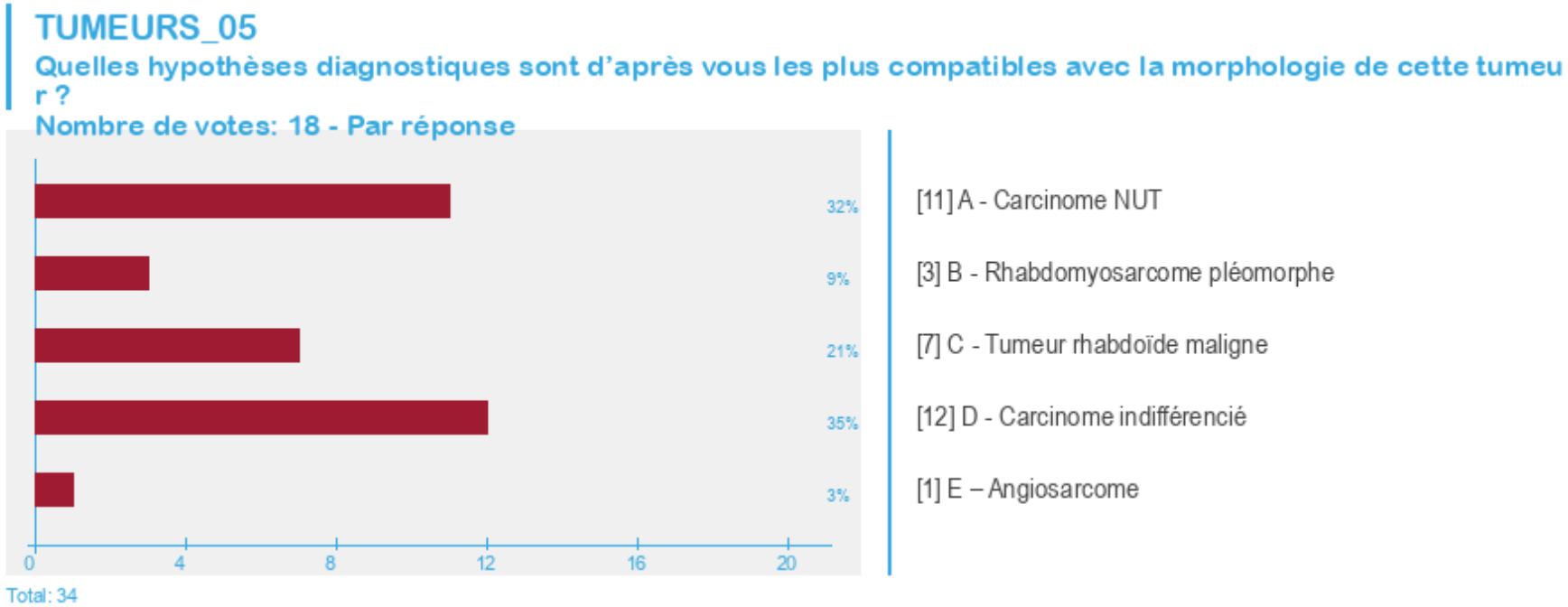

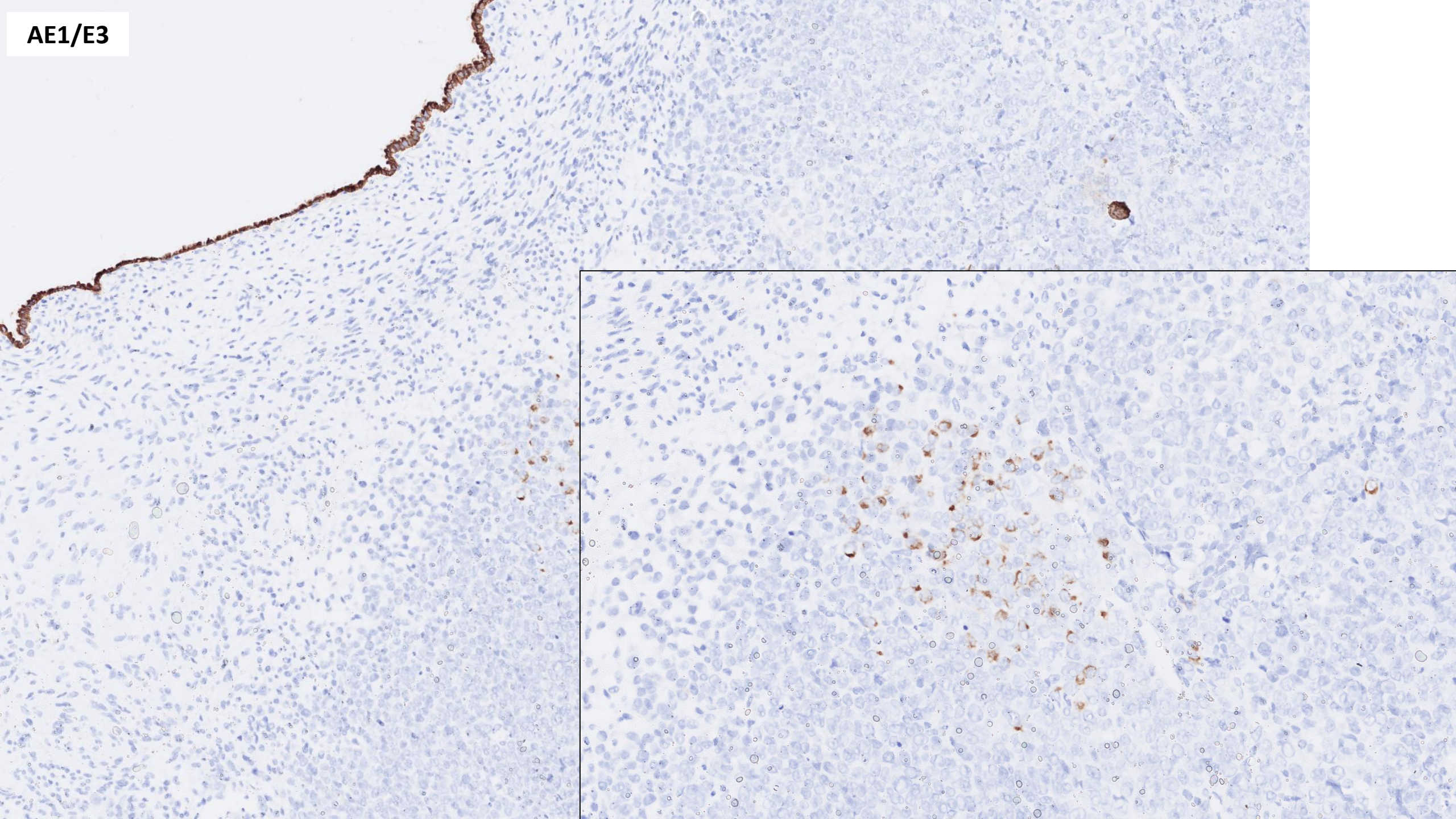
AE1/E3

EMA

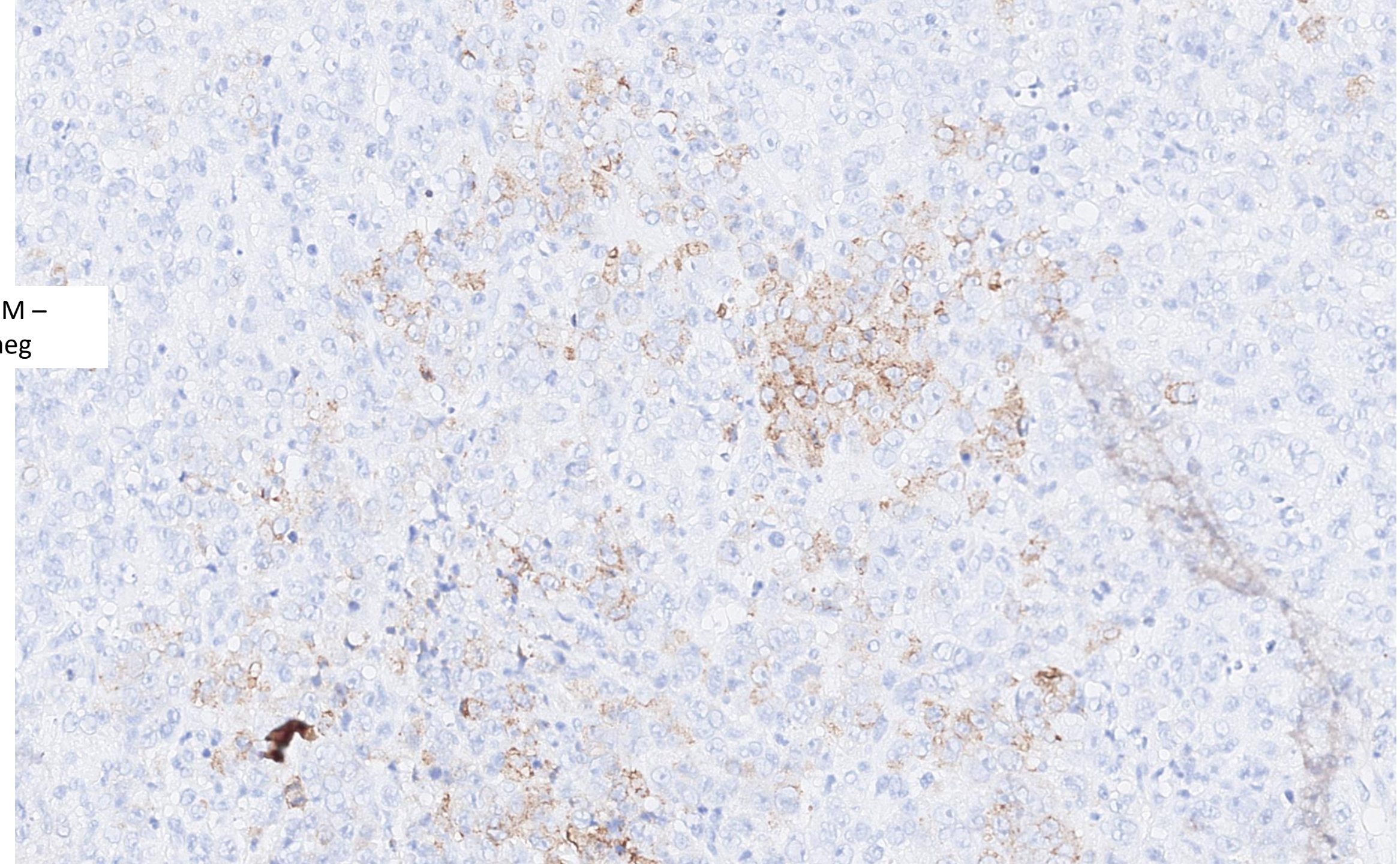

CK HPM –
NUT neg

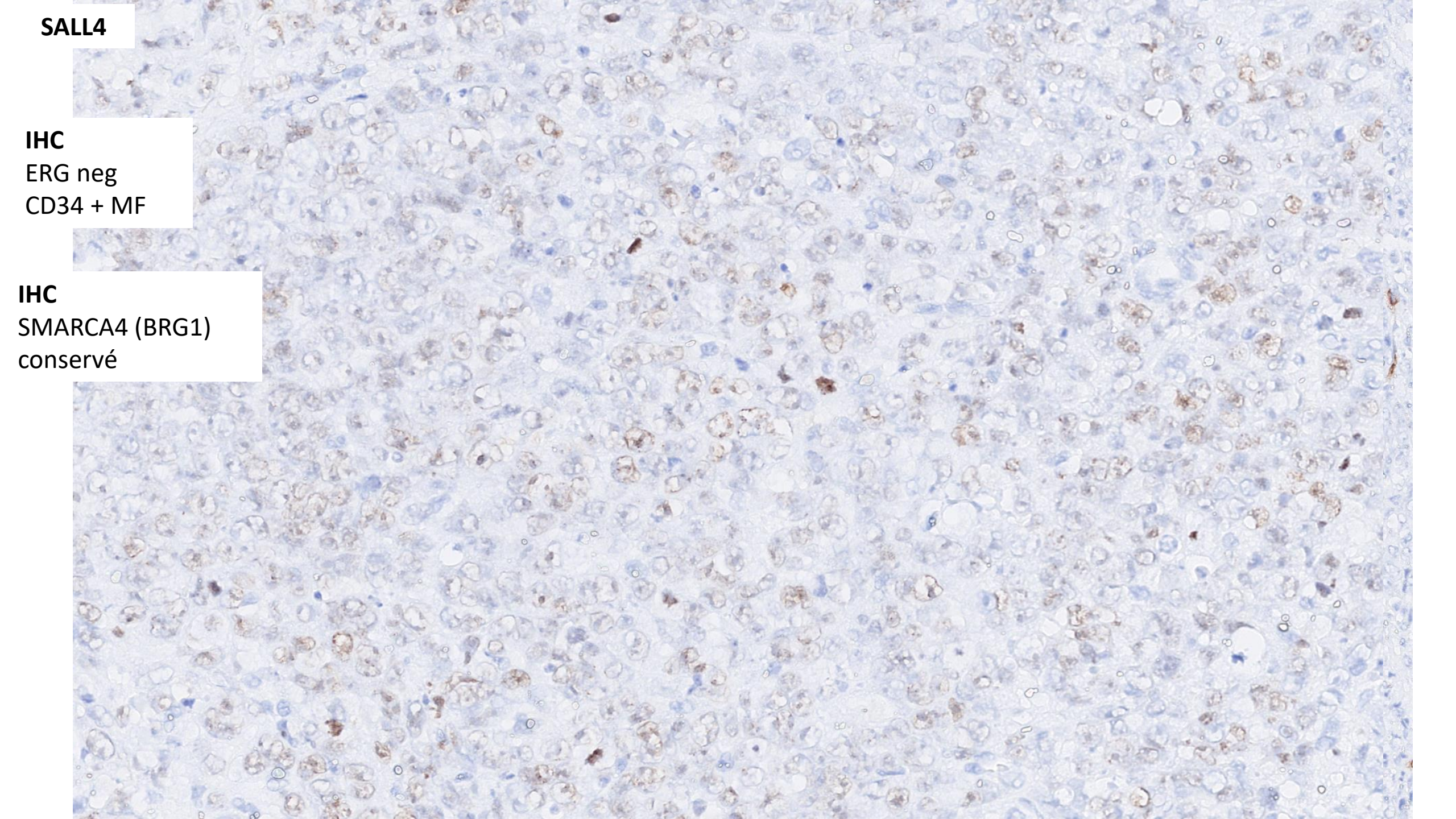
SALL4
IHC
ERG neg
CD34 + MF
IHC
SMARCA4 (BRG1)
conservé

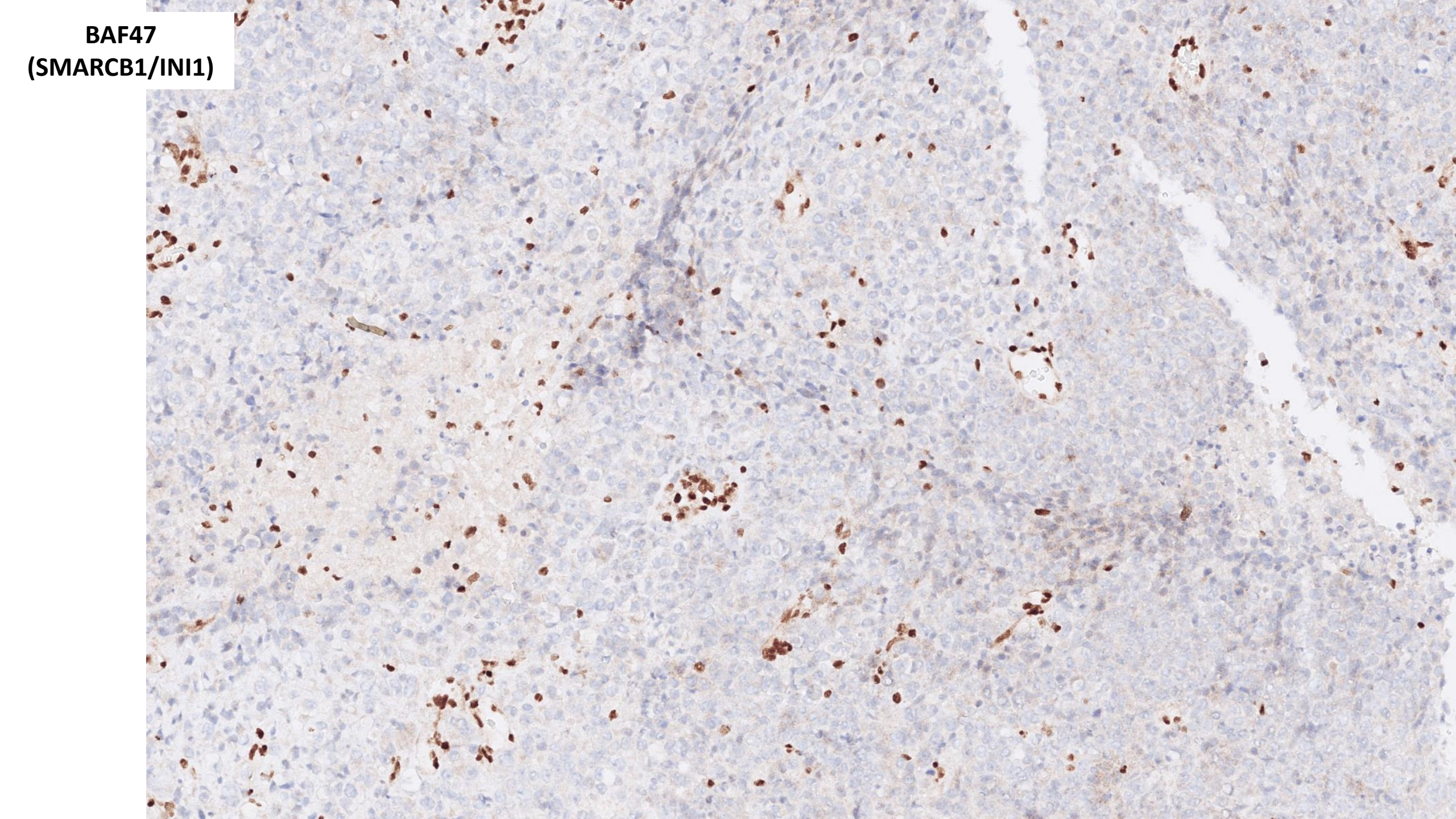
BAF47
(SMARCB1/INI1)

DIAGNOSTIC : TUMEUR MALIGNE SMARCB1-deficiente

Tumeur maligne rhabdoide
avec inactivation de SMARCB1

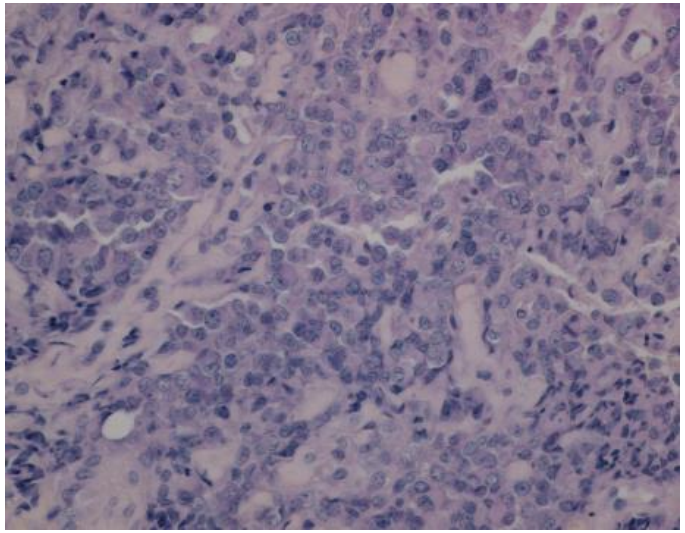

Carcinome myoépithélial avec
inactivation de SMARCB1?

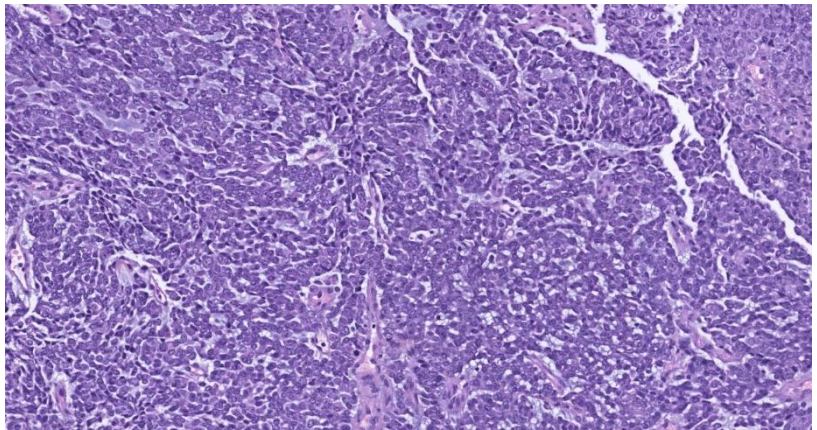

✓ localisation primitive viscérale

Sarcome épithélioide?

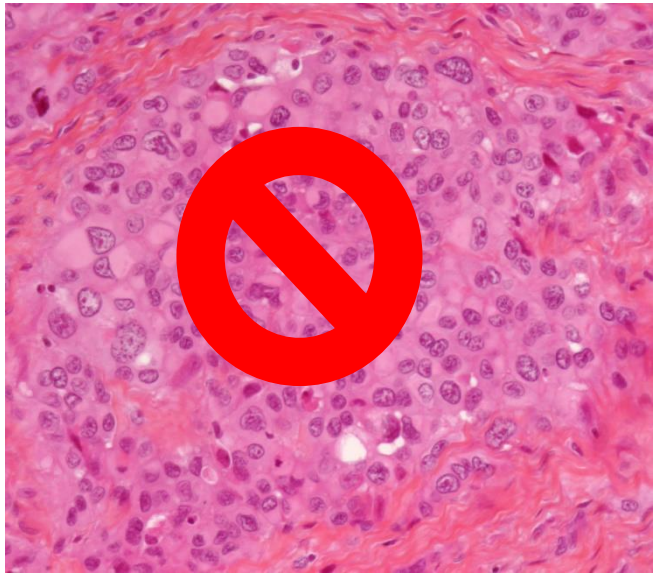

Carcinom me lla e du rein?

Synovialosarcome

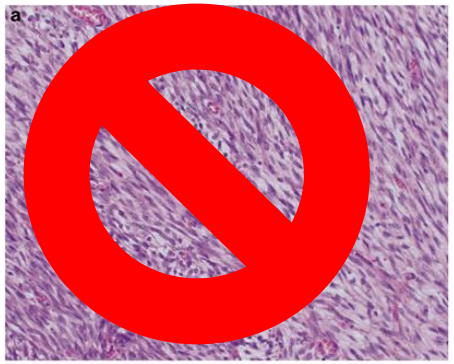

Carcinome dédifférencié/indifférencié?

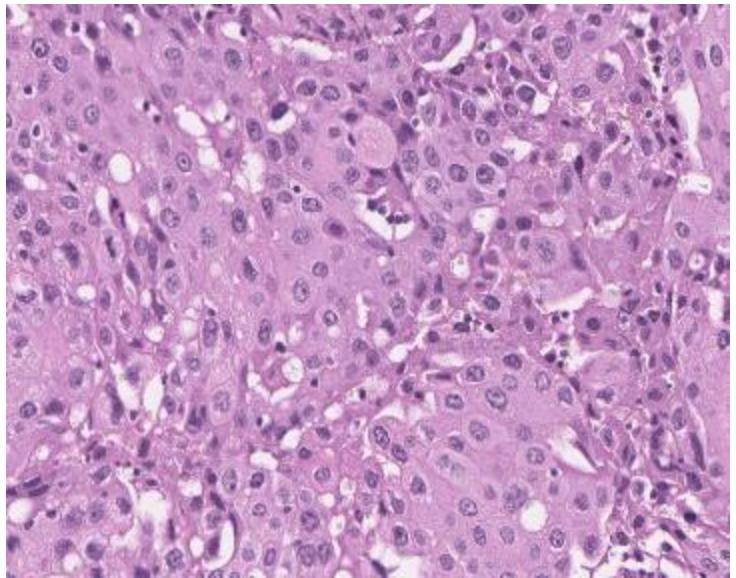

DIAGNOSTIC : TUMEUR MALIGNE SMARCB1-deficiente

✓ Age

- Patient de 11 ~~51~~ ans. Tumeur LID de 4cm

Tumeur maligne rhabdoide avec inactivation de SMARCB1

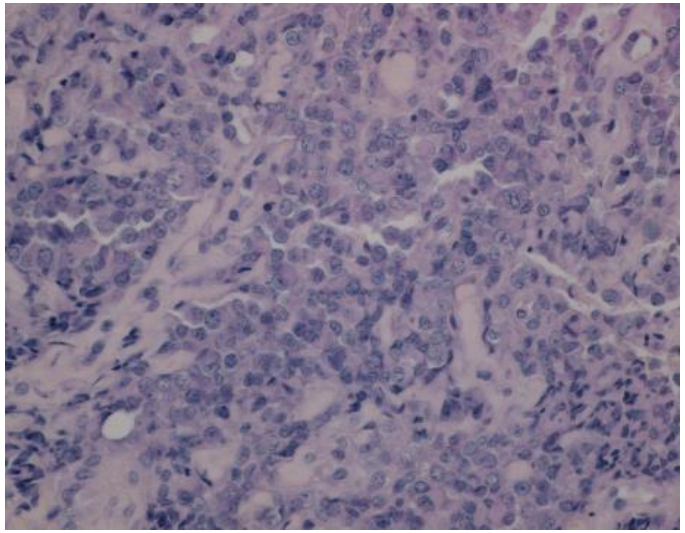

Carcinome myoépithélial avec inactivation de SMARCB1?

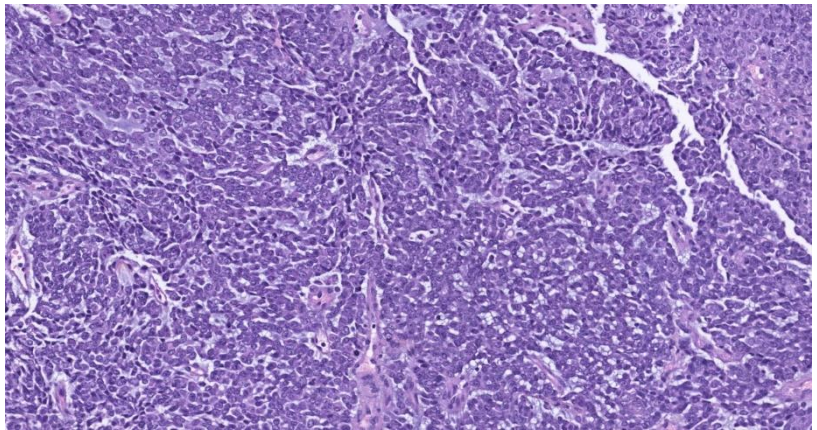

Sarcome épithélioide?

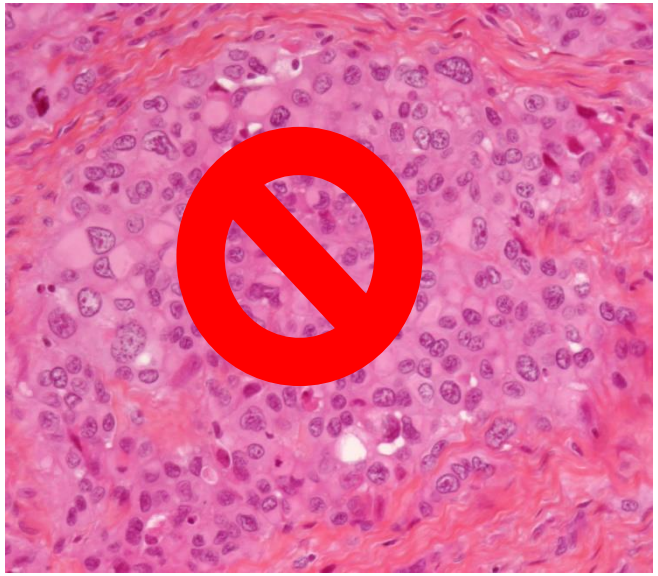

Carcinome [illegible] du rein?

Synovialosarcome

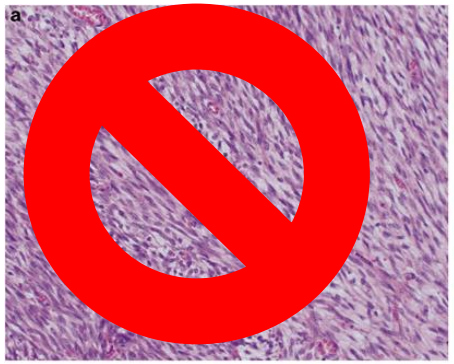

Carcinome dédifférencié/indifférencié?

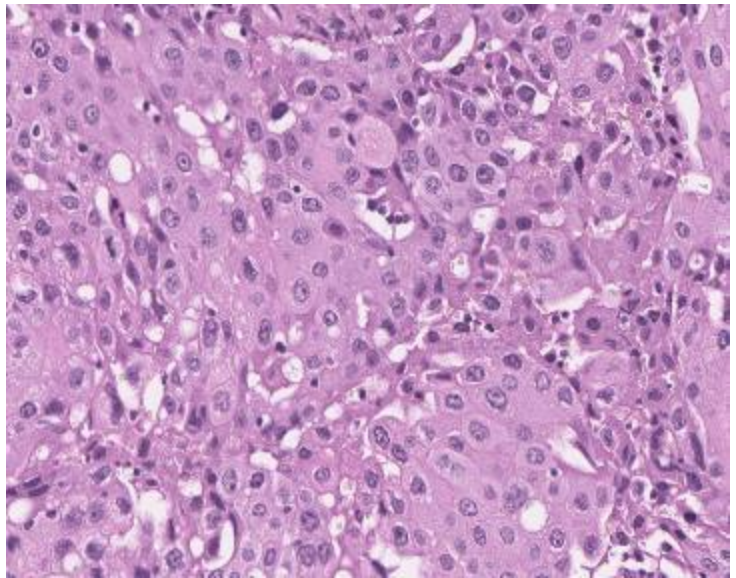

TUMEUR MALIGNE RHABDOIDE

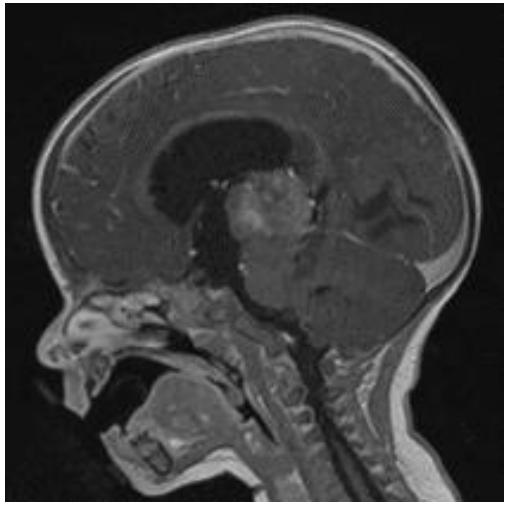

- SNC (AT/RT)
- Rein (RTK)
- Tissus mous (MRT)

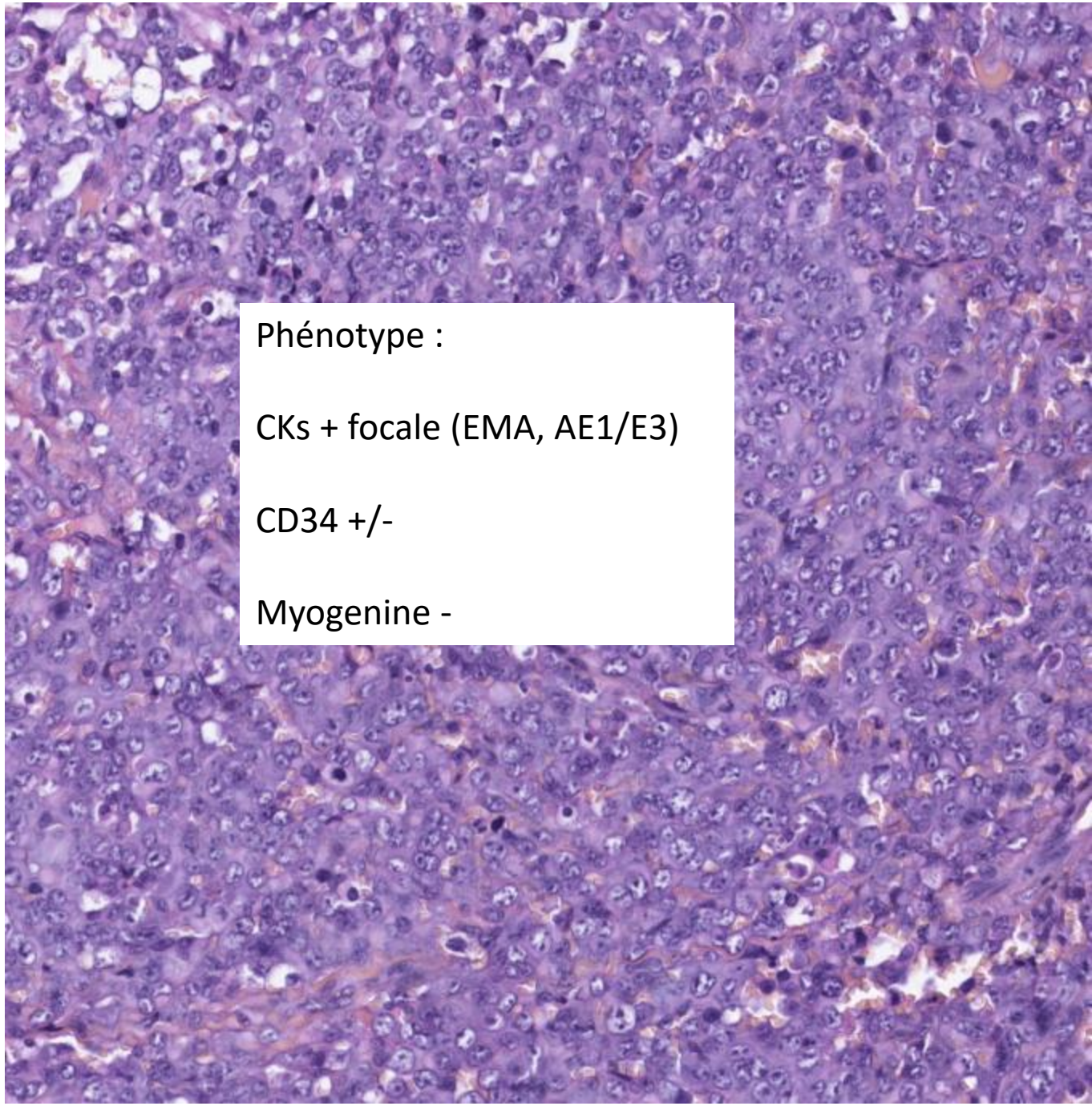

In Hasselblatt M et al, AJSP 2011.

PHENOTYPE RHABDOIDE

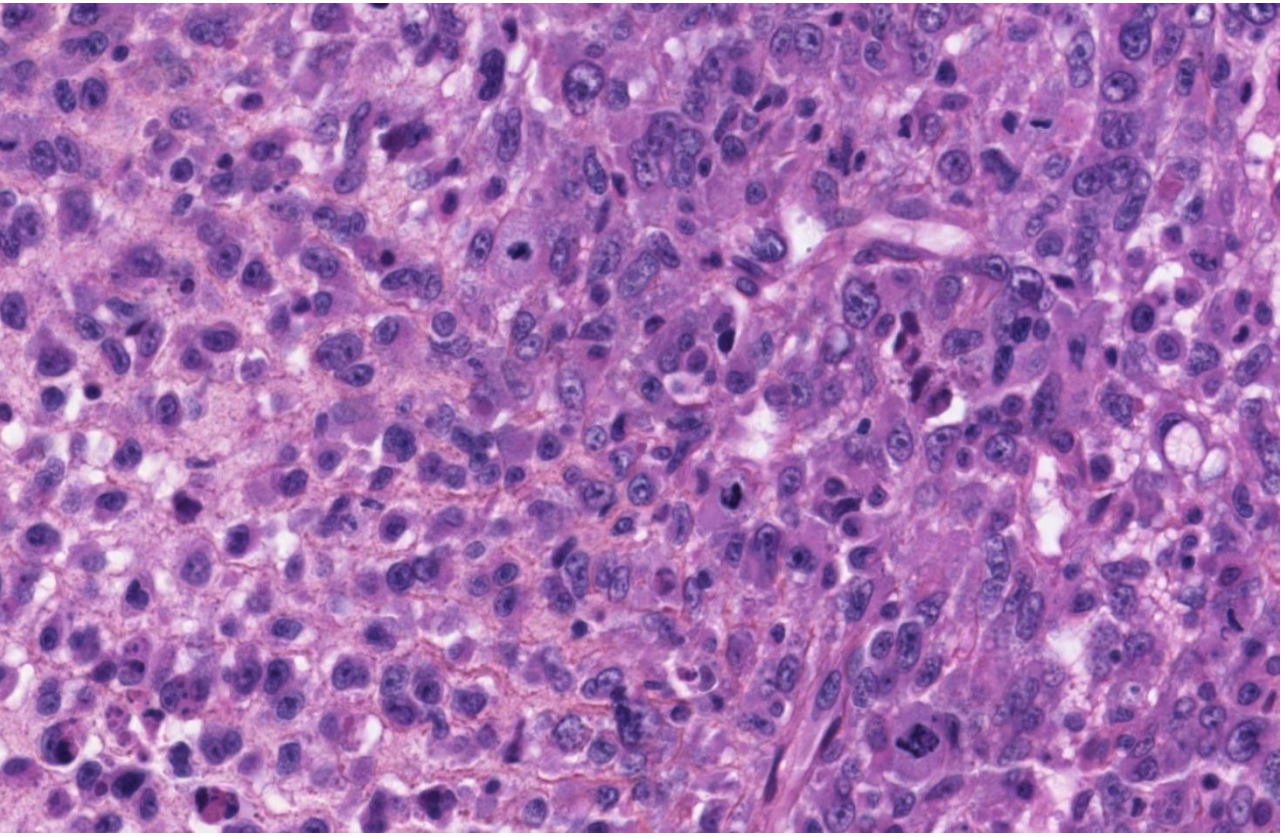

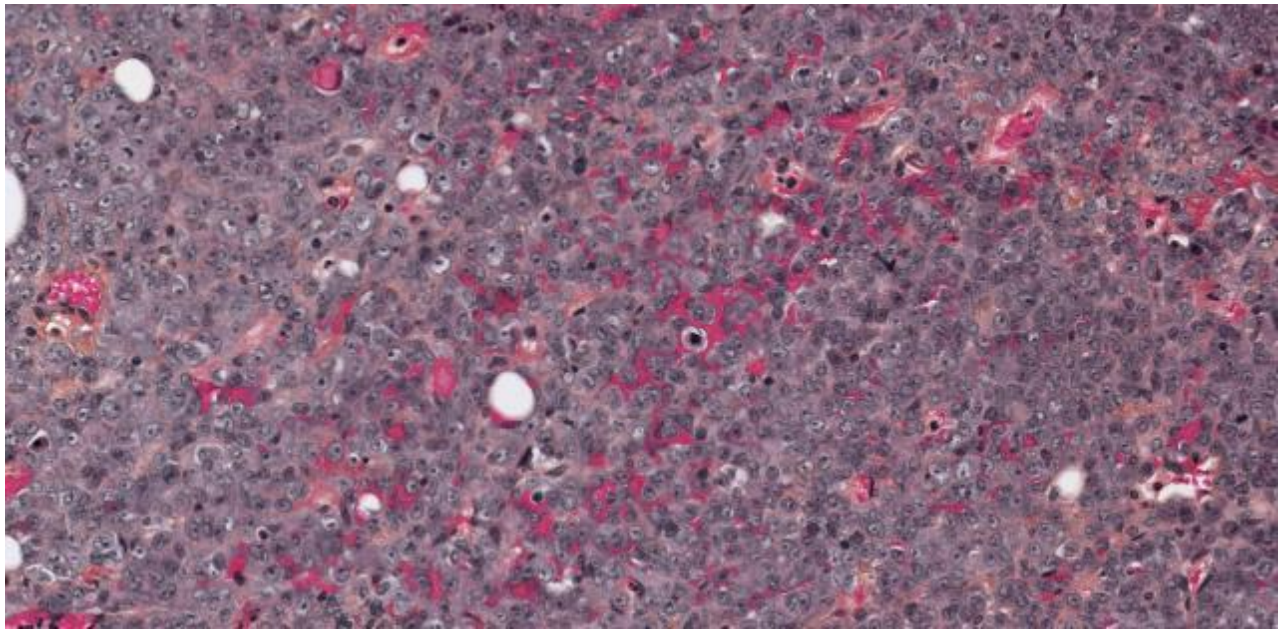

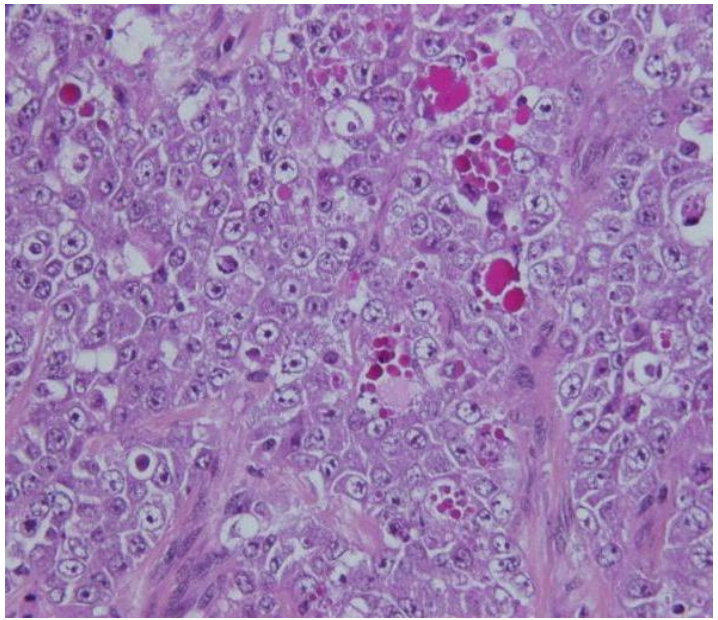

TUMEURS MALIGNES RHABDOIDES

INI1=SMARCB1= BAF47
Mutation frameshift

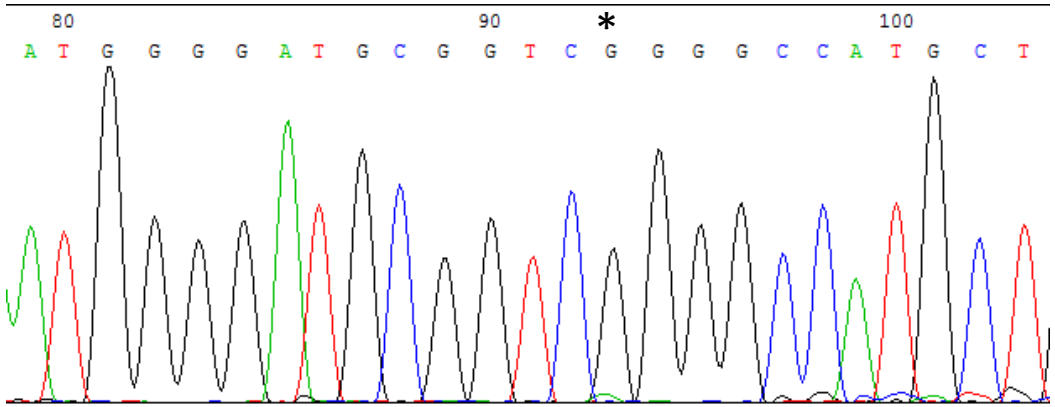

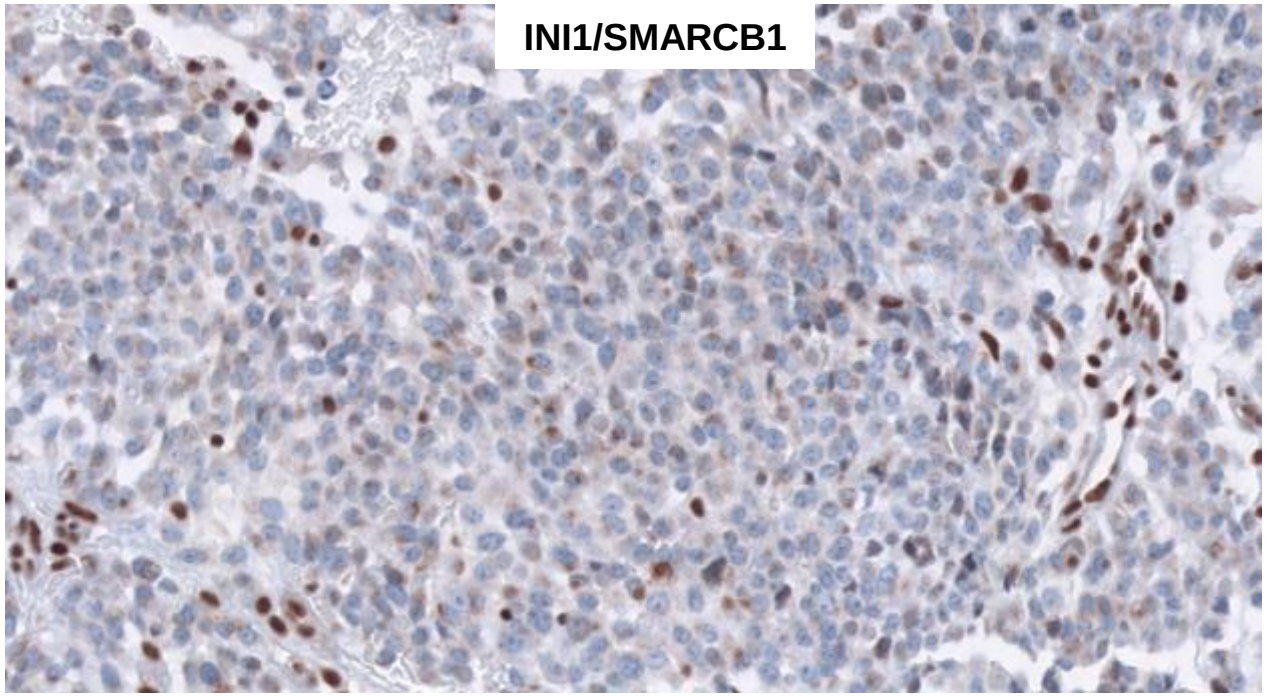

In Versteege I et al, Nature, 1998.

PLASTICITE PHENOTYPIQUE

MRT PSEUDO-TUMEUR GERMINALE!!!!

- ✓ Vulve
- ✓ ORL/ sinonasal

- ✓ Patients + âgés et sites extra-gonadiques

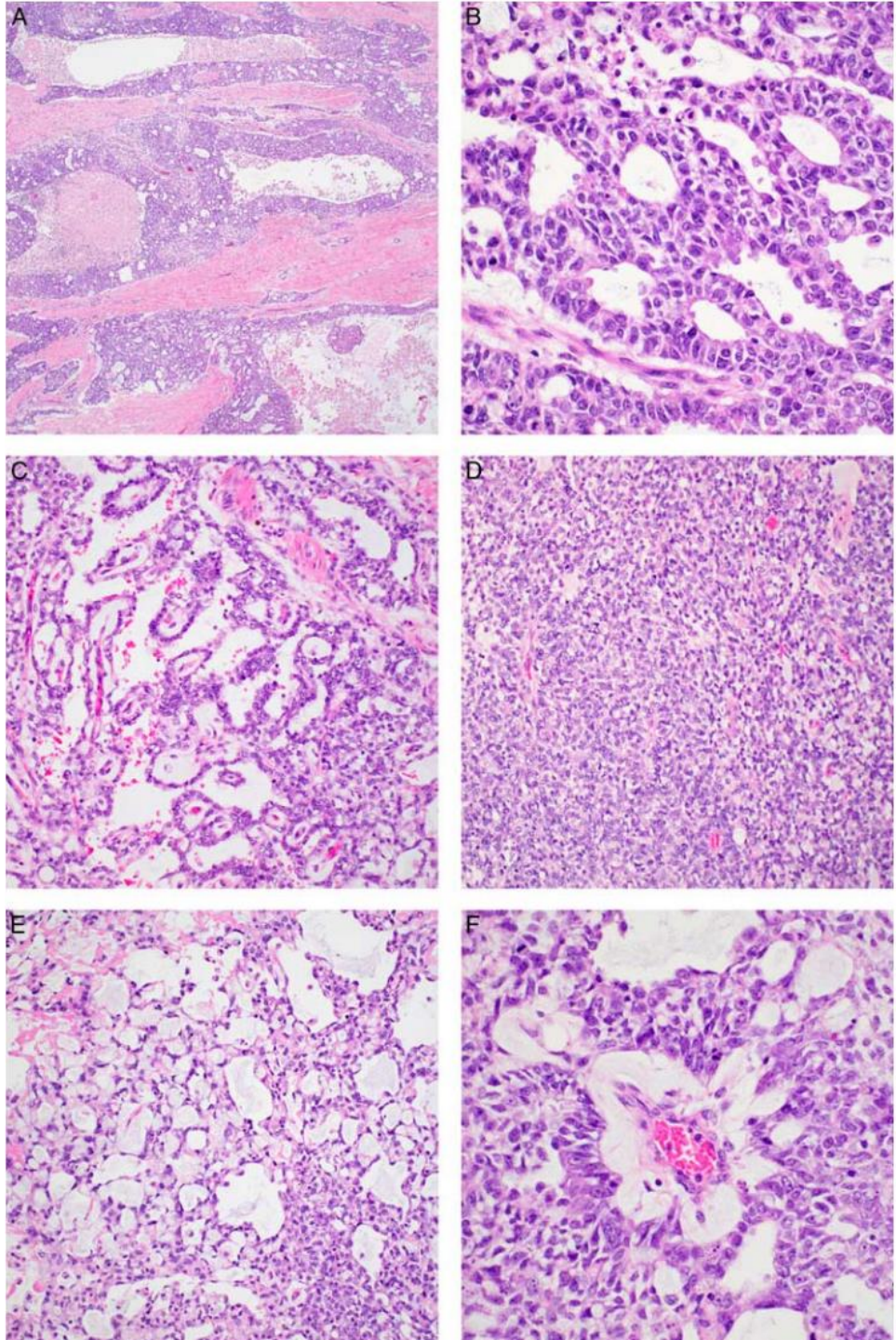

In Kolin DL et al, AJSP, 2022.

MRT PSEUDO-TUMEUR GERMINALE!!!!

- ✓ Phénotype IHC germinal!!
- ✓ Tumeur rhabdoide pseudo Yolk sac

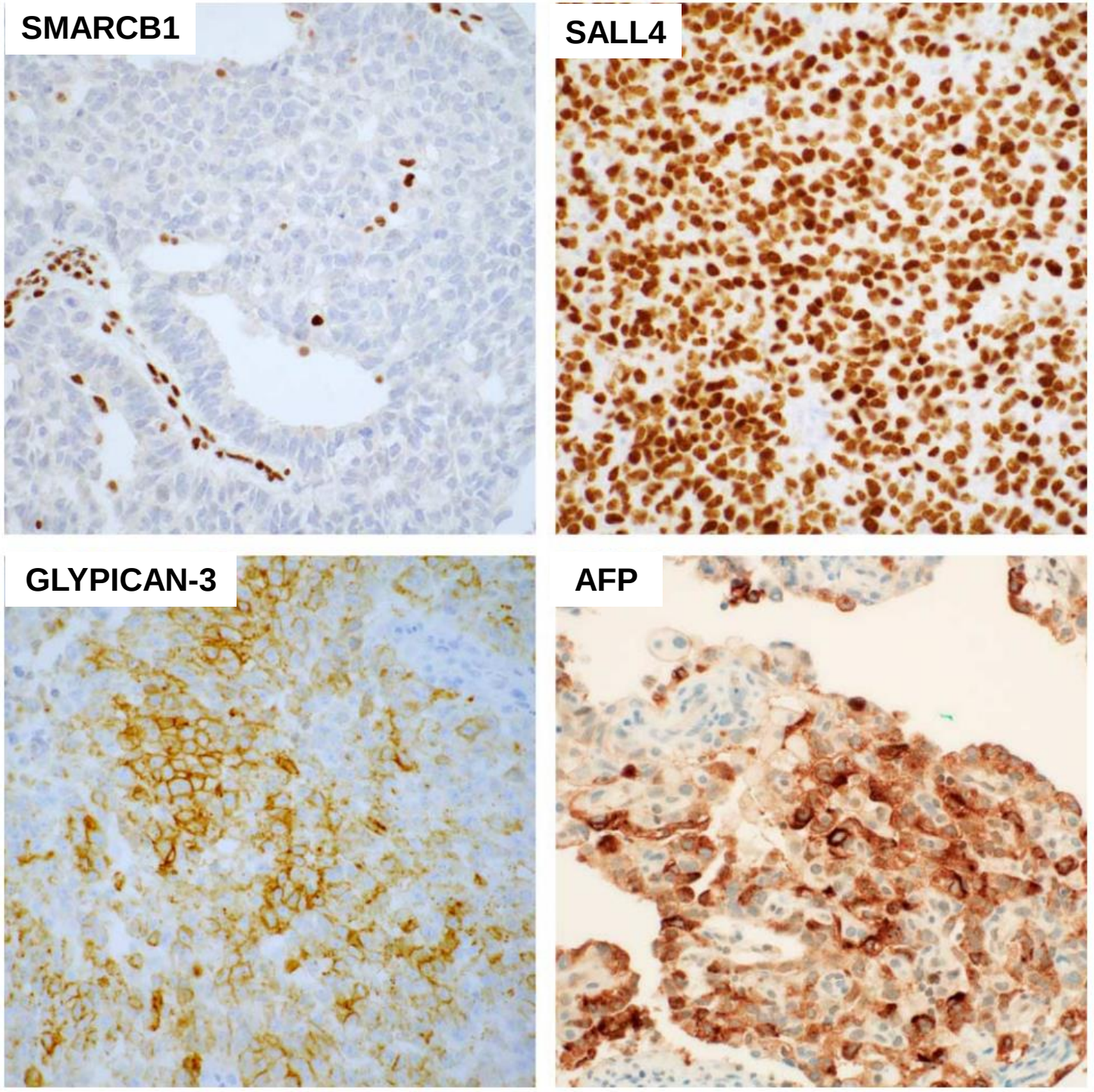

In Kolin DL et al, AJSP, 2022.

ASPECTS GENETIQUES DES MRT

1. Mutation rate: 0,19 mutation/Mb

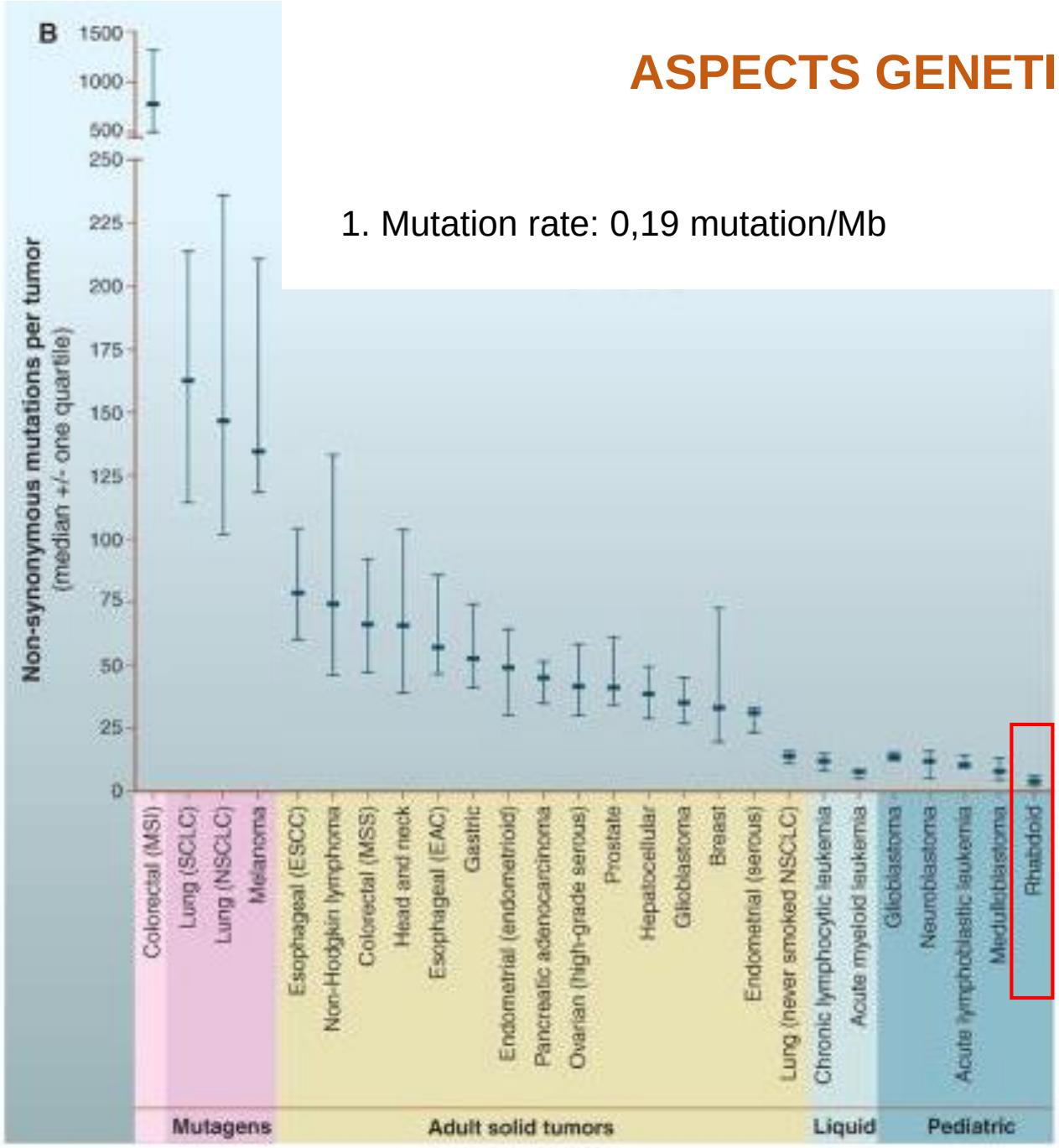

2. Profil génétique simple diploide

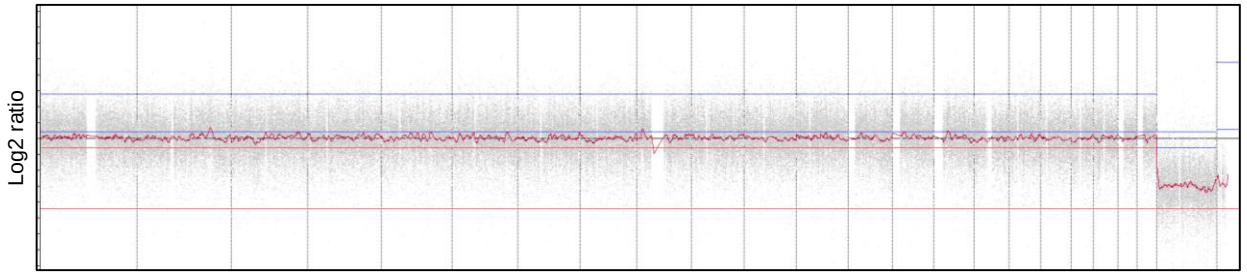

in Vogelstein B et al, Science, 2013.
Lee R et al, JCI, 2012.

ASPECTS GENETIQUES DES MRT

3. Mutation constitutionnelle

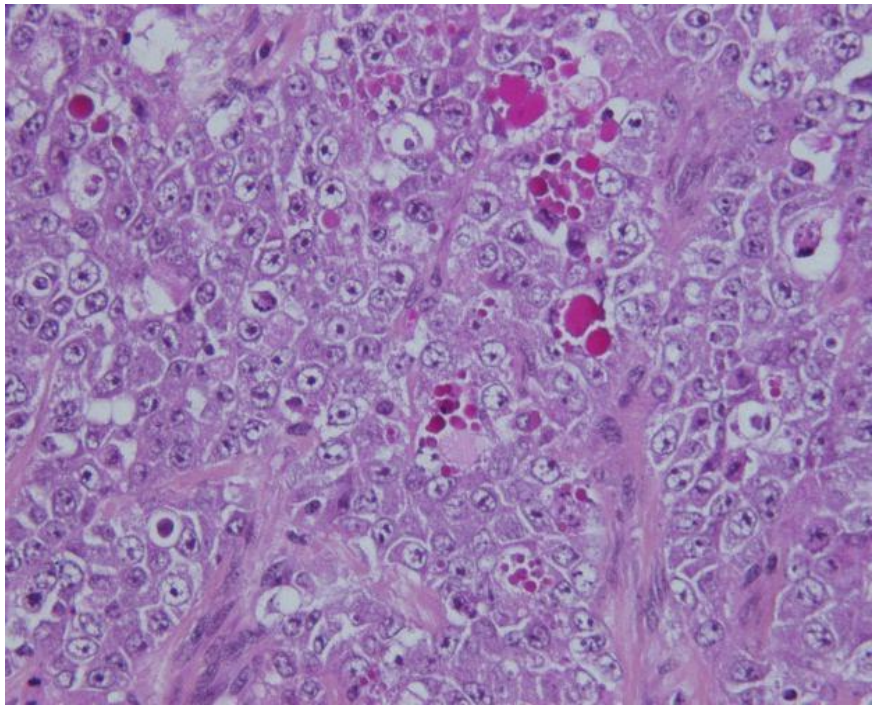

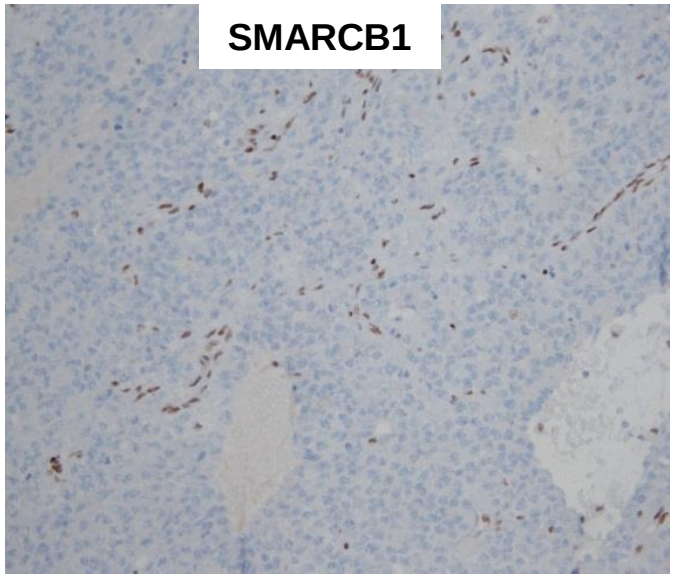

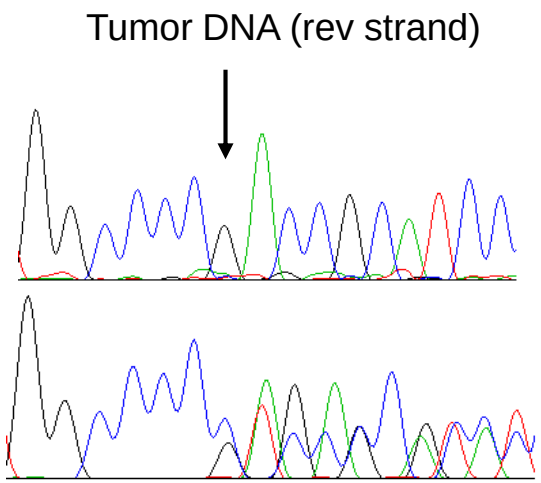

exon3:c.300_301delAG

VARIANT TUMEUR RHABDOIDE SMARCA4-DEFICIENTE (BRG1)

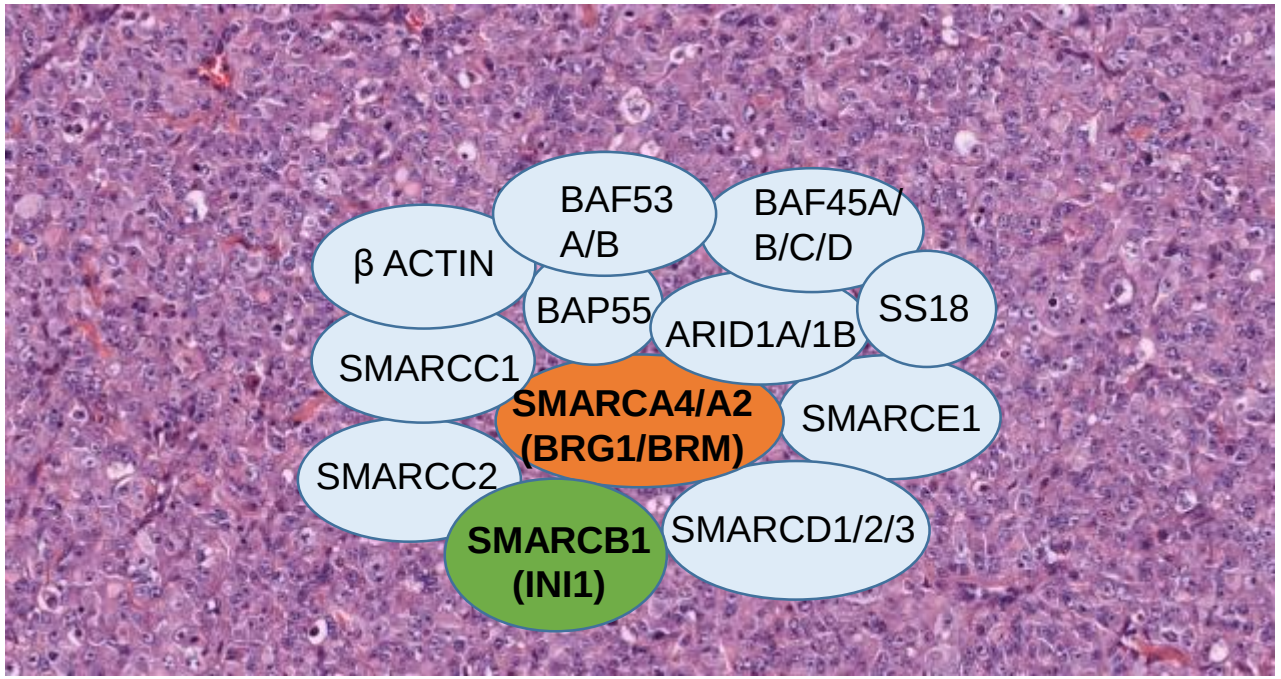

SMARCA4= BRG1

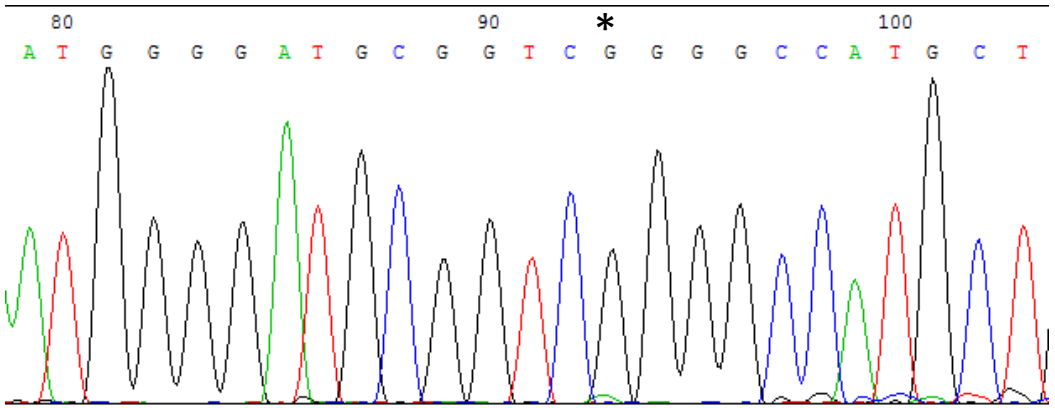

SMARCA4 Exon4:c.A298del: pS100fs

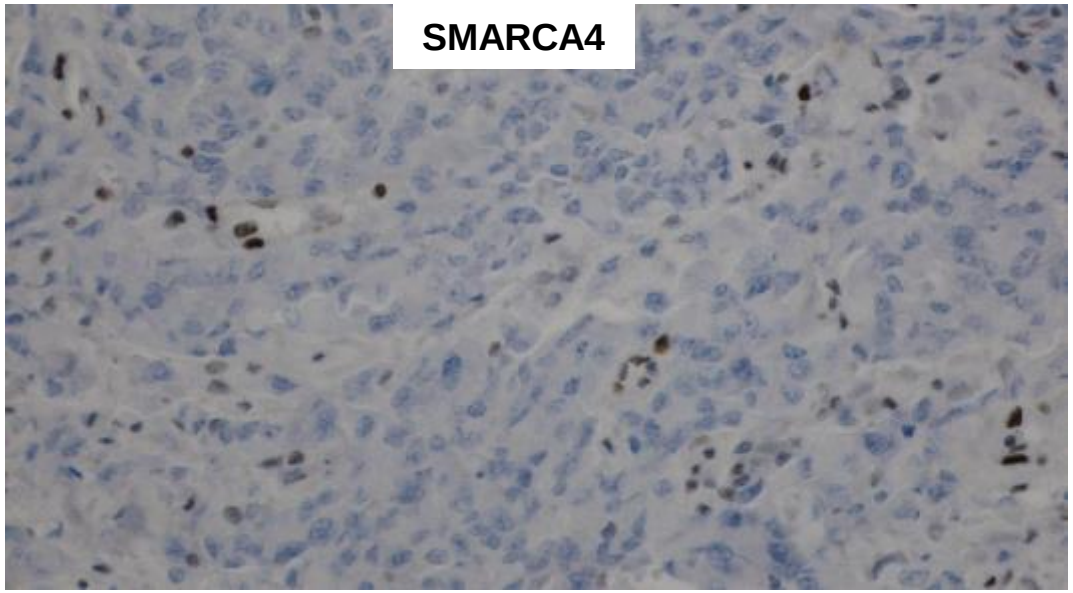

In Hasselblatt M et al, AJSP 2011 & Acta Neuropath, 2015.

TUMEURS MALIGNES RHABDOIDES ADULTES

13 cas « MRT » adulte

- 5 classés MRT-like
- 8 classés

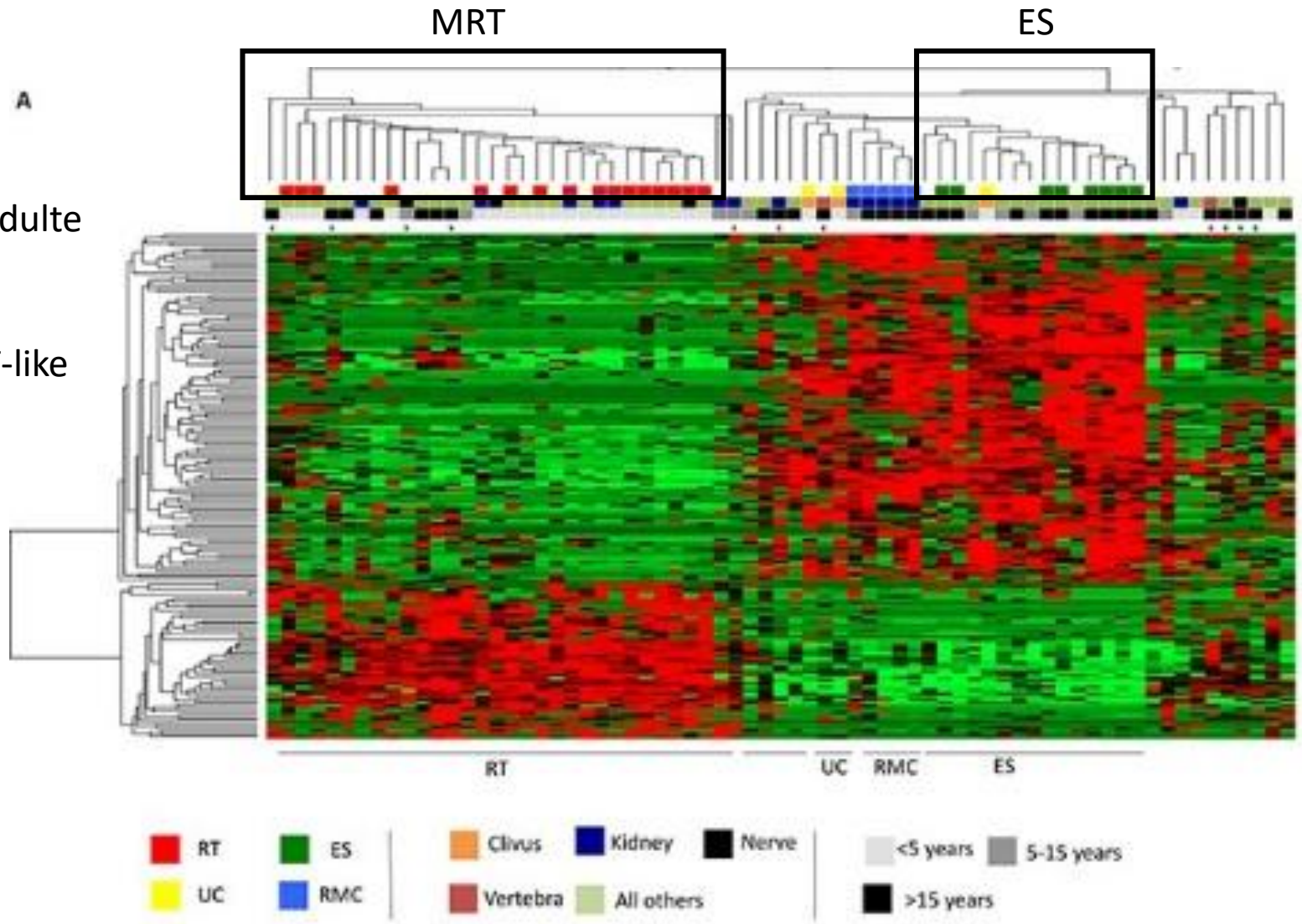

Sur le plan génétique

in Richer W et al, Oncotarget, 2016.

TUMEURS MALIGNES RHABDOIDES ADULTES

Sur le plan génétique

TUMEURS INCLASSEES ADULTES

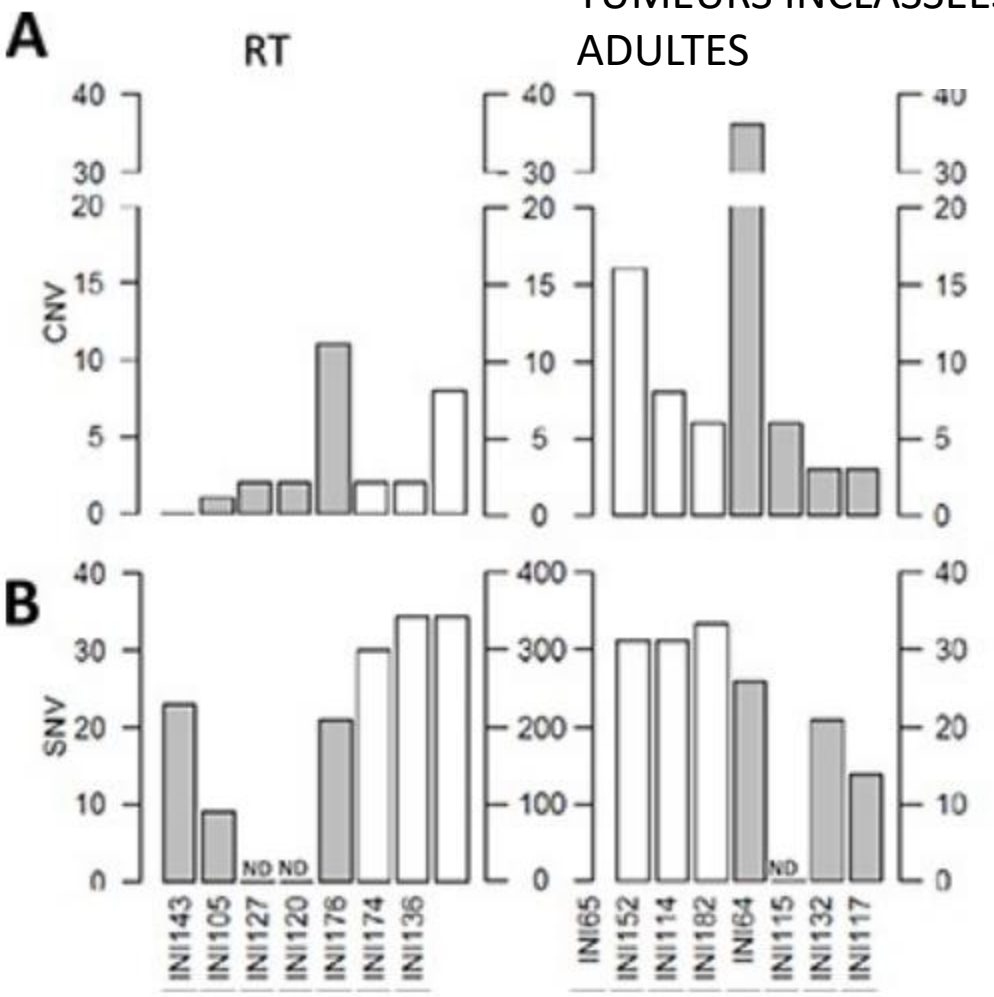

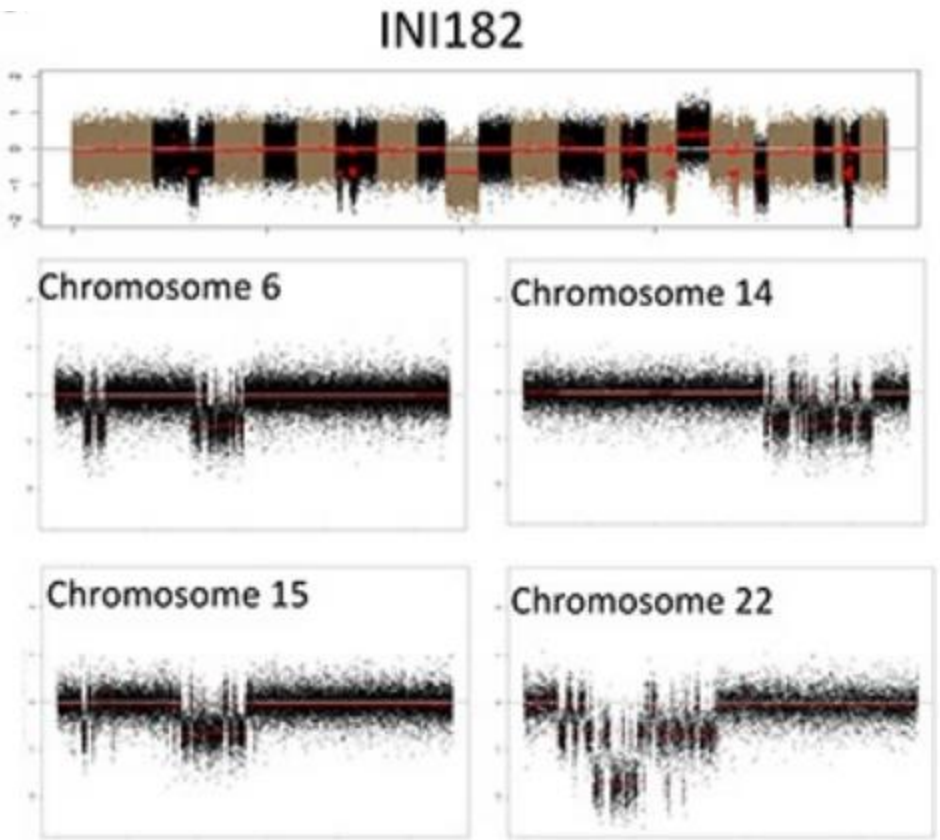

in Richer W et al, Oncotarget, 2016.

MRT AVEC CONTEXTE GENETIQUE DIFFERENT…

MRT dans contexte de **syndrôme de LI Fraumeni** !

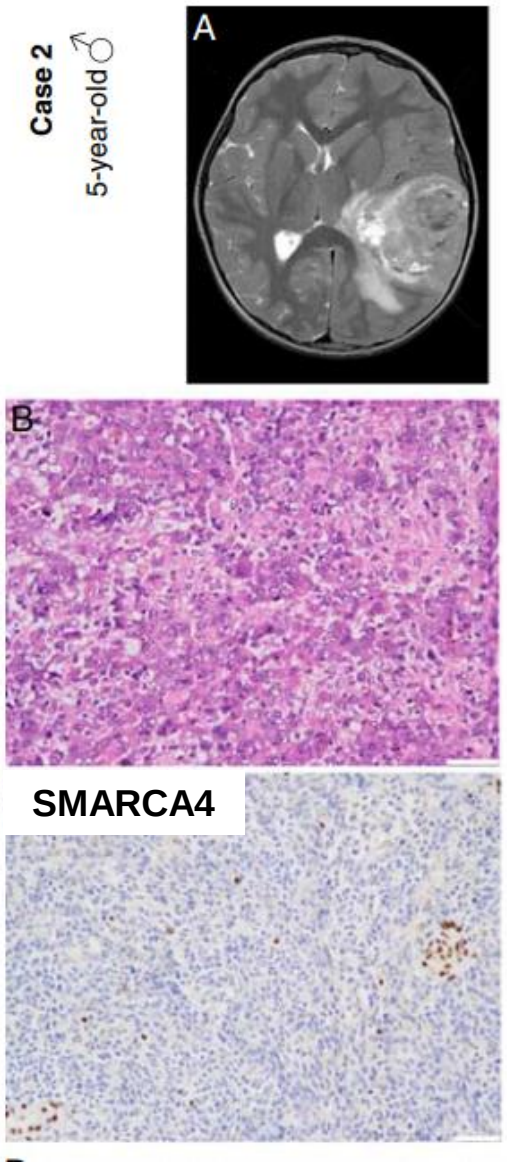

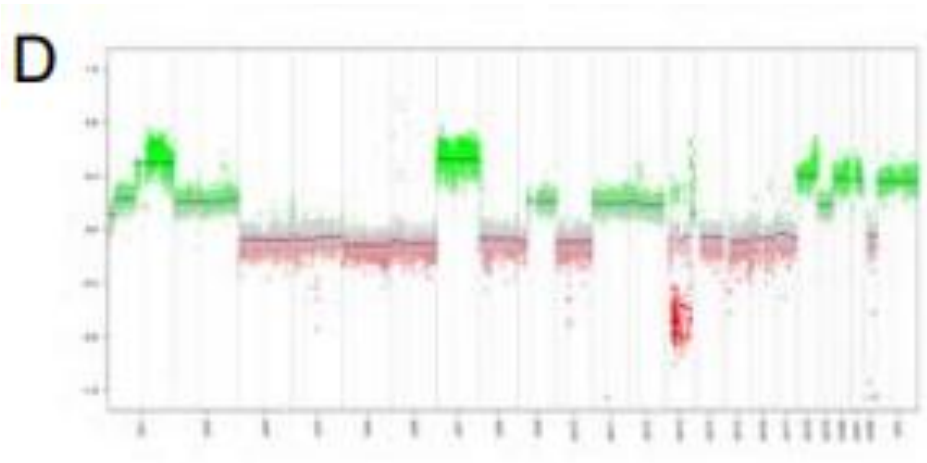

Profil génomique complexe!

Methylome profile

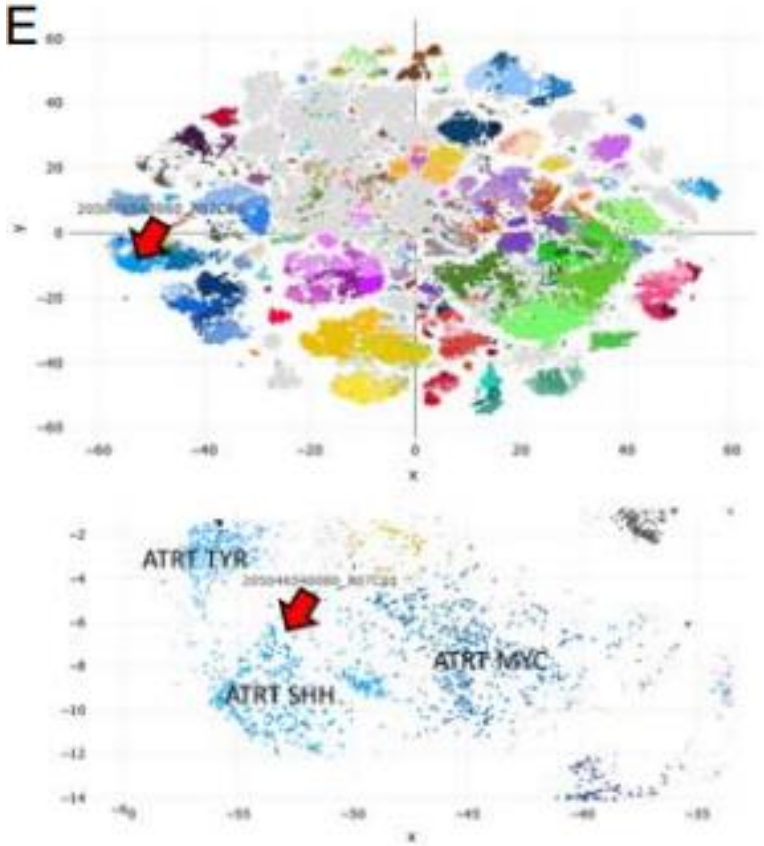

Methylome: ATRT class !
(pas tous classés …)

in Hasselblatt M et al. AJSP 46(9) 2022

NOTRE CAS : TUMEUR MALIGNE SMARCB1-deficiente

- Patient de 51 ans. Tumeur LID de 4 cm
- Tabagique

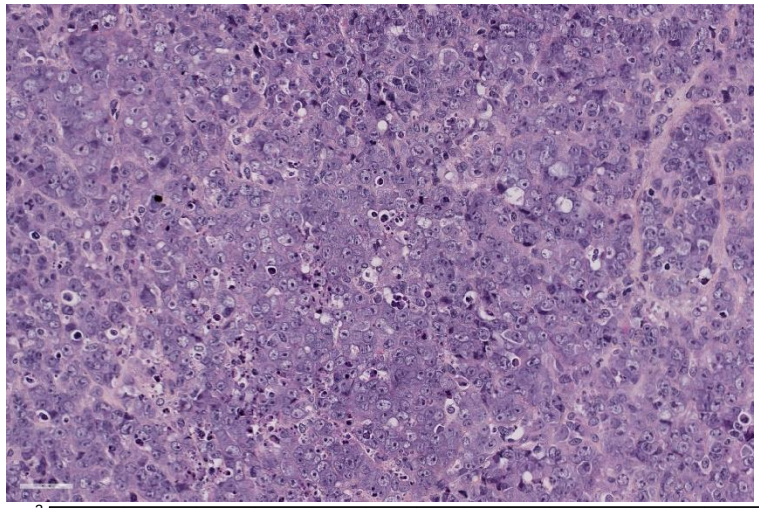

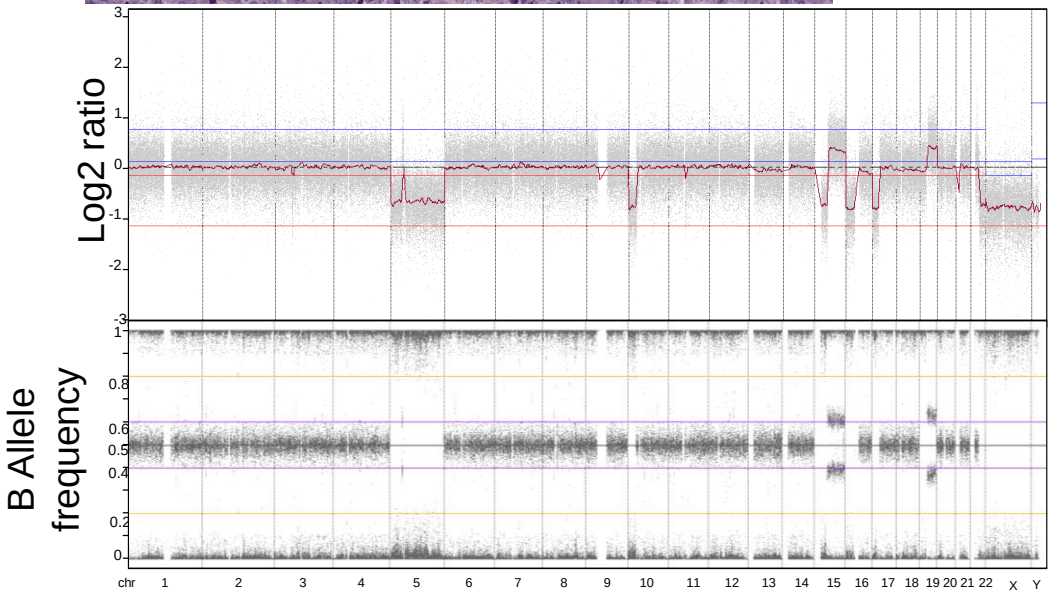

1. Profil génétique diploide avec quelques CNA
2. Pas Profilage d’expression
3. Pas d’enquête genetique

CARCINOME PULMONAIRE SMARCB1-DEFICIENT ?

***SMARCB1* ds Carcinomes Pulmonaires**

Données TCGA
NSCLC: 0.47% mutations, del 0.11%
Small cell Ca 0.31% mut et 0.31% del

Carcinome indifférencié/dédifférencié

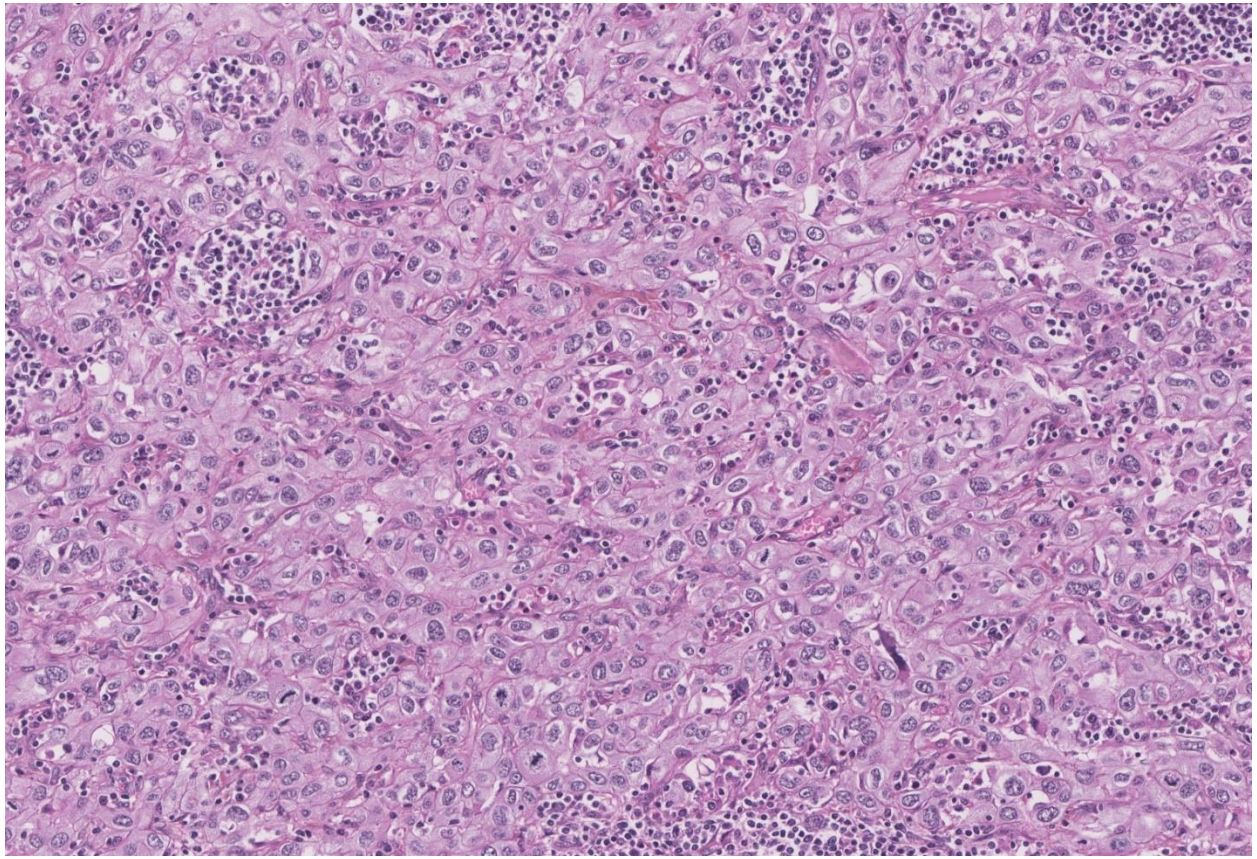

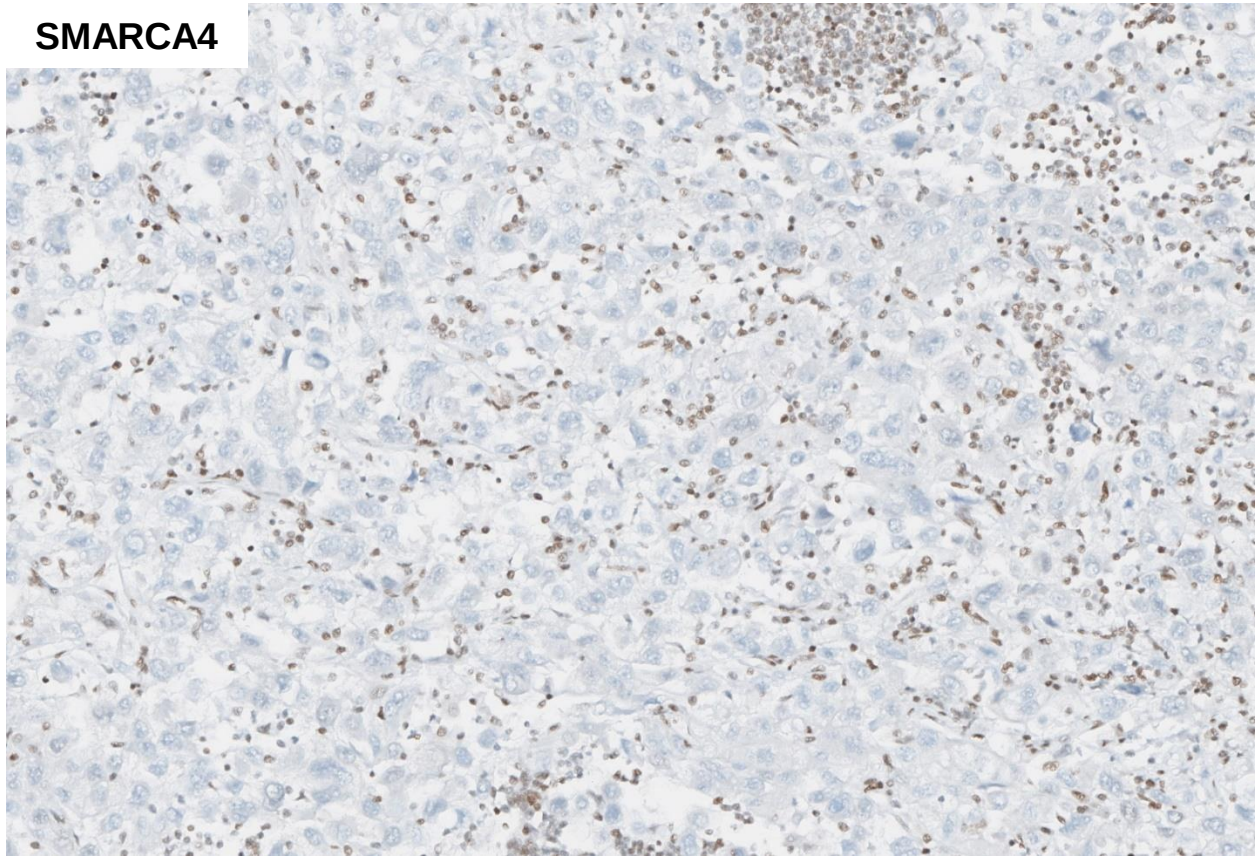

OMS THORACIQUE 2021

Tumeurs pulmonaires SMARCA4-deficientes

NSCLC

Tum thoracique indifferenciee

SMARCA4 UTT

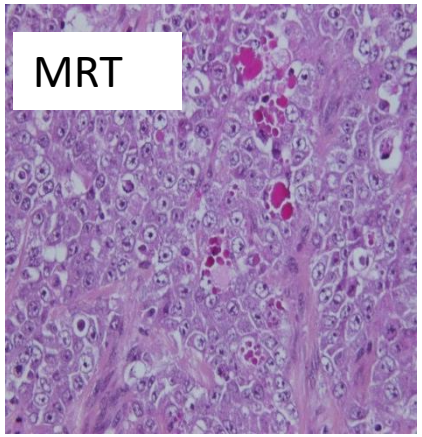

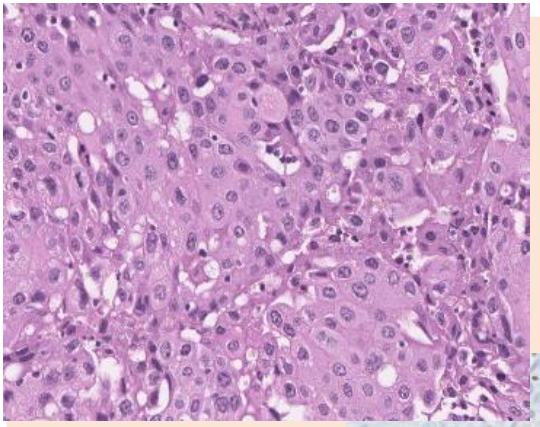

>après 55ans
>Homme
>Tabagique
>Survie 12 mois

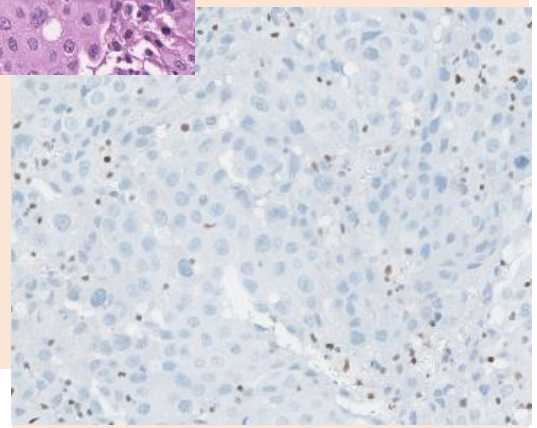

>Pic 30-35ans
>Homme
>Tabagique
>Survie 6 mois

NSCLC AVEC DEFICIENCE SMARCA4

Carcinome indifférencié/dédifférencié

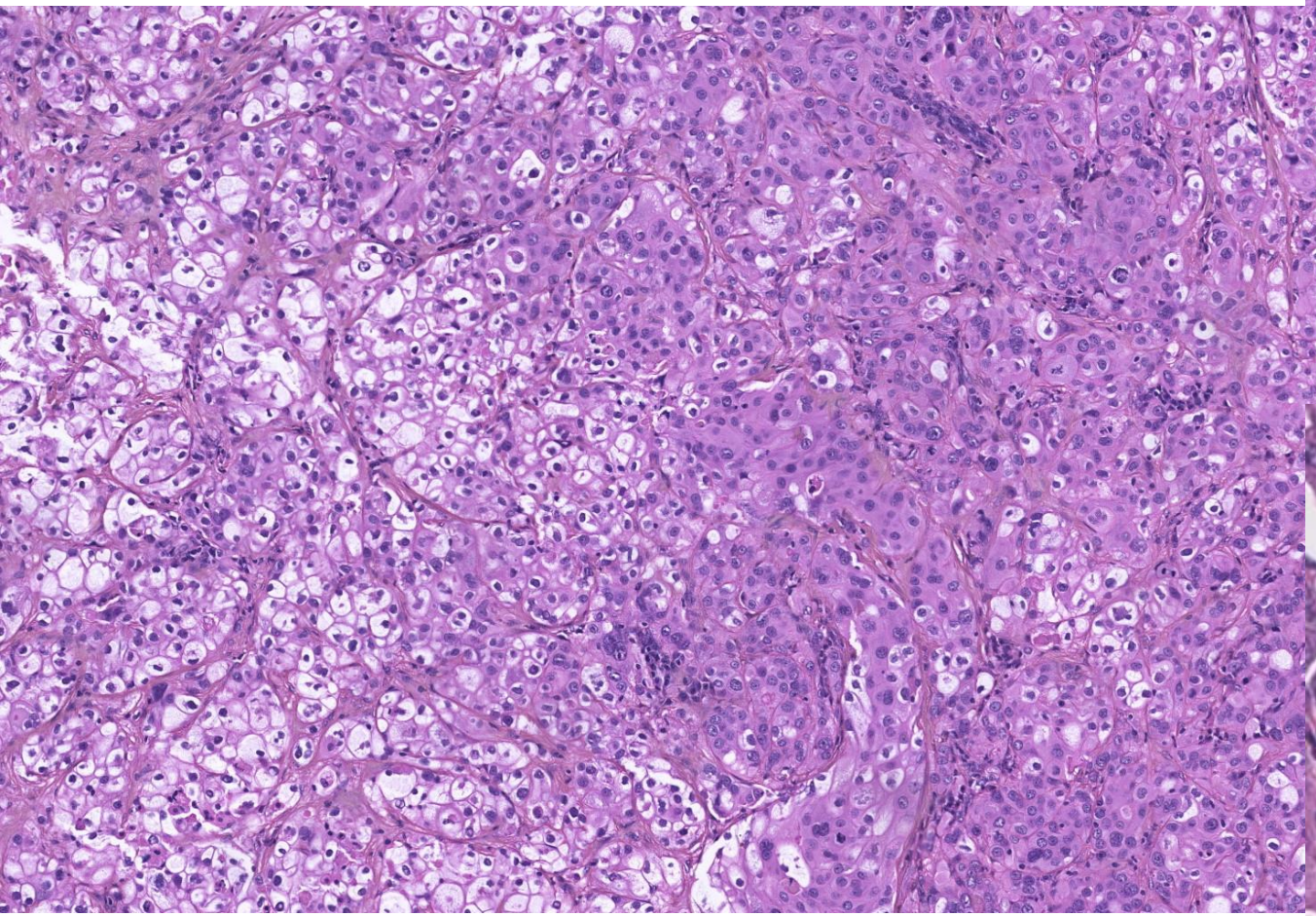

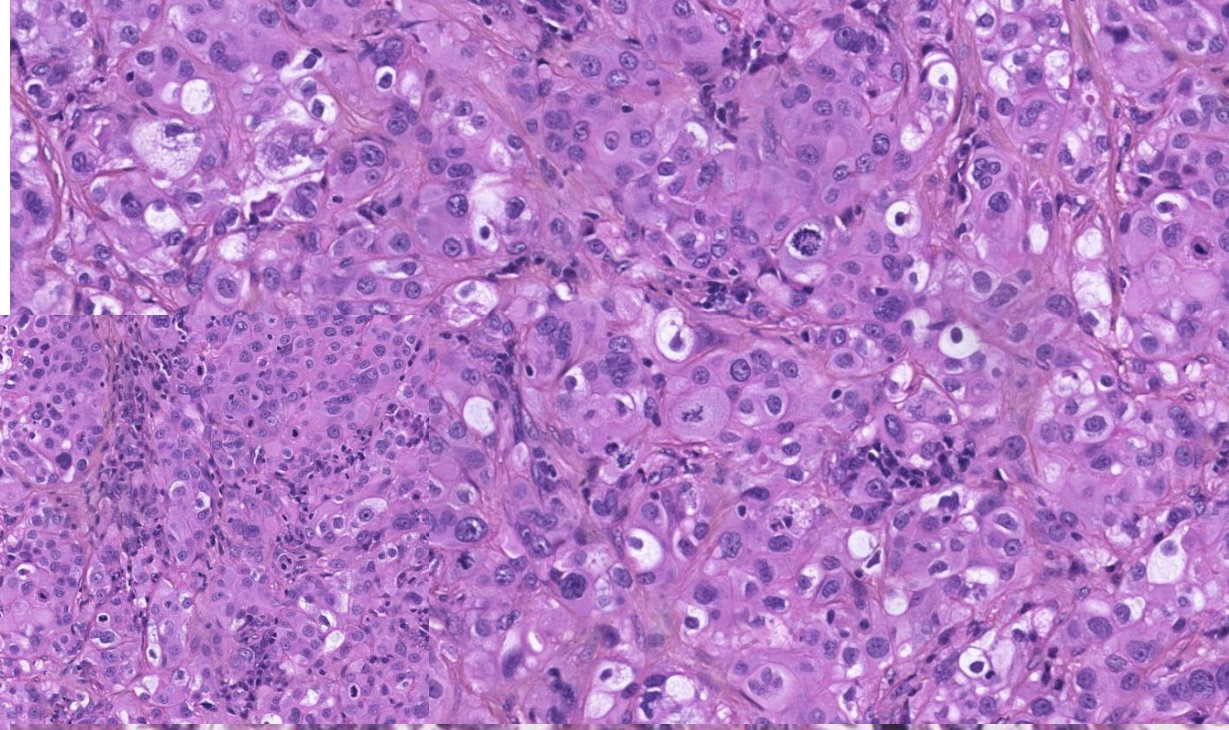

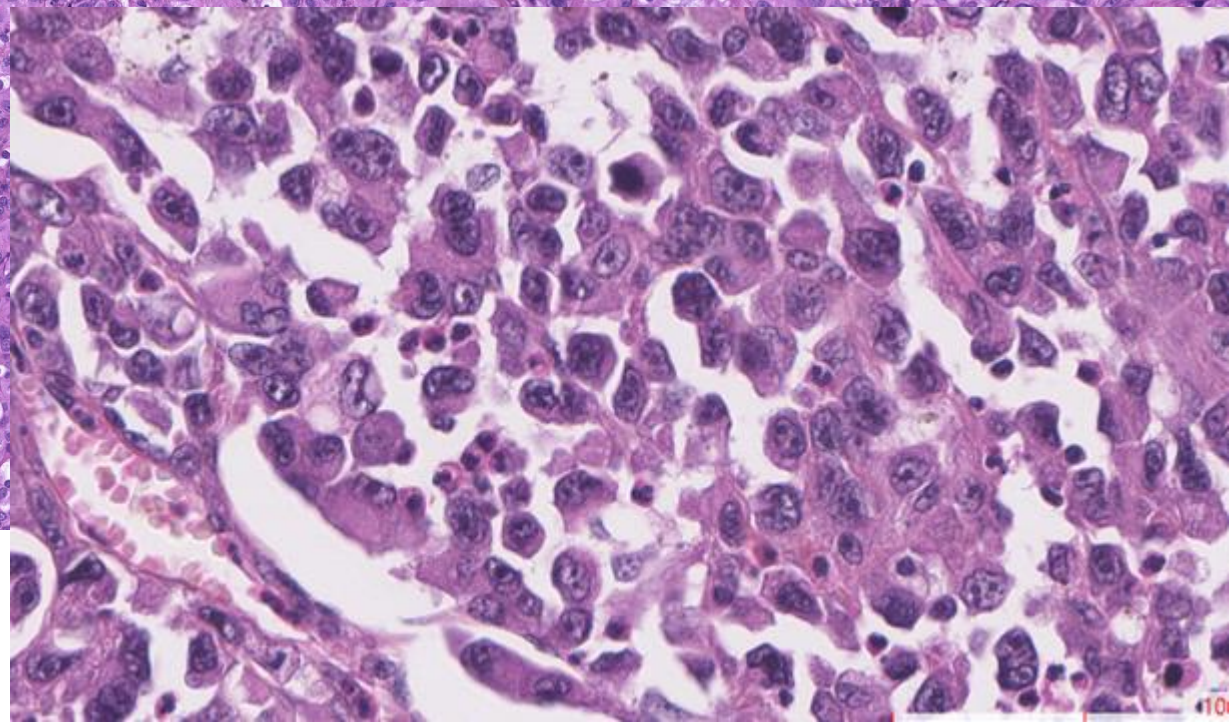

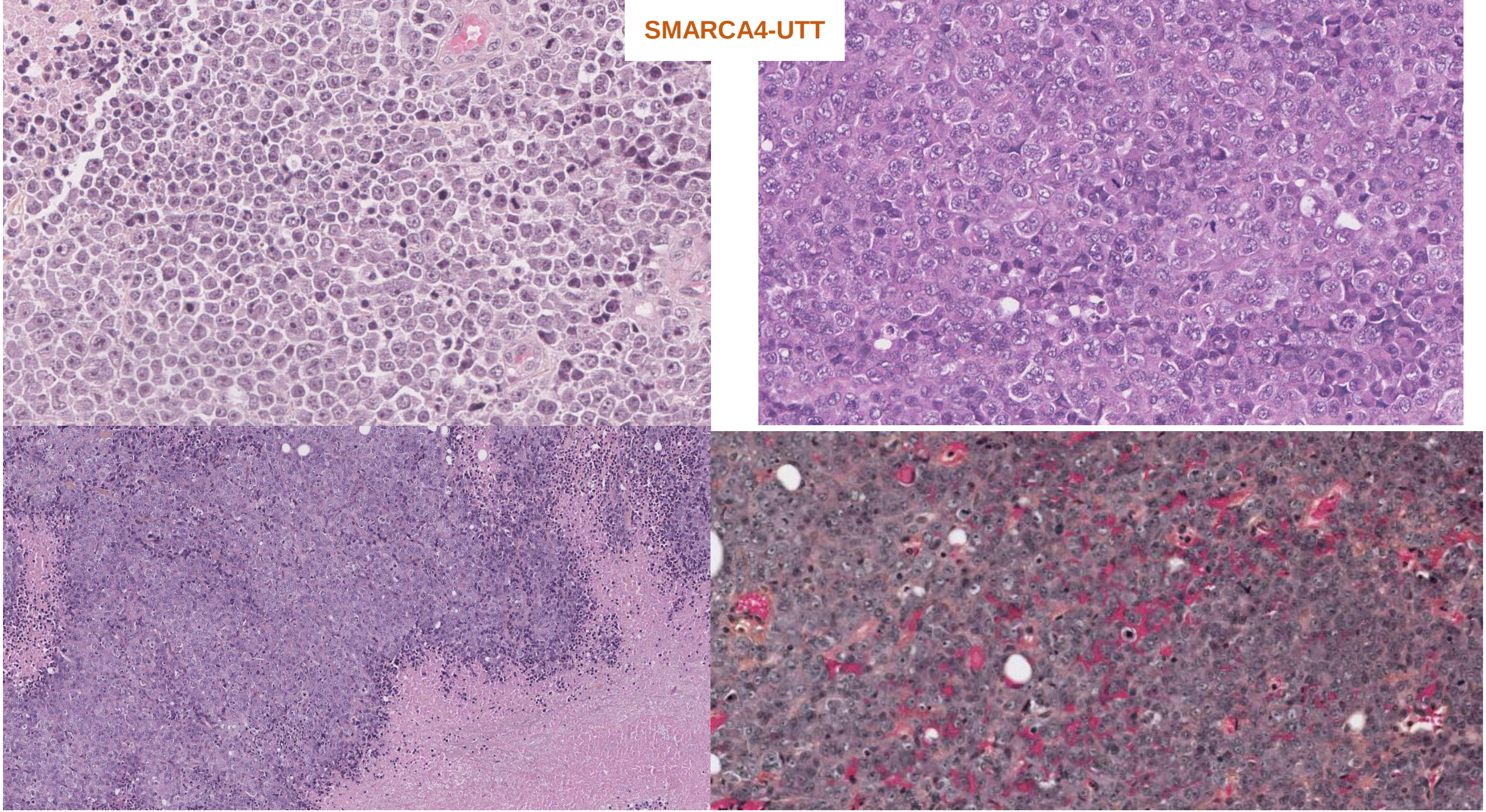

In F Le Loarer et al, Nat Genet, 2015.

PHENOTYPE SMARCA4-UTT

Carc. pulm *SMARCA4* muté

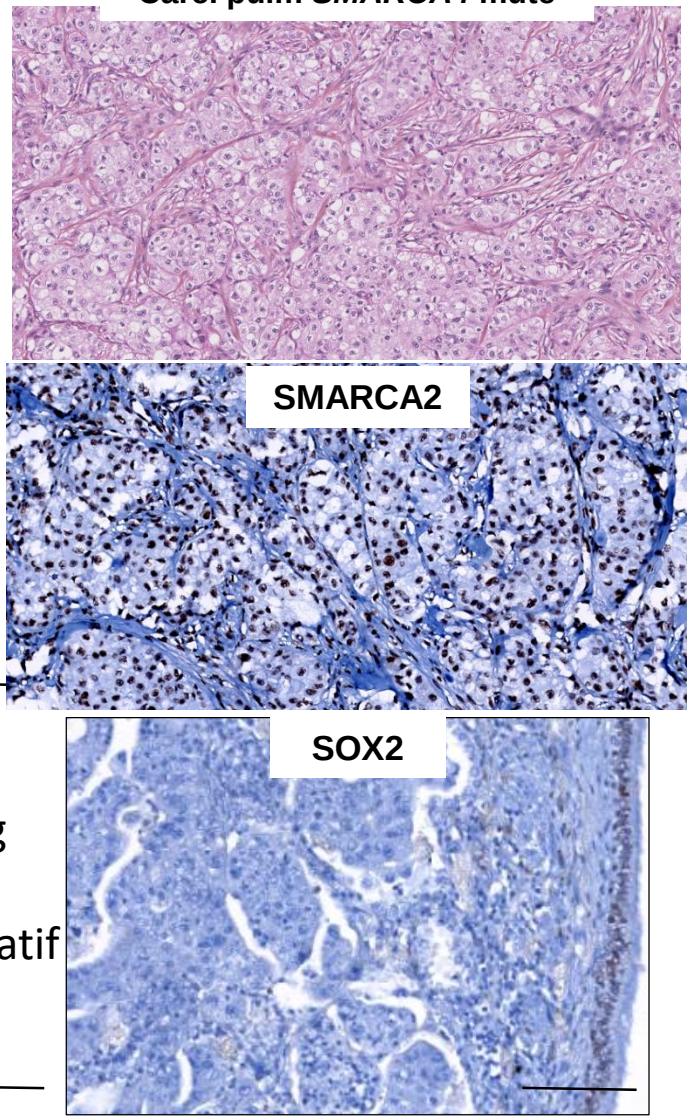

- SALL4 neg
- CD34 negatif

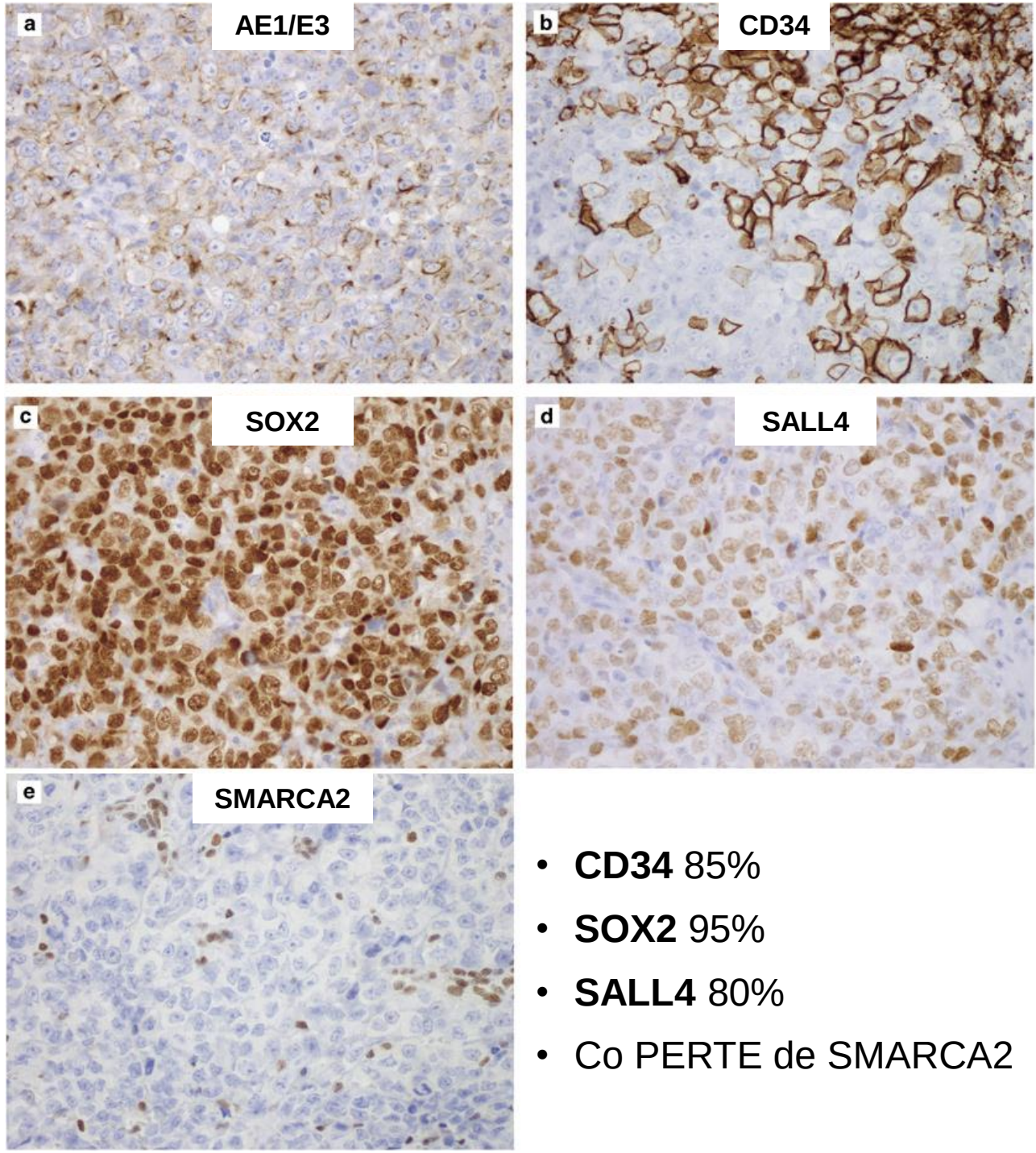

- **CD34** 85%
- **SOX2** 95%
- **SALL4** 80%
- Co PERTE de SMARCA2

in Yoshida A et al, Mod Pathol 2017. Sauter JL et al Mod Pathol, 2017.

OMS THORACIQUE 2021

Tumeurs pulmonaires SMARCA4-deficientes

NSCLC

Tum thoracique indifferenciee SMARCA4-UTT

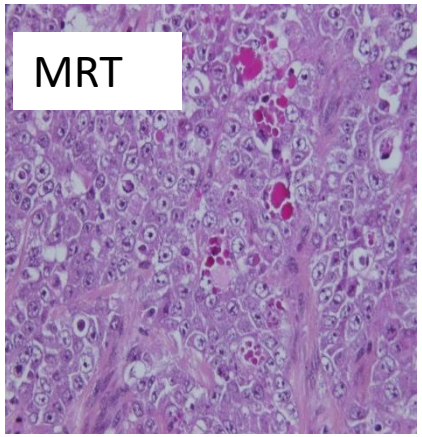

Grey zone cases

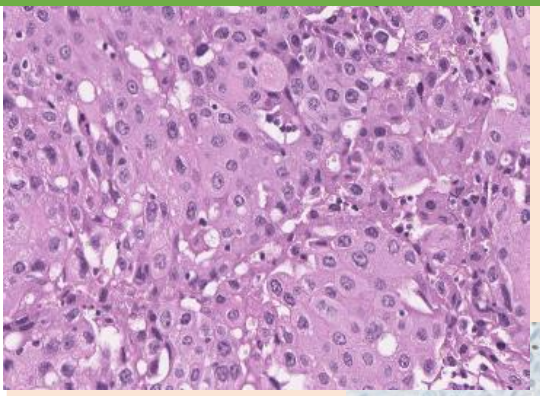

>après 55ans
>Homme
>Tabagique
>Survie 12 mois

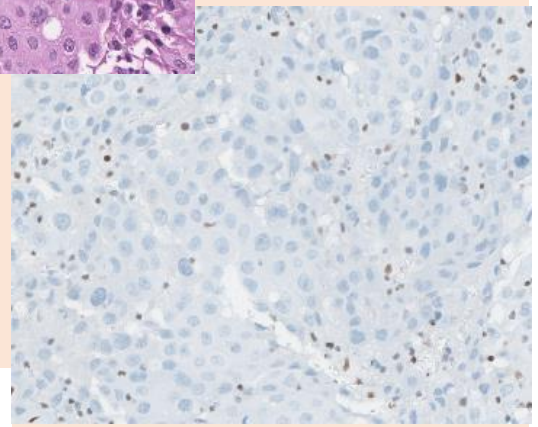

- Foyers carcinomateux exceptionnels
- Mutations oncogènes « pulmonaires »
- Signature mutationnelle tabac
- Profils génétiques remaniés

>Pic 30-35ans
>Homme
>Tabagique
>Survie 6 mois

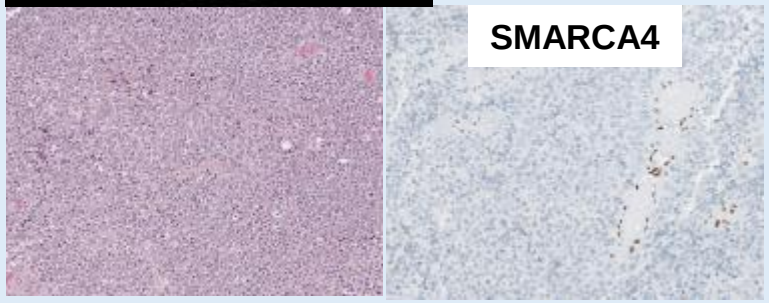

TUMEUR THORACIQUE SMARCB1-déficiente

Série de 9 tumeurs
Prévalence mutation 0.27%

Sur le plan moléculaire

- signature mut tabac 3/9
- Pas mutation oncogene poumon
- Methylation:

✓ 1 cas MRT
✓ 3 cas sarcome epithelioide

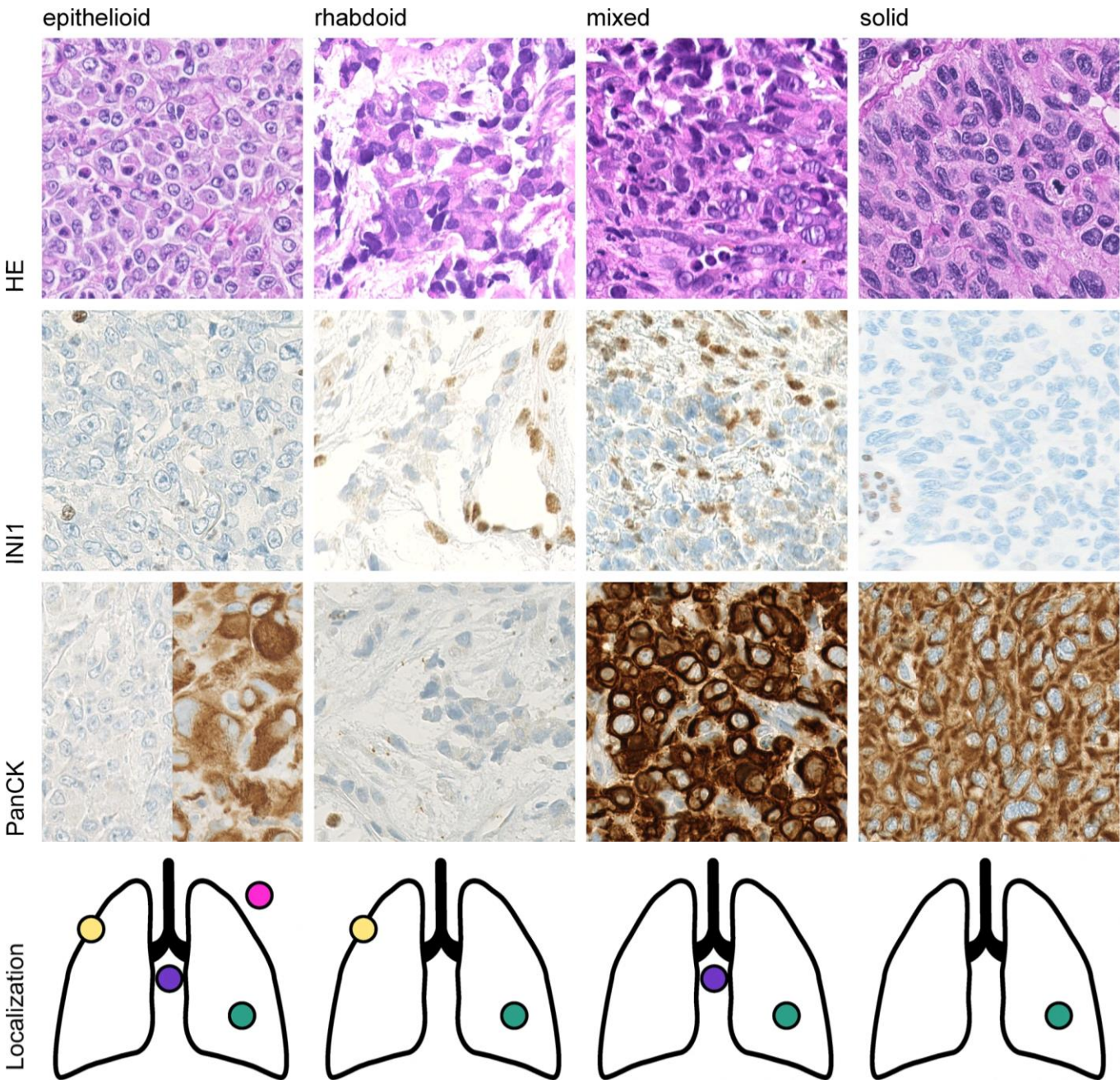

In Haberecker M et al Modern Path 2022

TUMEUR THORACIQUE SMARCB1-déficiente

> Identification de Cas Carcinome-like et de UTT-like !

Cas classé en MRT par méthylome
Genetique simple
only one driver event : smarcb1
Methylation class: MRT
Light smoking signature

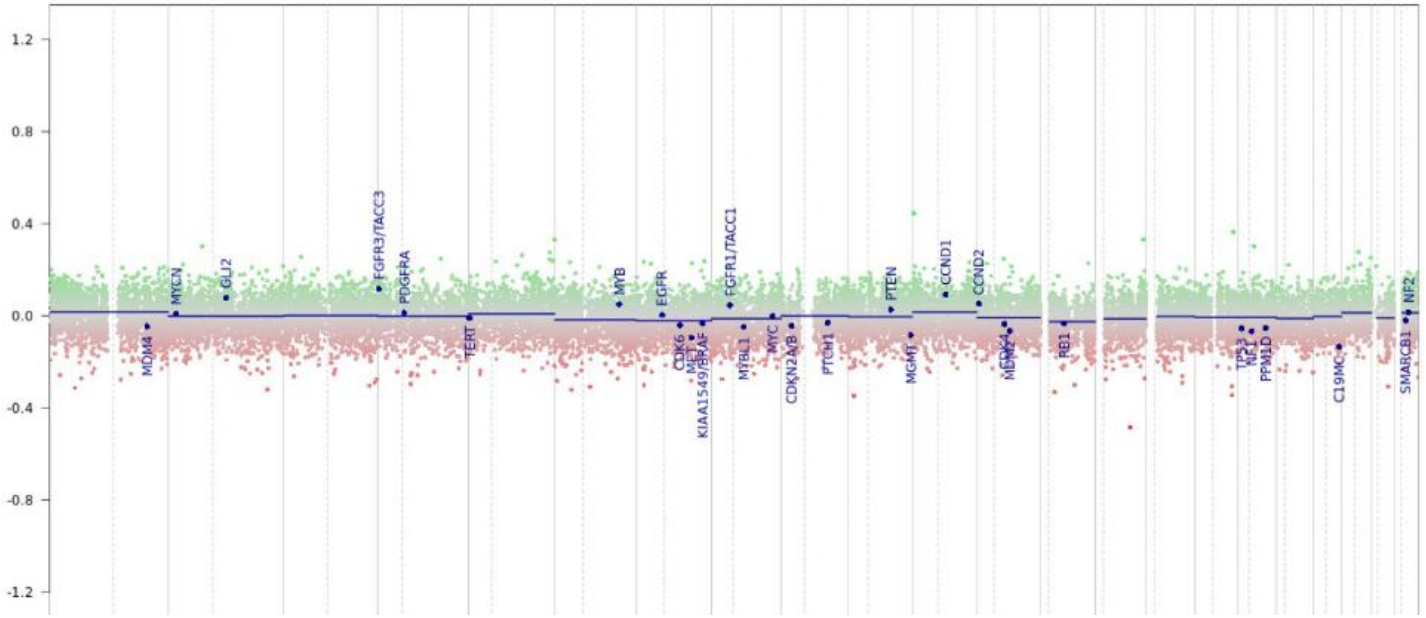

In Haberecker M et al Modern Path 2022

INSTITUT BERGONIÉ
229 cours de l'Argonne
CS 61283 - 33076 Bordeaux cedex
www.bergonie.org
CENTRE RÉGIONAL DE LUTTE CONTRE LE CANCER DE BORDEAUX ET DU SUD-OUEST

UNICANCER
MEMBRE DU GROUPE

université de BORDEAUX

CARREFOUR PATHOLOGIE 2022
HISTOSEMINAIRE Pr C Guettier

CAS 5:
TUMEUR THORACIQUE MALIGNE INDIFFERENCIEE SMARCB1-DEFICIENTE

François LE LOARER, MD, PhD

Université de Bordeaux & CLCC Bordeaux

Mail f.le-loarer@bordeaux.unicancer.fr