Congratulations !

May all success be with you forever

Our best wishes and warmest regards

TURKISH SOCIETY OF CYTOPATHOLOGY

50th anniversary of the French Society of Clinical Cytology

Congratulations!

TURKISH SOCIETY OF CYTOPATHOLOGY

50th anniversary of the French Society of Clinical Cytology

Guidelines for Cytopathological Diagnosis of Malignant Mesothelioma – 2015 Statement

Pinar Firat, MD, MIAC

Istanbul, TURKEY

KOÇ UNIVERSITY

Cytopathological Diagnosis of Malignant Mesothelioma

- Serous effusions are the most colorful specimens of the cytopathology practice ! *(My favorite, I am biased)*
- An invaluable tool to answer the clinicians' questions in a fast and accurate way *(if especially accompanied by ancillary tests)*
- Patients suffering from mesothelioma frequently present with effusions
- Cytologic examination can give a definitive diagnosis in mesothelioma
  - But not in each case
  - It is (has been) a controversial issue
- It is generally a pattern diagnosis rather than being based on cellular features - and has to be supported by ancillary tests
  - As the ancillary tests distinguishing benign from malignant mesothelial proliferations improve, cytologic diagnosis of mesothelioma becomes more achiveable

Cytopathological Diagnosis of Malignant Mesothelioma

What are the difficulties ?

- Sarcomatoid and desmoplastic mesotheliomas do not shed cells
  - Only epithelioid mesotheliomas are the target of cytologic diagnosis
- Nuclear atypia is not pronounced in most mesotheliomas
  - By definition makes cytologic recognition difficult
- Invasion of the underlying tissue is an important diagnostic criteria
  - Can not be assesed by cytology
- However; the cytological features of malignant mesothelioma are well described in the literature, and some cases present with these typical findings; in addition, specific ancillary tests – eventhough their sensitivity is not very high- have been developed

Guidelines for Pathologic Diagnosis of Malignant Mesothelioma

2017 Update of the Consensus Statement From the International Mesothelioma Interest Group

Aliya Noor Husain, MD; Thomas V. Colby, MD; Nelson G. Ordóñez, MD; Timothy Craig Allen, MD, JD; Richard Luther Attanoos, MBBS, MD, FRCPath; Mary Beth Beasley, MD; Kelly Jo Butnor, MD; Lucian R. Chirieac, MD; Andrew M. Churg, MD; Sanja Dacic, MD, PhD; Françoise Galateau-Sallé, MD; Allen Gibbs, MD; Allen M. Gown, MD; Thomas Krausz, MD; Leslie Anne Litzky, MD; Alberto Marchevsky, MD; Andrew G. Nicholson, DM; Victor Louis Roggli, MD; Anupama K. Sharma, MD; William D. Travis, MD; Ann E. Walts, MD; Mark R. Wick, MD

- '… Emerging data that indicate subtyping of epithelioid MM according to morphologic features and nuclear grade are important to predicting survival and suggest that a cytologic diagnosis of malignant mesothelioma epithelioid type might not be sufficient in the future..'

(Arch Pathol Lab Med. doi: 10.5858/arpa.2017-0124-RA)

Review

ACTA CYTOLOGICA

Acta Cytologica 2015;59:2–16
DOI: 10.1159/000377697

Received: December 23, 2014
Accepted: December 29, 2014
Published online: March 24, 2015

Guidelines for the Cytopathologic Diagnosis of Epithelioid and Mixed-Type Malignant Mesothelioma

Complementary Statement from the International Mesothelioma Interest Group, Also Endorsed by the International Academy of Cytology and the Papanicolaou Society of Cytopathology

Anders Hjerpe[a] Valeria Ascoli[b] Carlos W.M. Bedrossian[c] Mathilde E. Boon[d] Jenette Creaney[e] Ben Davidson[f] Annika Dejmek[g] Katalin Dobra[a] Ambrogio Fassina[h] Andrew Field[i] Pinar Firat[j] Toshiaki Kamei[k] Tadao Kobayashi[l] Claire W. Michael[m] Sevgen Önder[n] Amanda Segal[o] Philippe Vielh[p]

[a]Division of Clinical Pathology/Cytology, Department of Laboratory Medicine, Karolinska Institutet, Karolinska University Hospital Huddinge, Huddinge, Sweden; [b]Department of Radiological, Oncological and Pathological Sciences, Sapienza University, Rome, Italy; [c]Rush University Medical College, Chicago, Ill., USA; [d]Leiden Cytology and Pathology Laboratory, Lieveren, The Netherlands; [e]National Centre for Asbestos Related Disease, School of Medicine and Pharmacology, University of Western Australia, QEII Medical Centre, Perth, W.A., Australia; [f]Department of Pathology, The Norwegian Radium Hospital, Oslo University Hospital, Oslo, Norway; [g]Department of Laboratory Medicine in Malmö, Lund University, Malmö University Hospital, Malmö, Sweden; [h]Department of Medicine, University of Padova, Padova, Italy; [i]Department of Anatomical Pathology, St Vincents Hospital, Sydney, N.S.W., Australia; [j]Istanbul University, Istanbul Faculty of Medicine, Istanbul, Turkey; [k]Division of Pathology, Yamaguchi Grand Medical Center, Hofu, and [l]Cancer Education and Research Center, Osaka University Graduate School of Medicine, Osaka, Japan; [m]Case Western Reserve University/University Hospitals Case Medical Center, Department of Pathology, Cleveland, Ohio, USA; [n]Hacettepe University, Faculty of Medicine, Department of Pathology, Ankara, Turkey; [o]Department of Tissue Pathology, PathWest Laboratory Medicine WA, QE2 Medical Centre, Perth, W.A., Australia; [p]Department of Biopathology, Gustave Roussy Comprehensive Cancer Center, Villejuif, France

Guidelines for the Cytopathologic Diagnosis of Epithelioid and Mixed-Type Malignant Mesothelioma

Complementary Statement from the International Mesothelioma Interest Group, Also Endorsed by the International Academy of Cytology and the Papanicolaou Society of Cytopathology

Anders Hjerpe,[1*] Valeria Ascoli,[2] Carlos W.M. Bedrossian,[3] Mathilde E. Boon,[4] Jenette Creaney,[5] Ben Davidson,[6] Annika Dejmek,[7] Katalin Dobra,[1] Ambrogio Fassina,[8] Andrew Field,[9] Pinar Firat,[10] Toshiaki Kamei,[11] Tadao Kobayashi,[12] Claire W. Michael,[13] Sevgen Onder,[14] Amanda Segal,[15] and Philippe Vielh[16]

REVIEW

Diagnostic Cytopathology, Vol. 43, No 7

Guidelines for the Cytopathologic Diagnosis of Epithelioid and Mixed-Type Malignant Mesothelioma: a secondary publication[1]

A. Hjerpe*, V. Ascoli†, C. W. M. Bedrossian‡, M. E. Boon§, J. Creaney¶, B. Davidson**, A. Dejmek††, K. Dobra*, A. Fassina‡‡, A. Field§§, P. Firat¶¶, T. Kamei***, T. Kobayashi†††, C. W. Michael‡‡‡, S. Önder§§§, A. Segal¶¶¶ and P. Vielh****

Cytopathology 2015, **26**, 142–156

Malignant mesotheliomas on cytology are either,

- Clearly malignant by cytomorphology — IHC / ICC for mesothelial phenotype
- Require ancillary testing to establish malignan — Molecular tests + IHC / ICC
- Can not be diagnosed by cytology — Biopsy

Acta Cytologica 2015;59:2–16

Malignant mesothelioma on cytology ,..

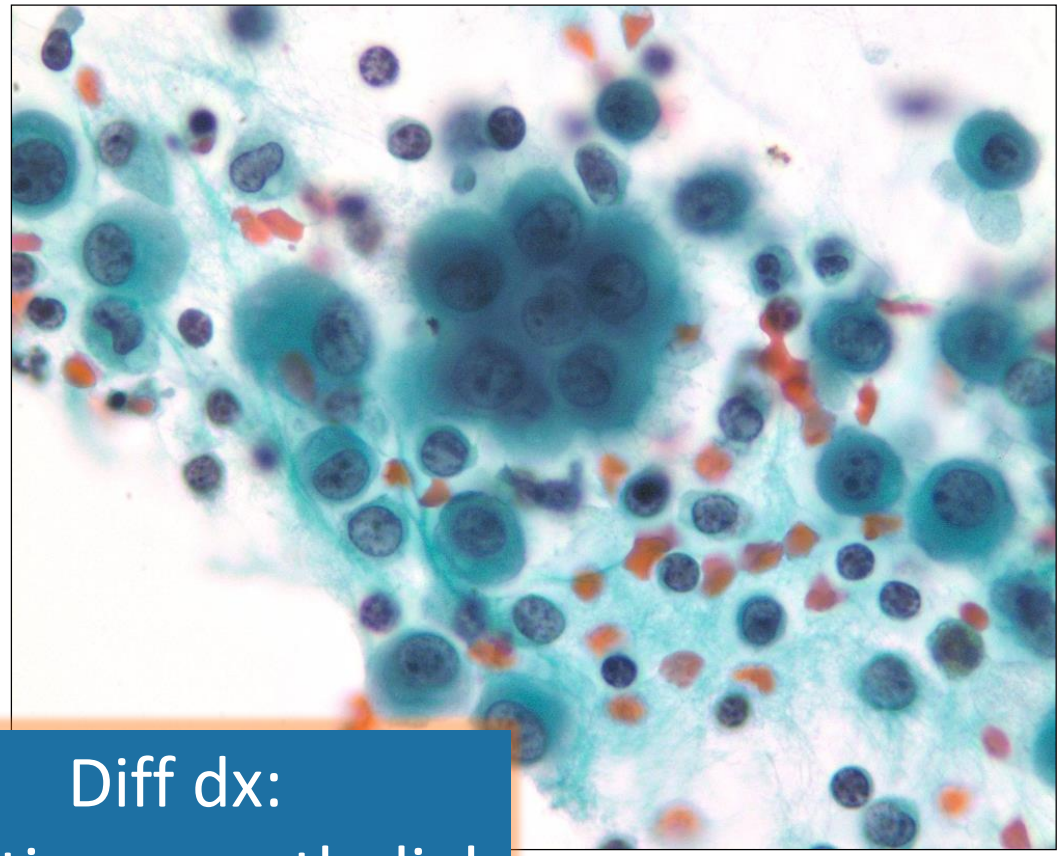

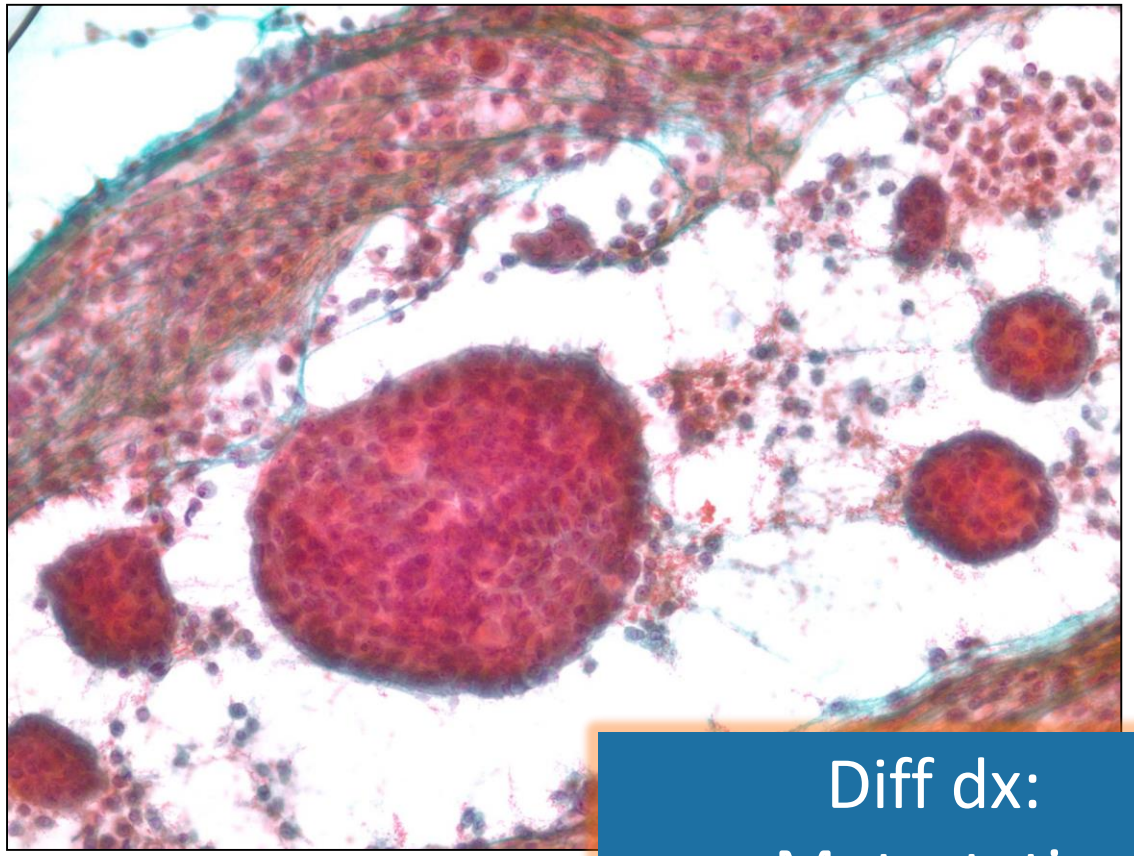

Diff dx:
Reactive mesothelial proliferation

Diff dx:
Metastatic carcinoma

Malignant mesothelioma on cytology ,..

Molecular tests + IHC / ICC

Biopsy

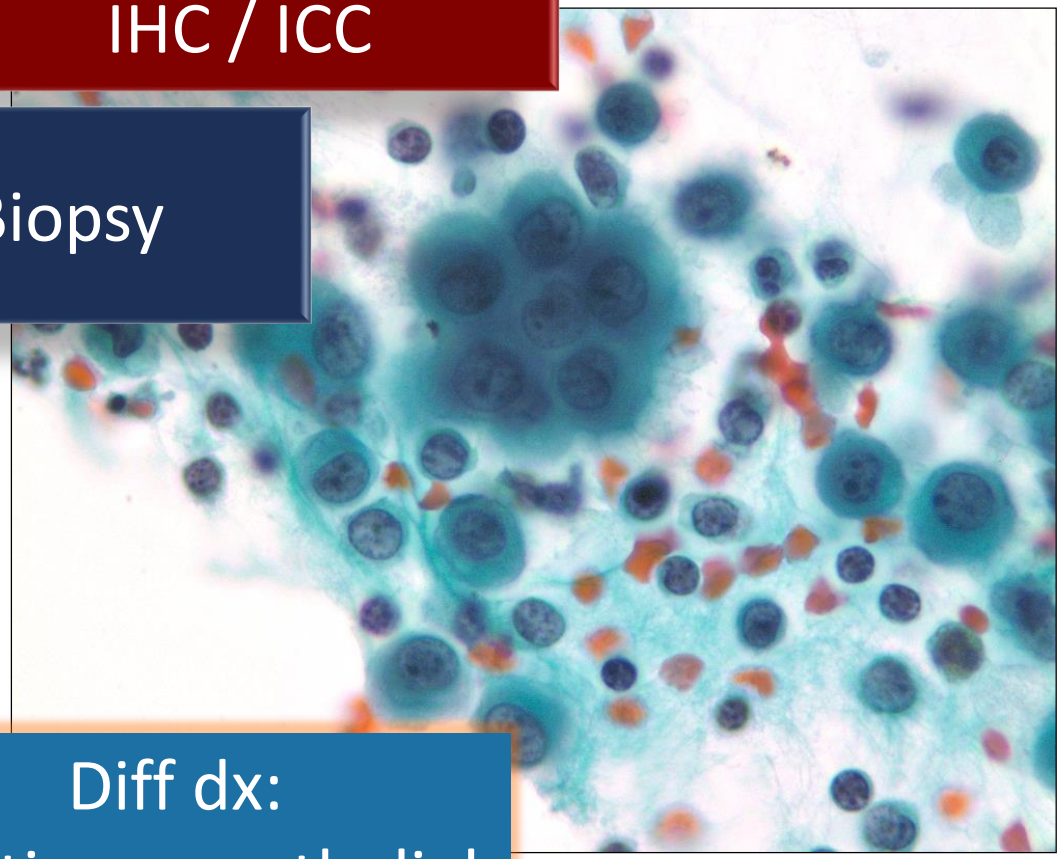

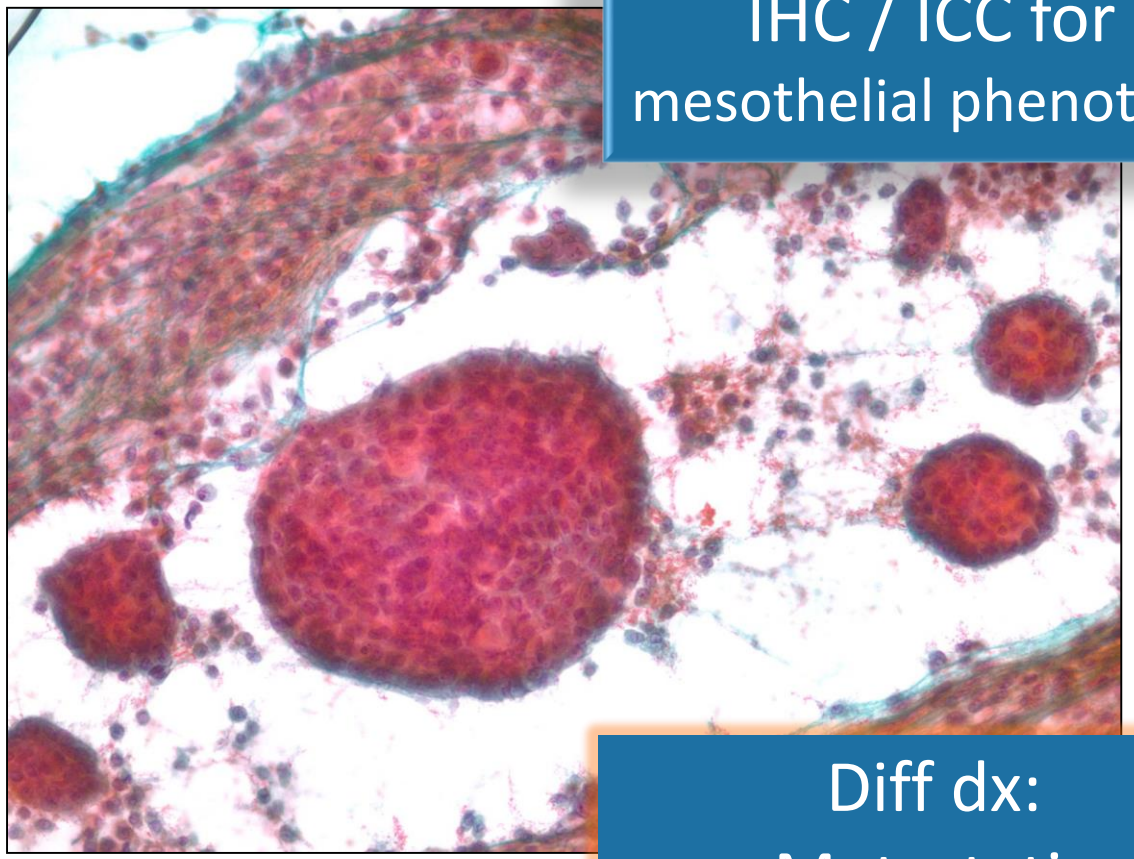

IHC / ICC for mesothelial phenotype

Diff dx:
Reactive mesothelial proliferation

Diff dx:
Metastatic carcinoma

Guidelines for the Cytopathologic Diagnosis of Epithelioid and Mixed-Type Malignant Mesothelioma

Table 2. Summary of cytomorphological criteria indicating malignant mesothelioma
Highly cellular sample, often including large and small tissue fragments
Mesothelial cells significantly larger than normal, either singly or in tissue fragments; each component is enlarged: cytoplasm, nucleus and nucleolus
Papillary tissue fragments forming spheres with a smooth surface or berry-like tissue fragments with a scalloped surface, sometimes with clear spaces or 'windows' between the cells
Acidophilic extracellular matrix cores - collagen cores- within the tissue fragments and an extracellular granular acidophilic background indicating large amounts of hyaluronan
The presence of macronucleoli
Protrusions from the cell membrane or blebbing
Prominent degree of cell-within-cell arrangements
Multinucleated giant cells and small pyknotic eosinophilic or orangeophilic cells

Acta Cytologica 2015;59:2–16

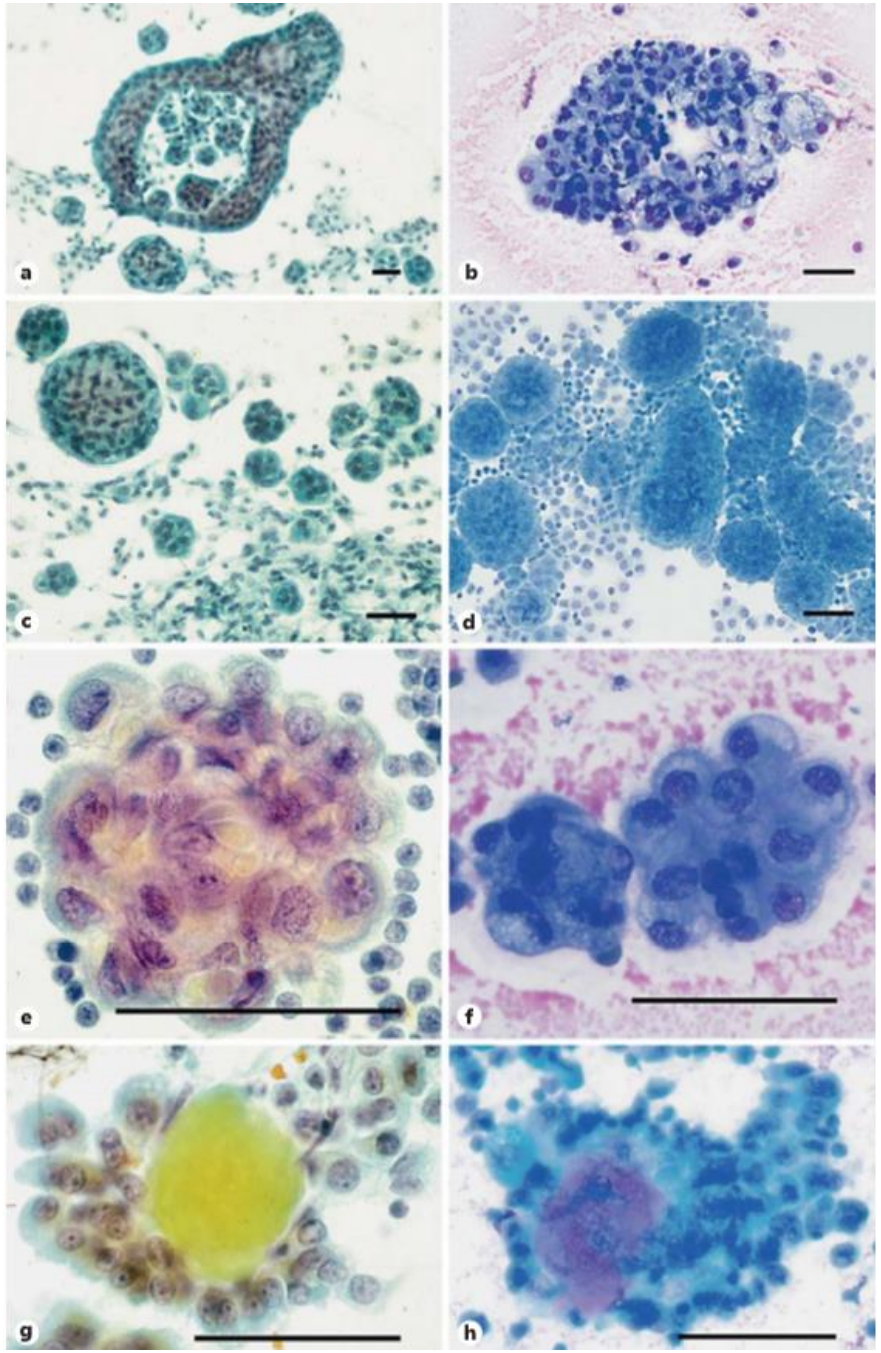

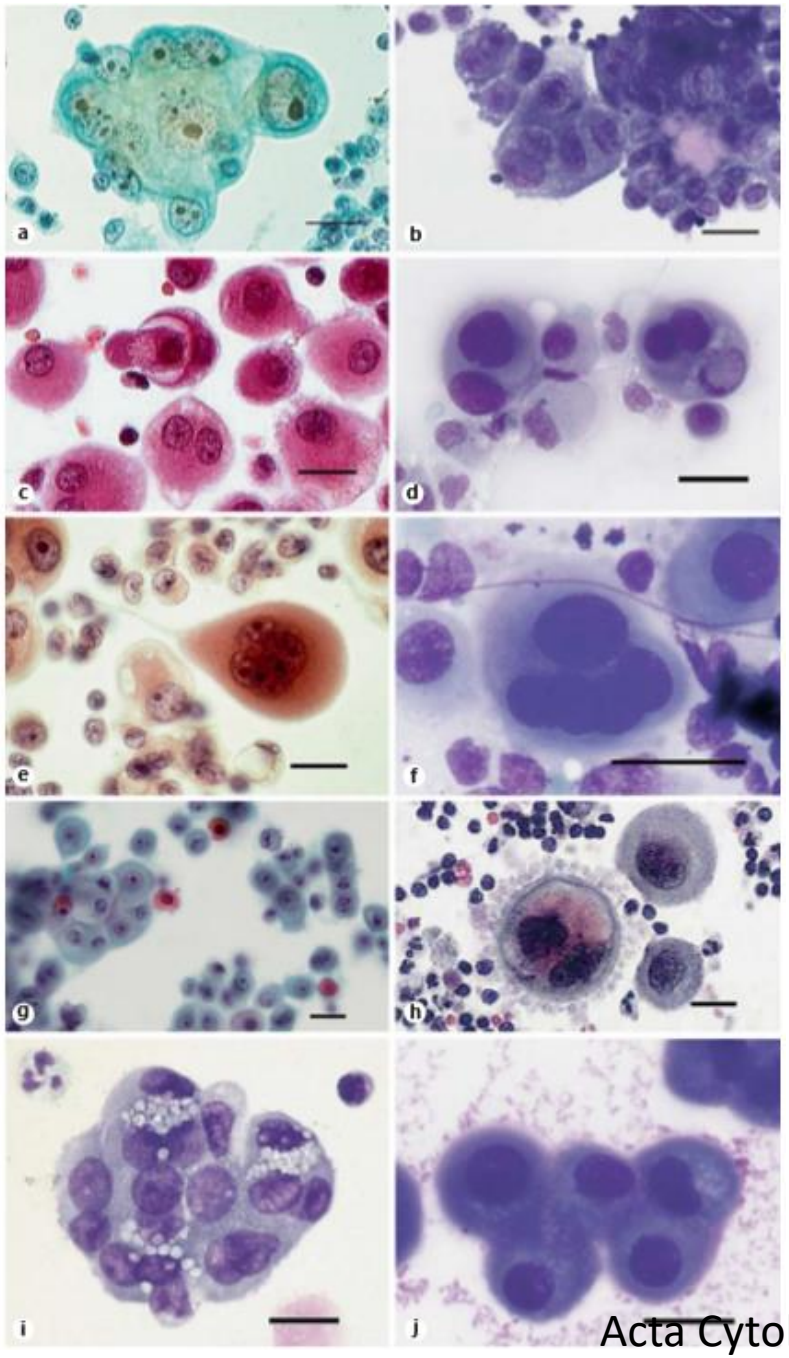

Acta Cytologica 2015;59:2–16

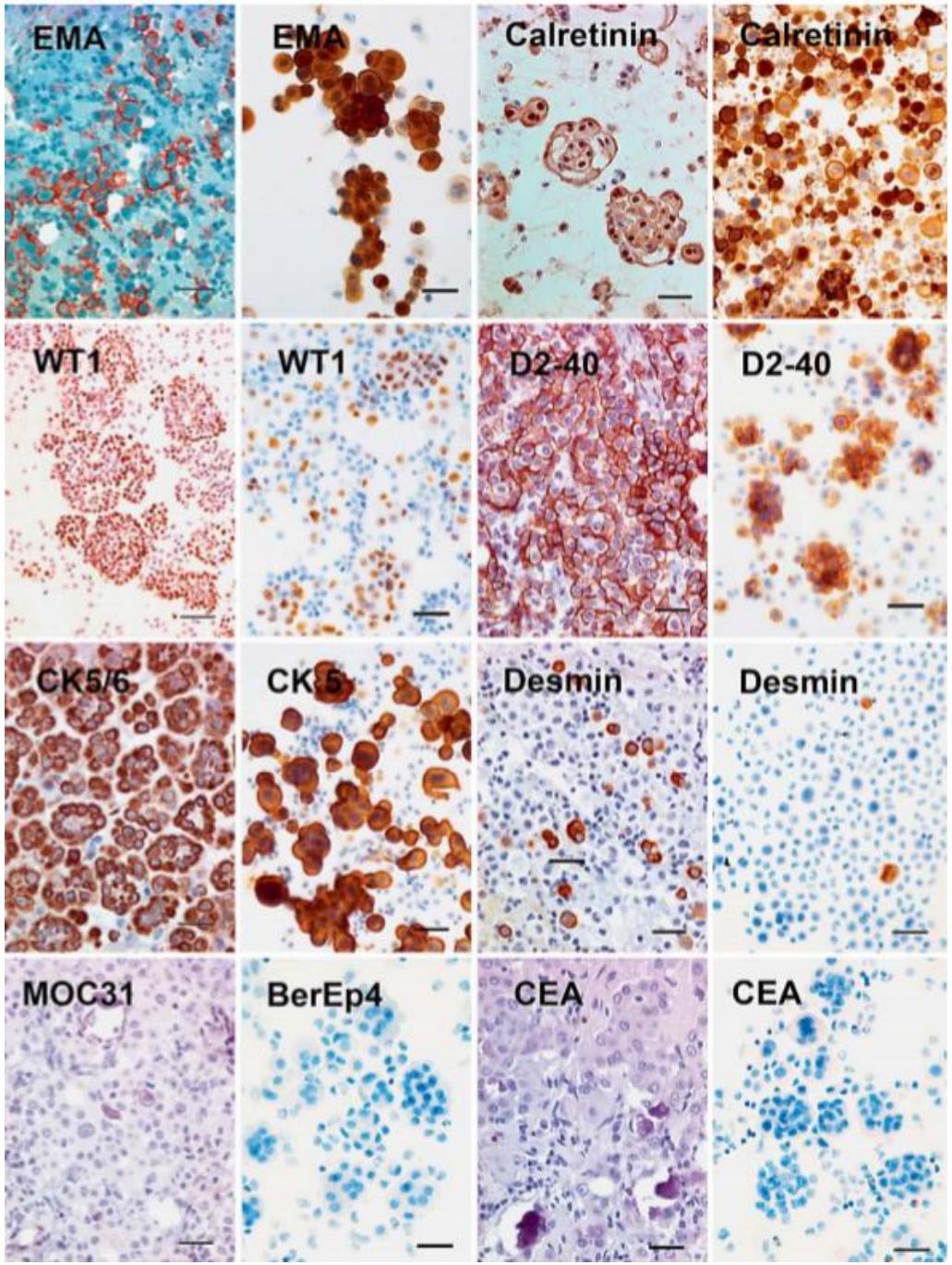

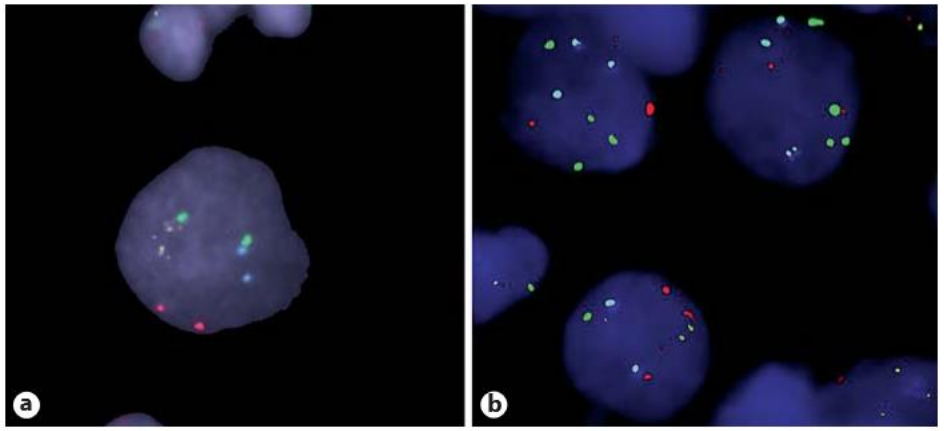

Fig. 8. FISH analysis of ploidy. The Abbot UroVysion® kit labels centromeric sequences on chromosomes 3 (red), 7 (green) and 17 (blue), showing gains or losses of the chromosome, while the fourth probe (yellow) labels the 9p21 band, containing the p16INK gene. The benign cell (**a**) shows two signals for each probe while the MM cells often present with homozygous deletion of the 9p21 band (**b**).

Acta Cytologica 2015;59:2–16

Reactive mesothelial cells

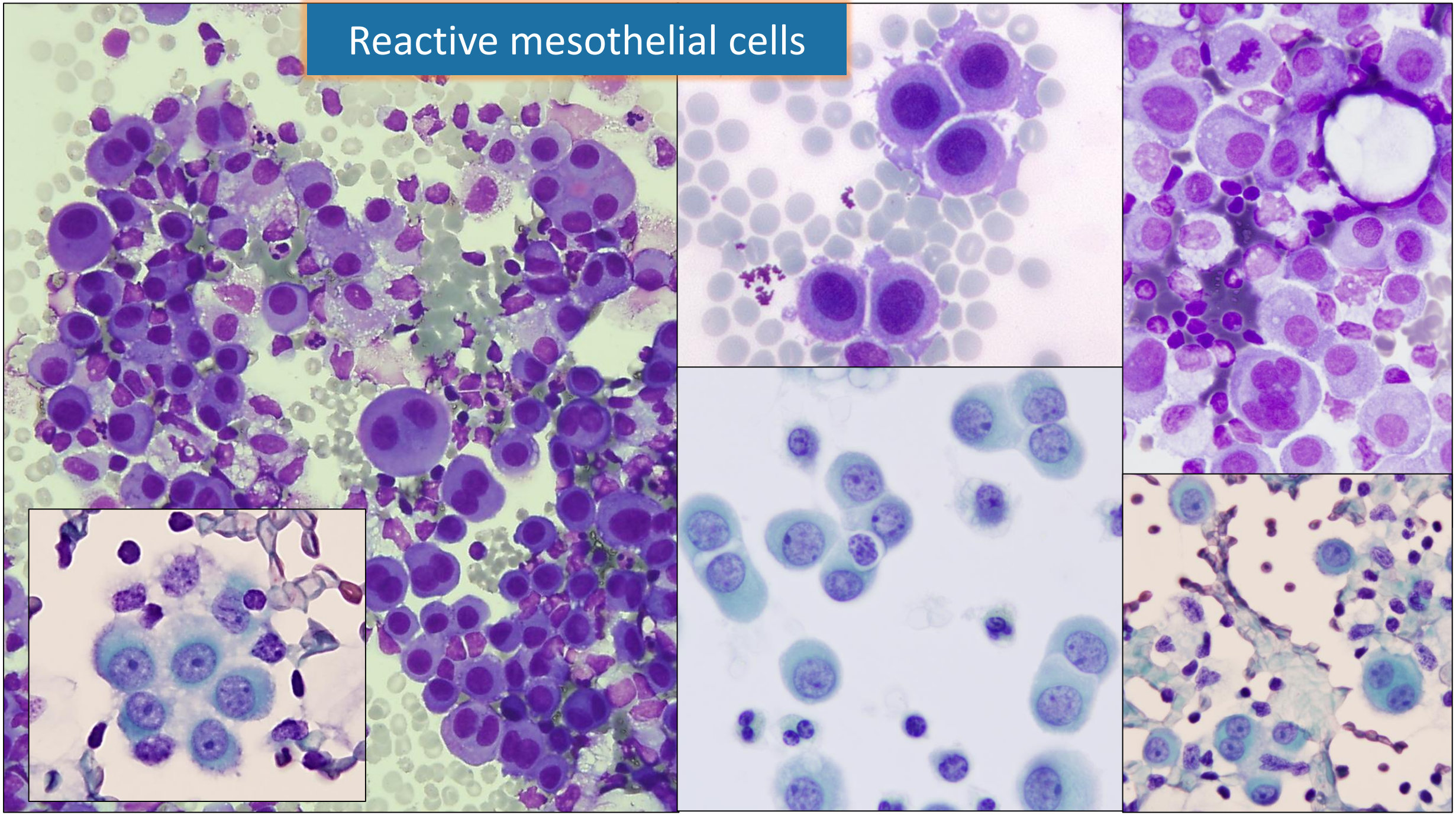

Reactive mesothelial cells

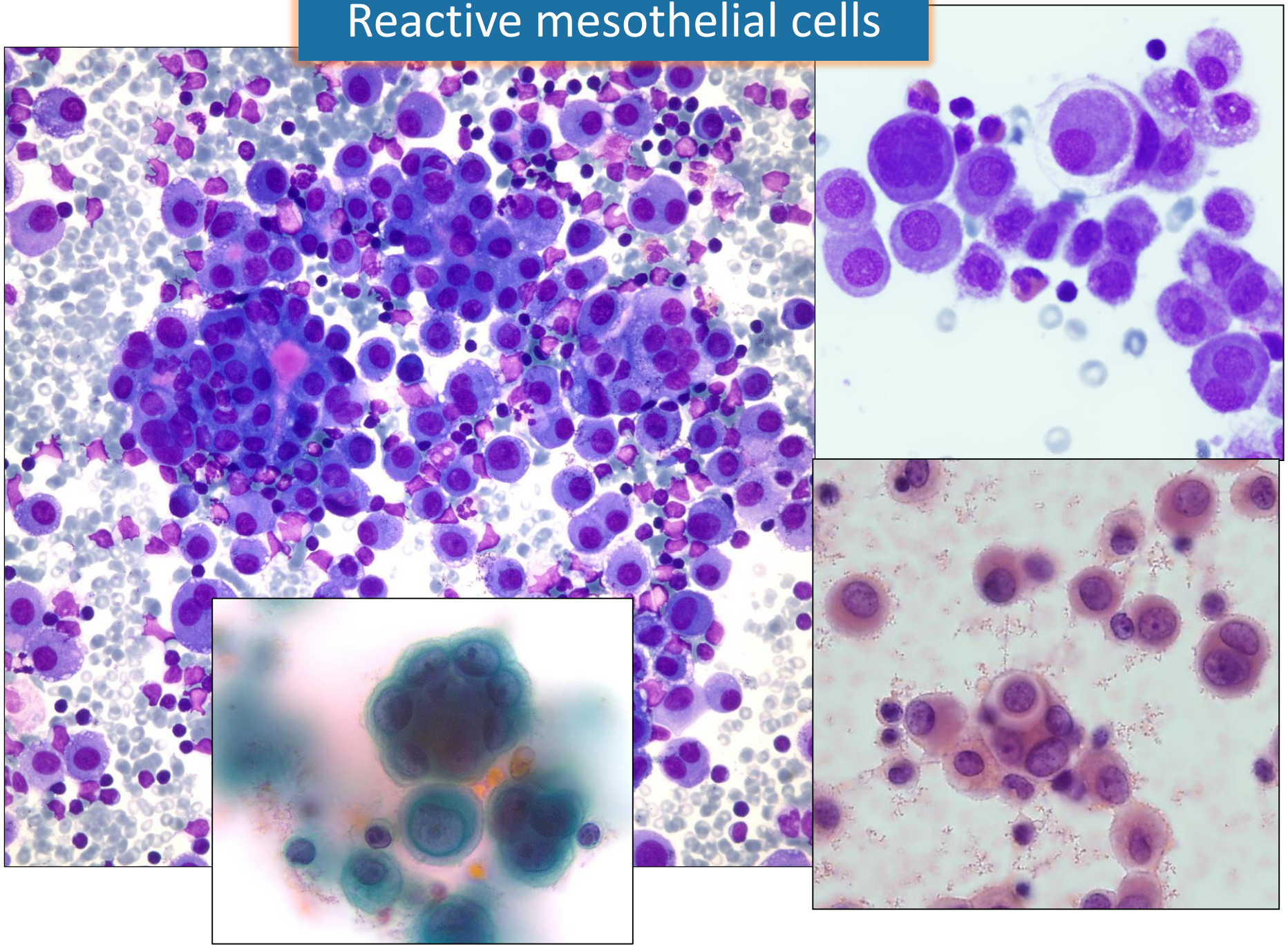

Malignant mesothelioma

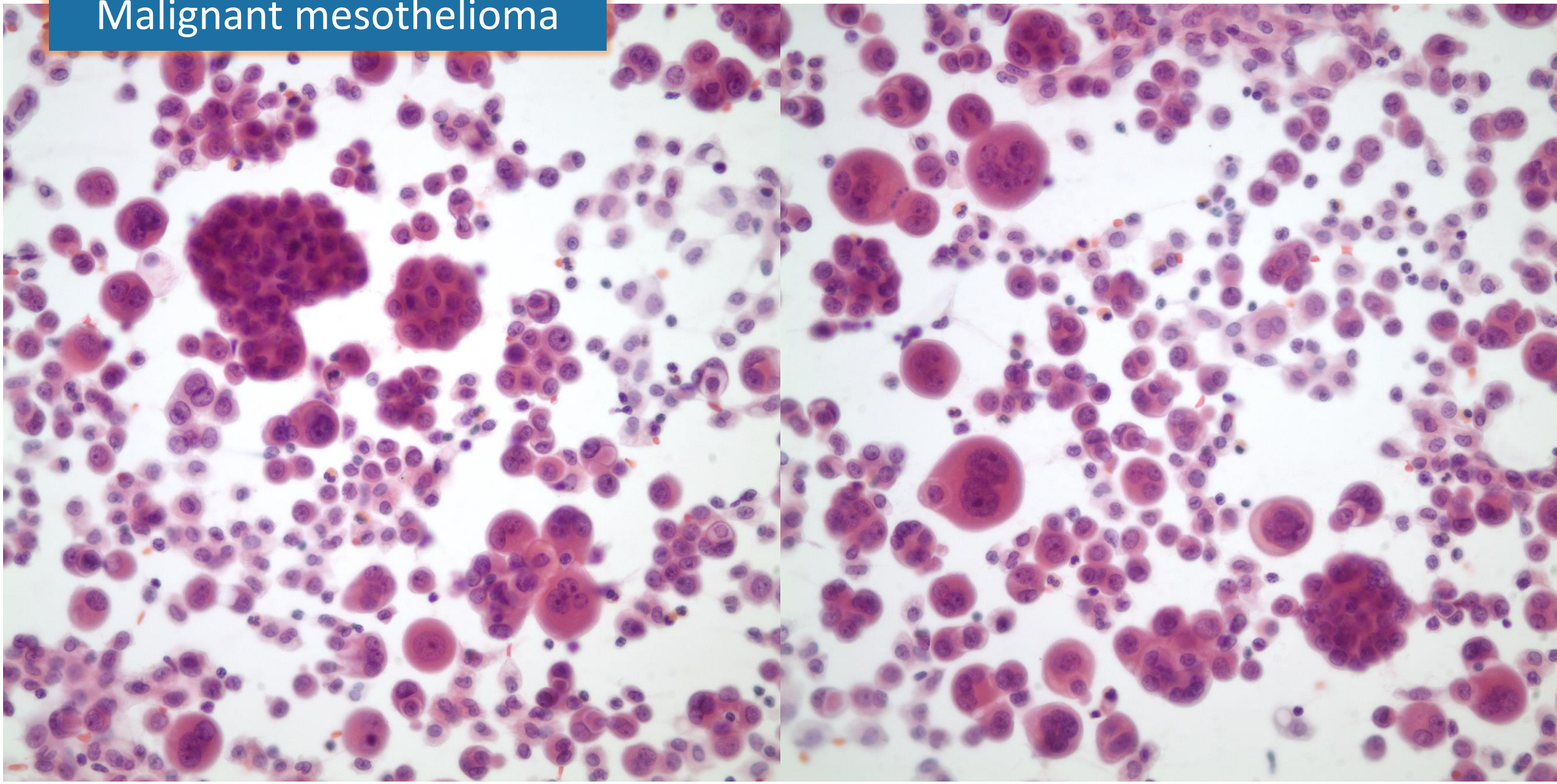

Malignant mesothelioma

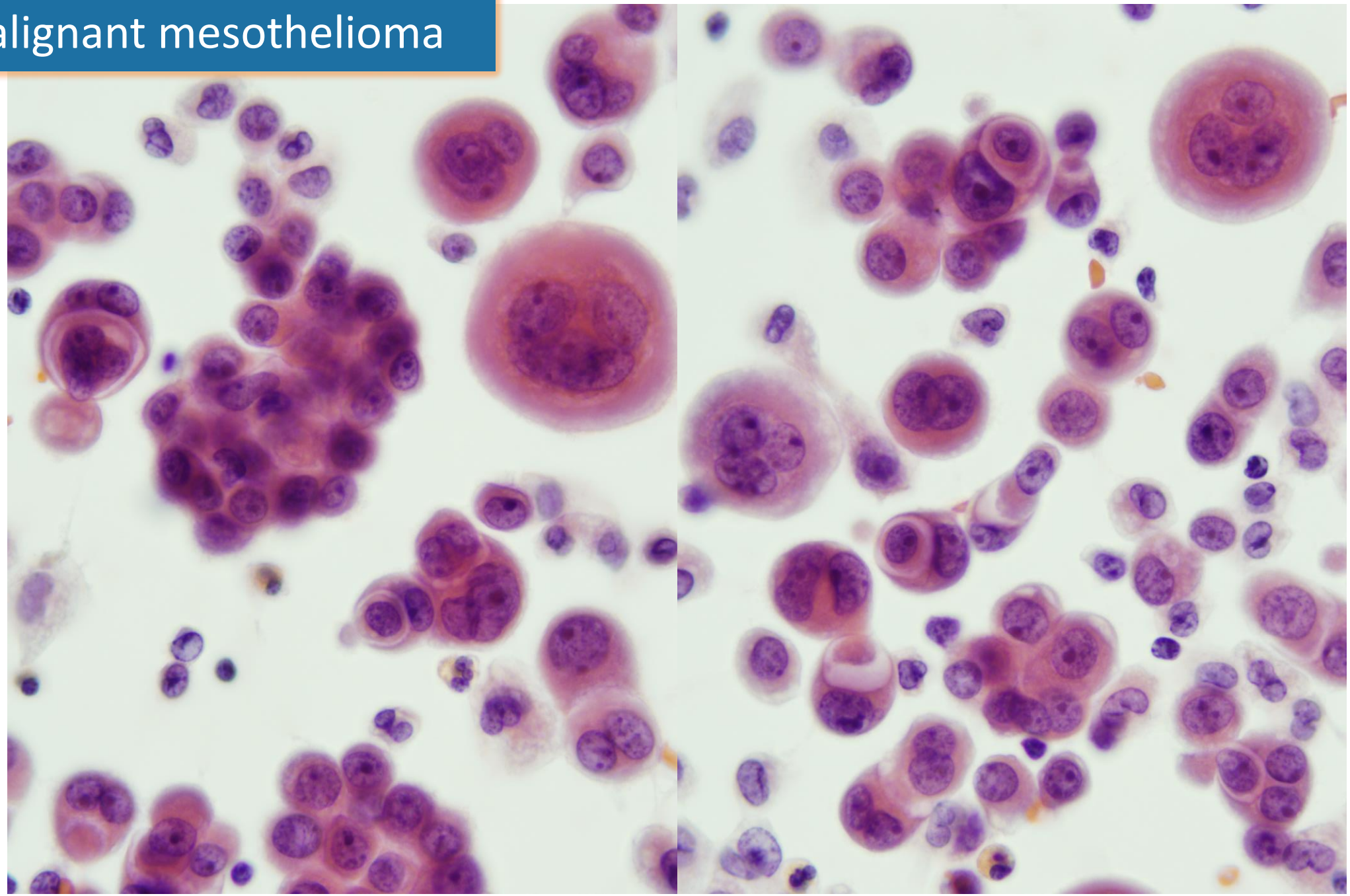

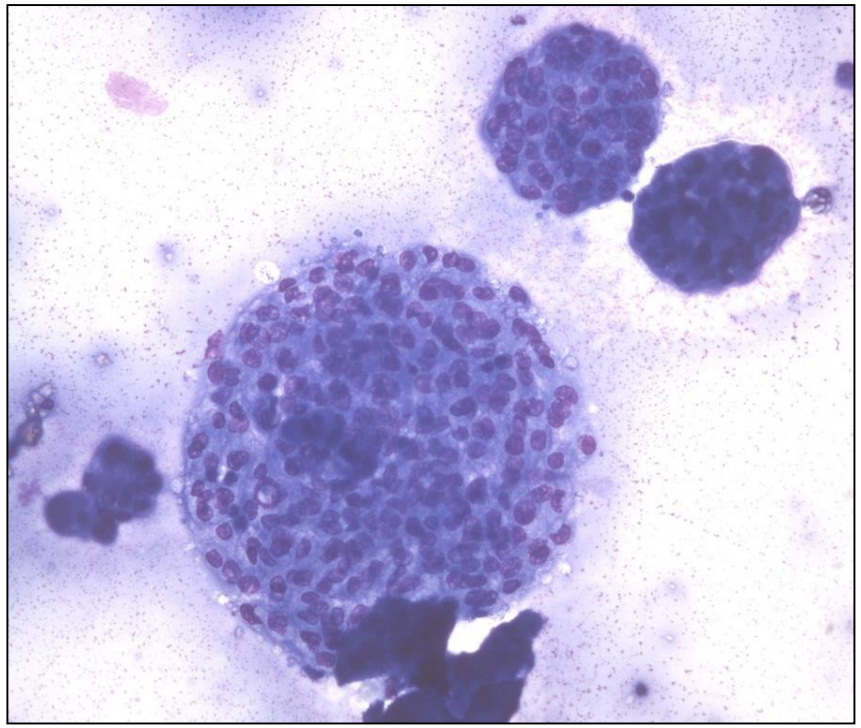

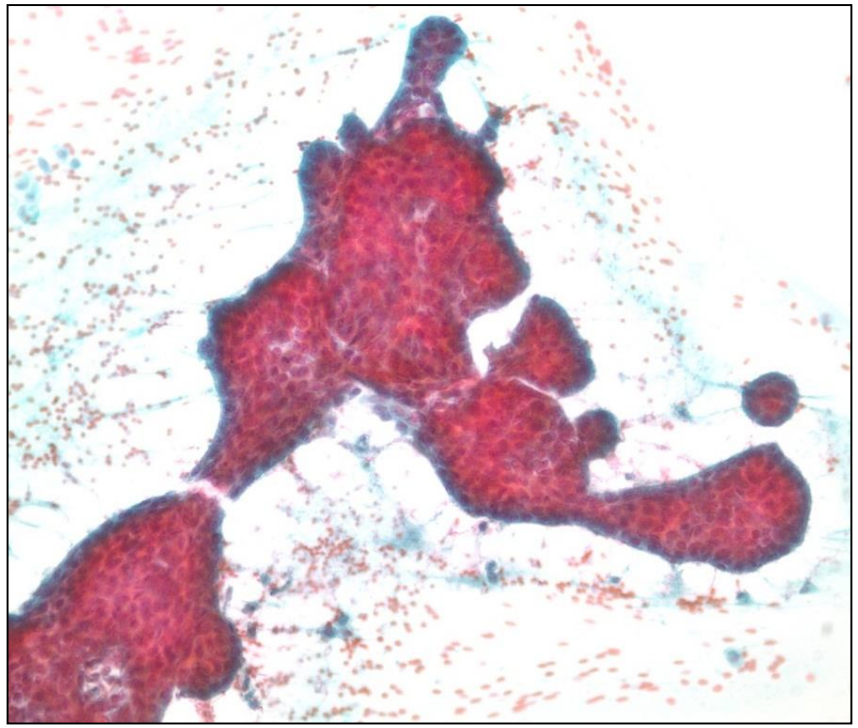

- “More and bigger cells in more and bigger clusters”

DeMay

- Complex groups, three dimentional aggregates
- Cell-in cell arrangements more common

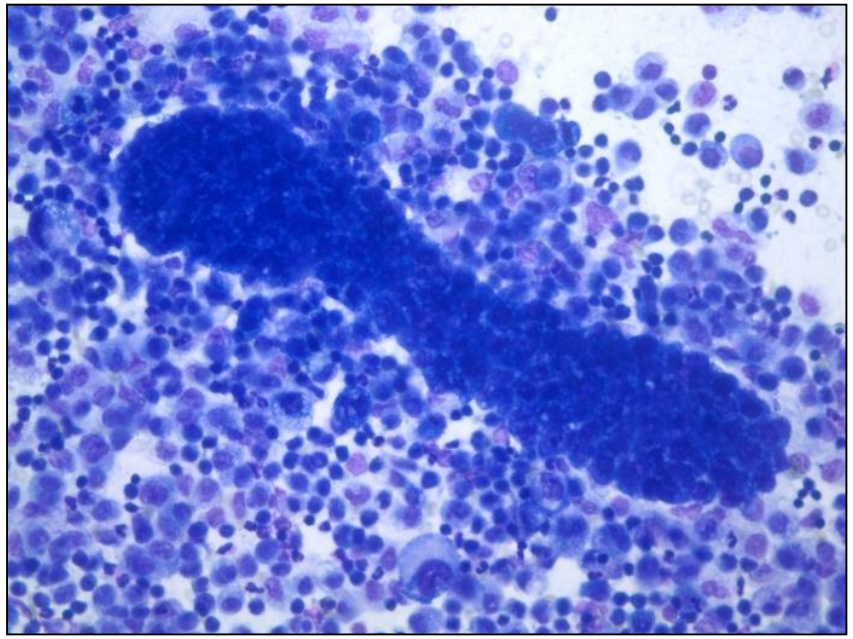

Malignant mesothelioma

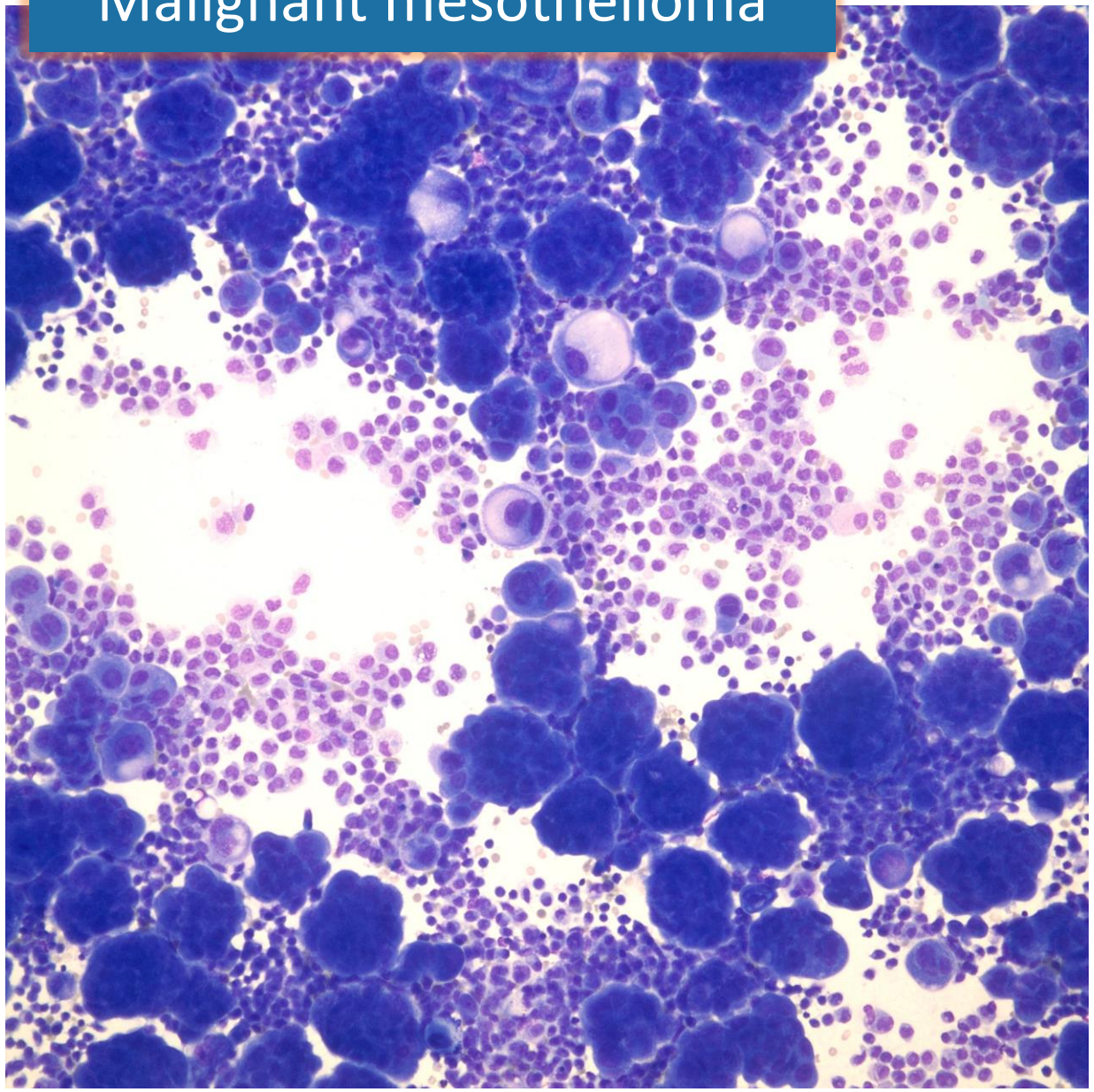

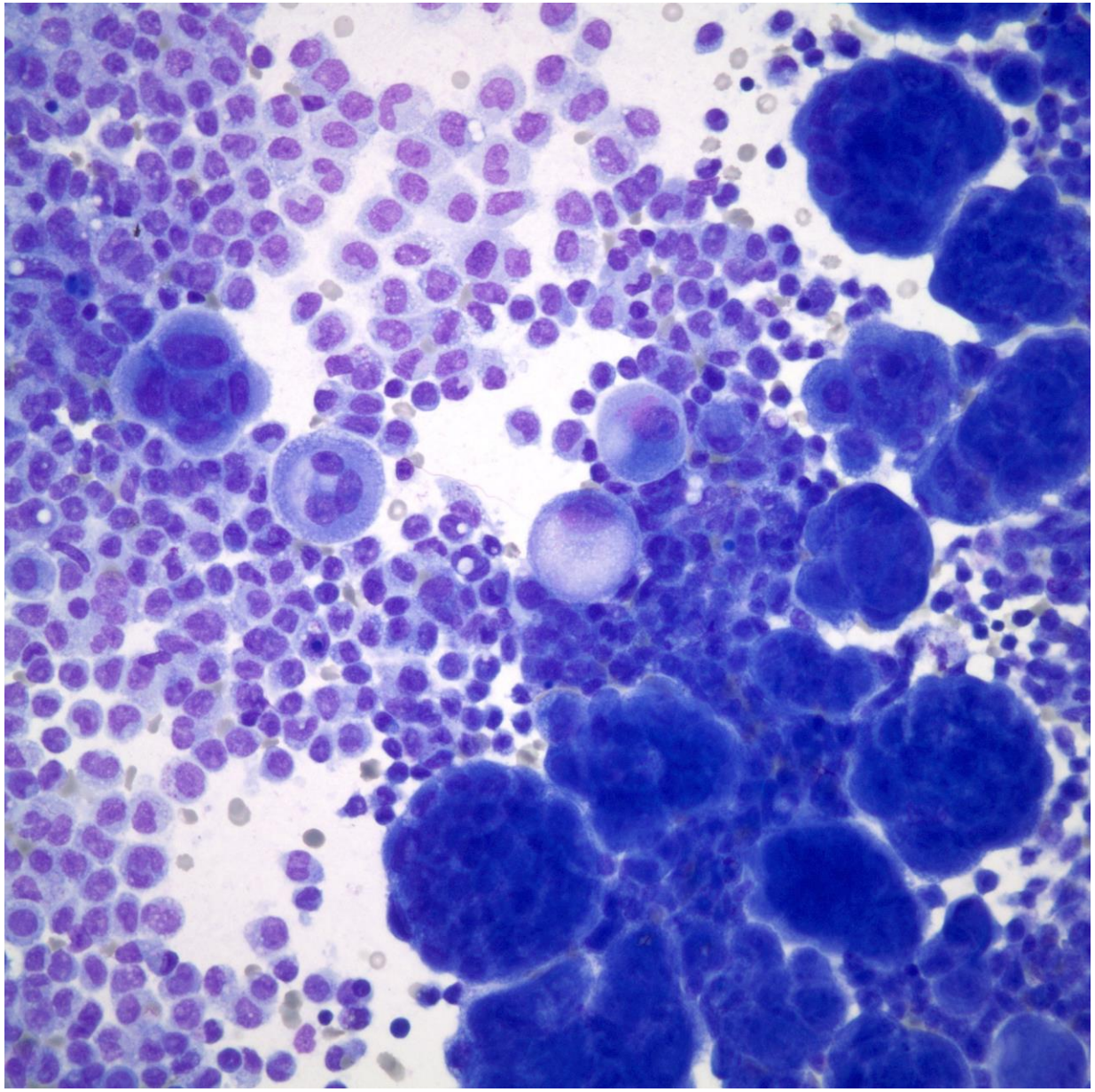

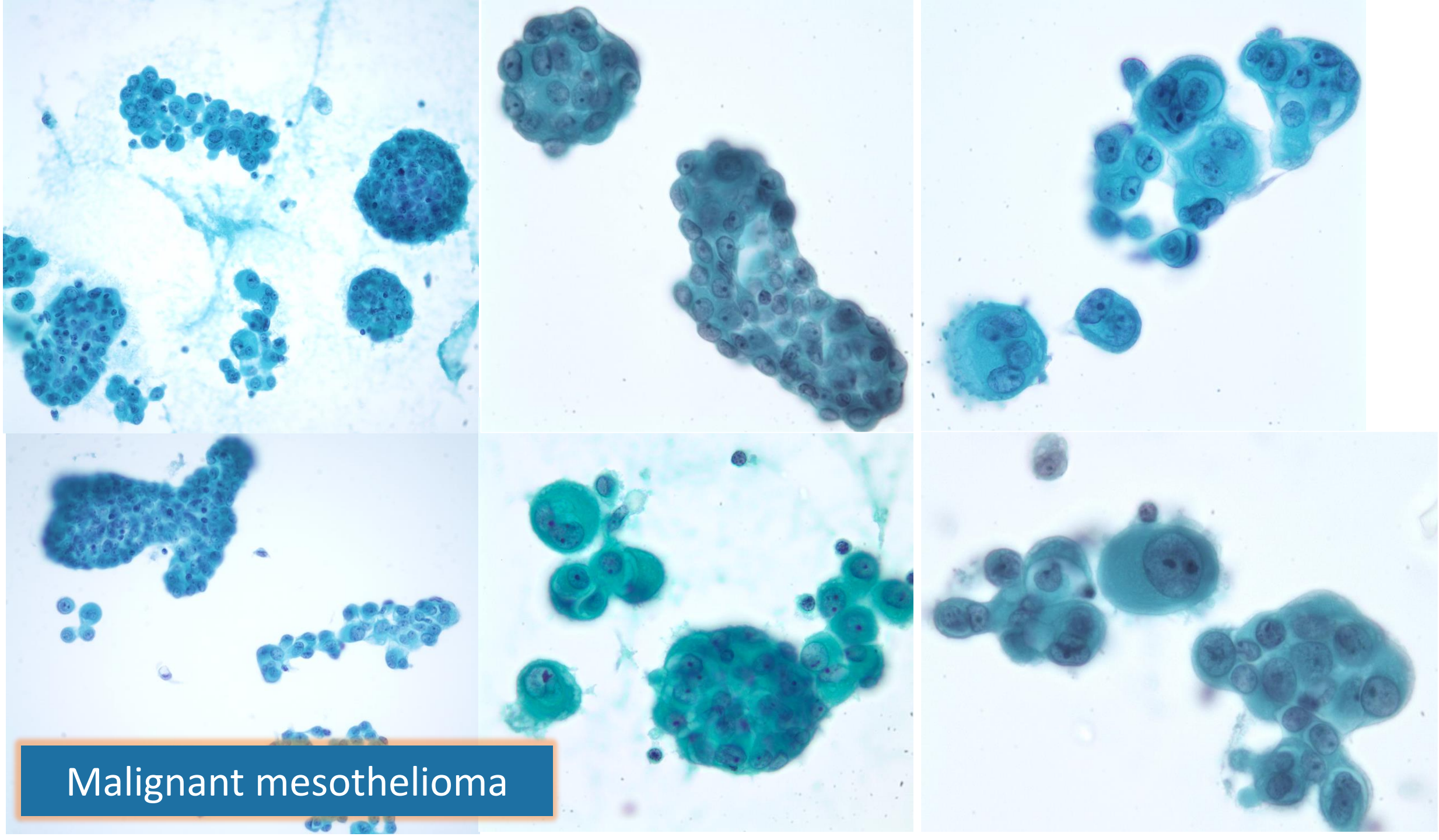

Malignant mesothelioma

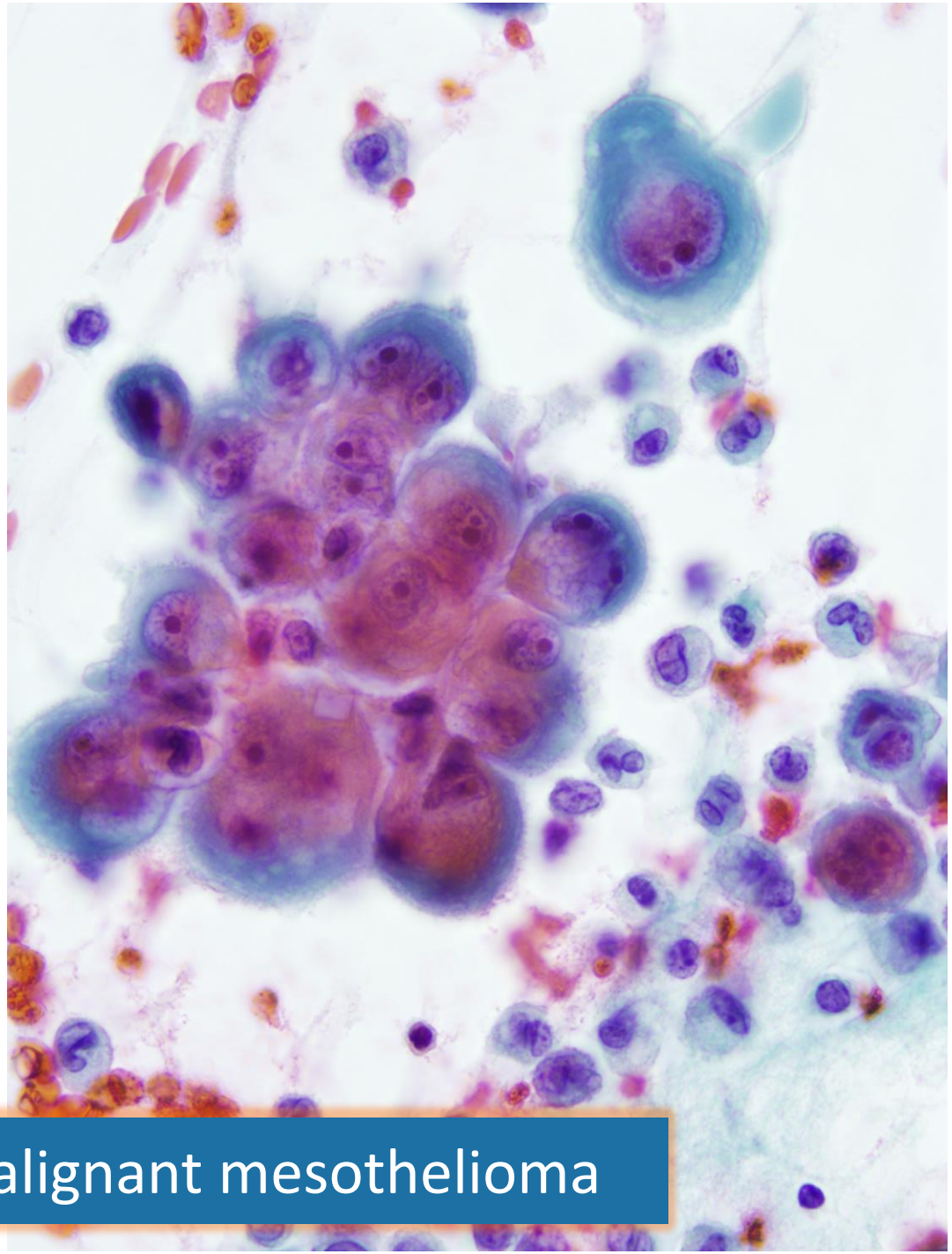

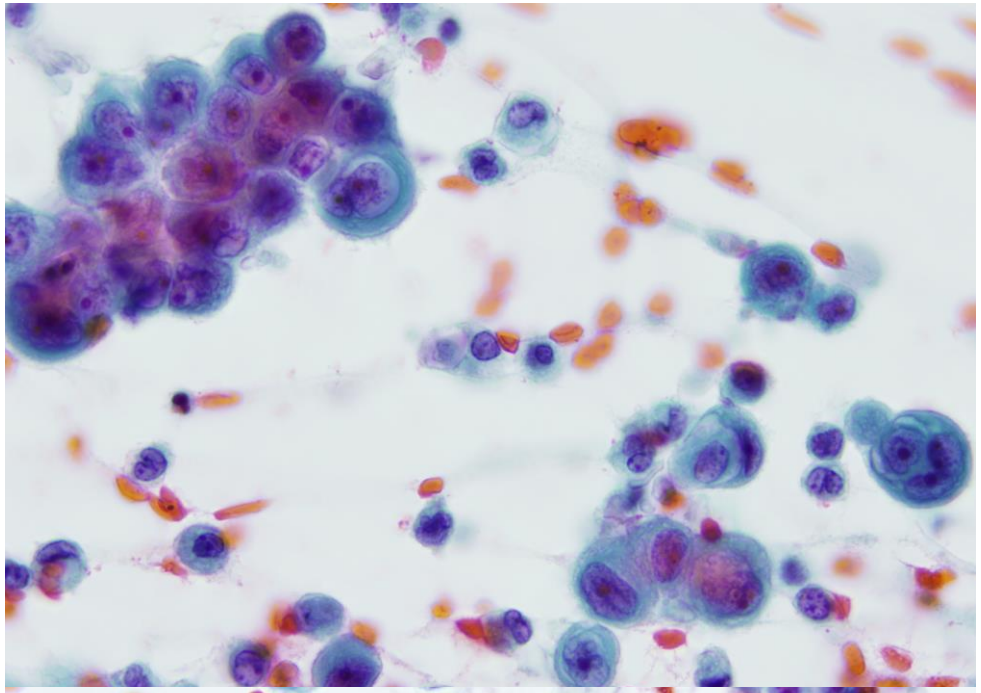

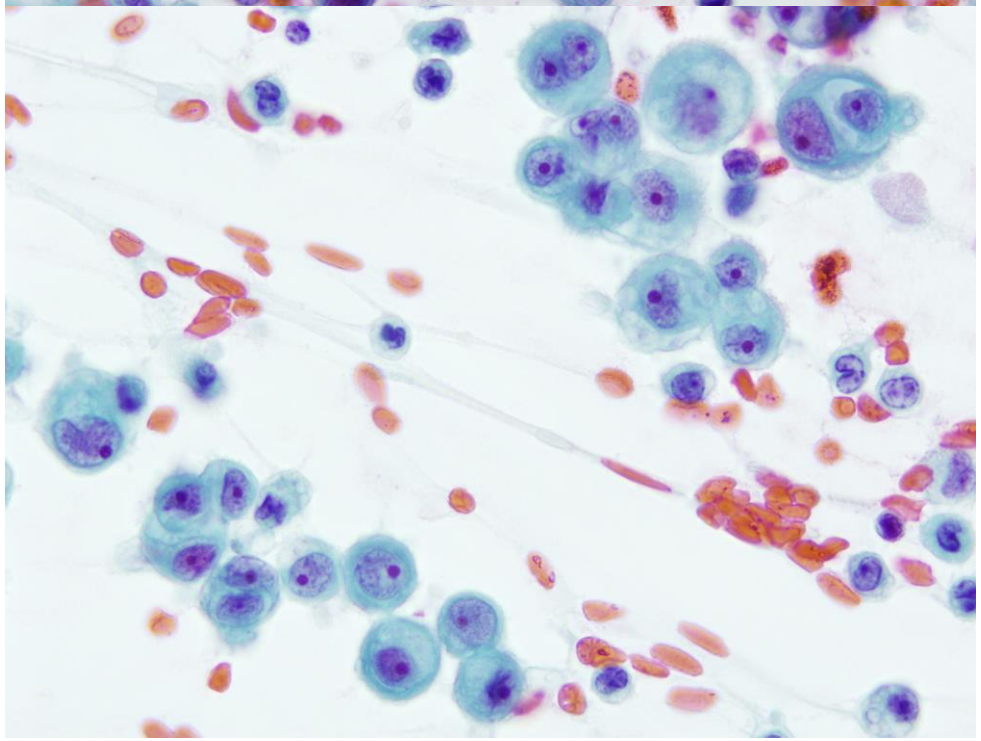

Malignant mesothelioma

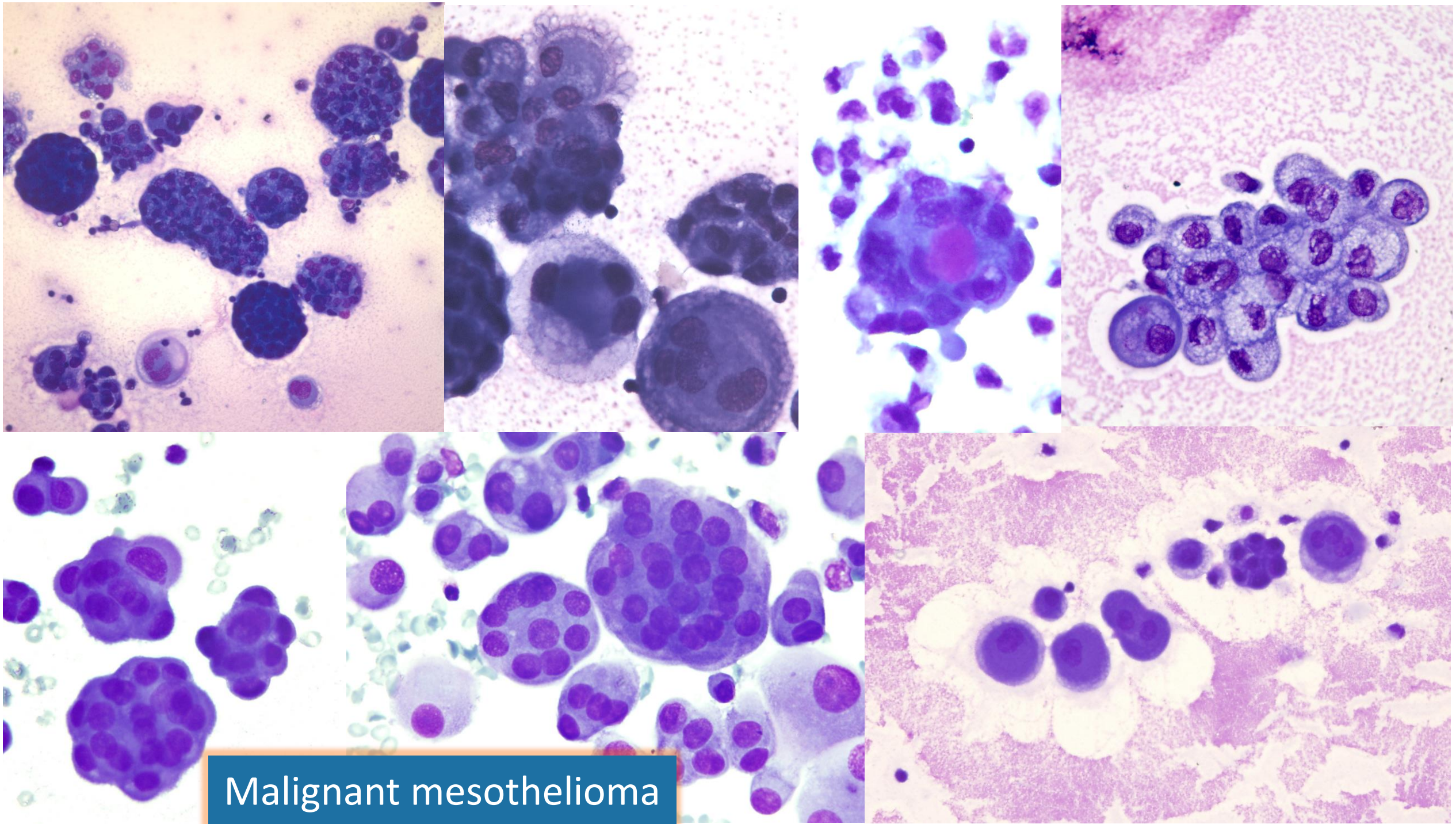

Malignant mesothelioma

Small Orangiophilic Squamous-Like Cells: An Underrecognized and Useful Morphological Feature for the Diagnosis of Malignant Mesothelioma in Pleural Effusion Cytology

Longwen Chen, MD, PhD[1,2]; Sonia Gatius Caldero, MD[1,3]; Stephen Gmitro, BS, CT(ASCP)[2]; Maxwell L. Smith, MD[1]; Giovanni De Petris, MD[1]; and Mathew A. Zarka, MD[1]

Cancer (Cancer Cytopathol) 2014;122:70-5.

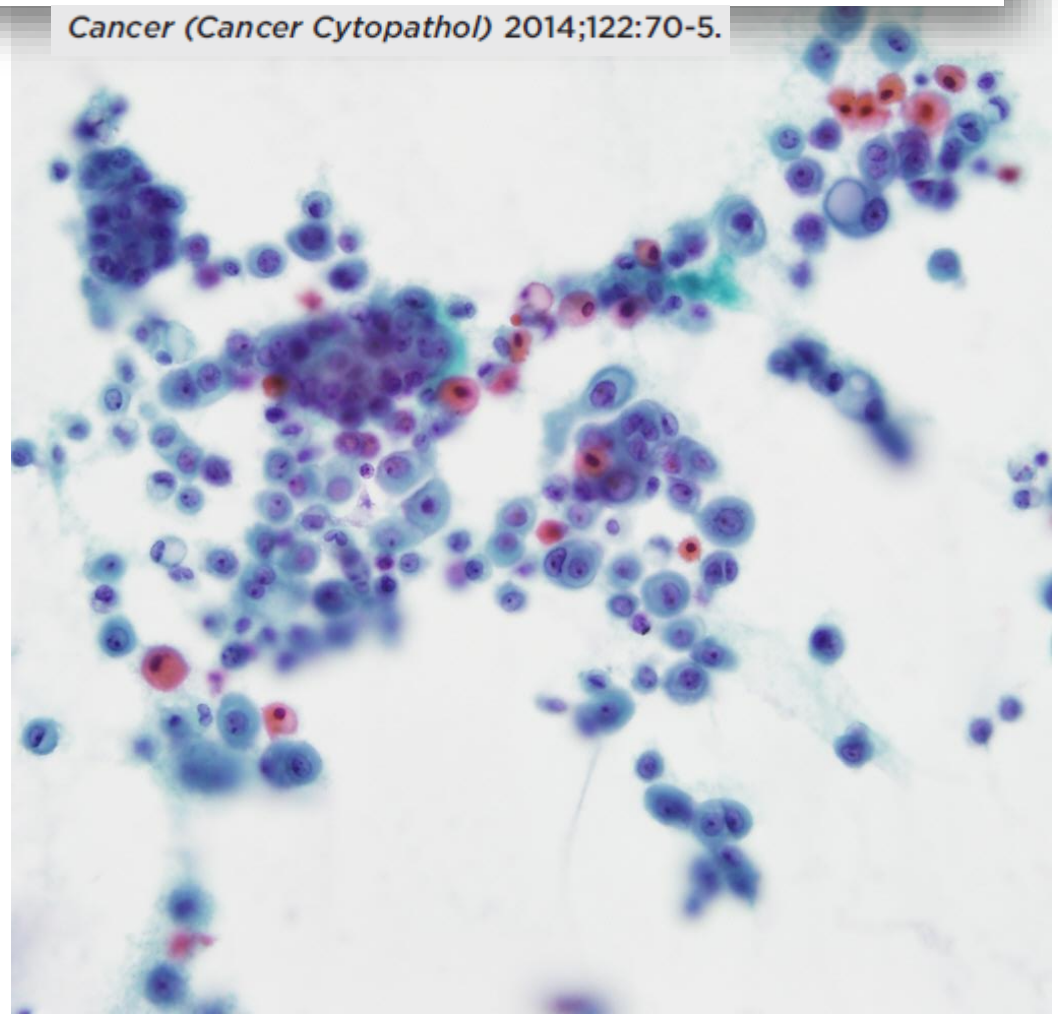

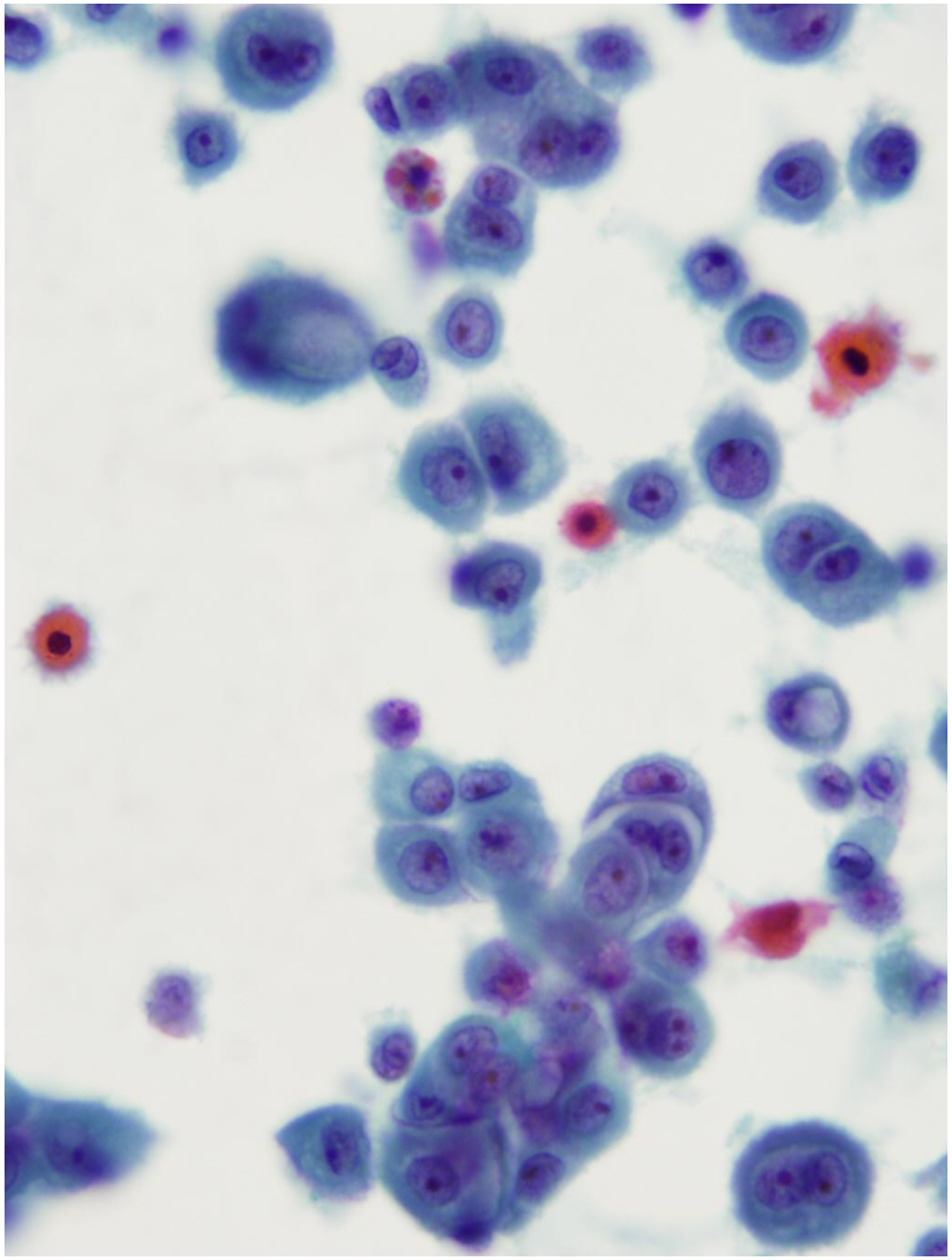

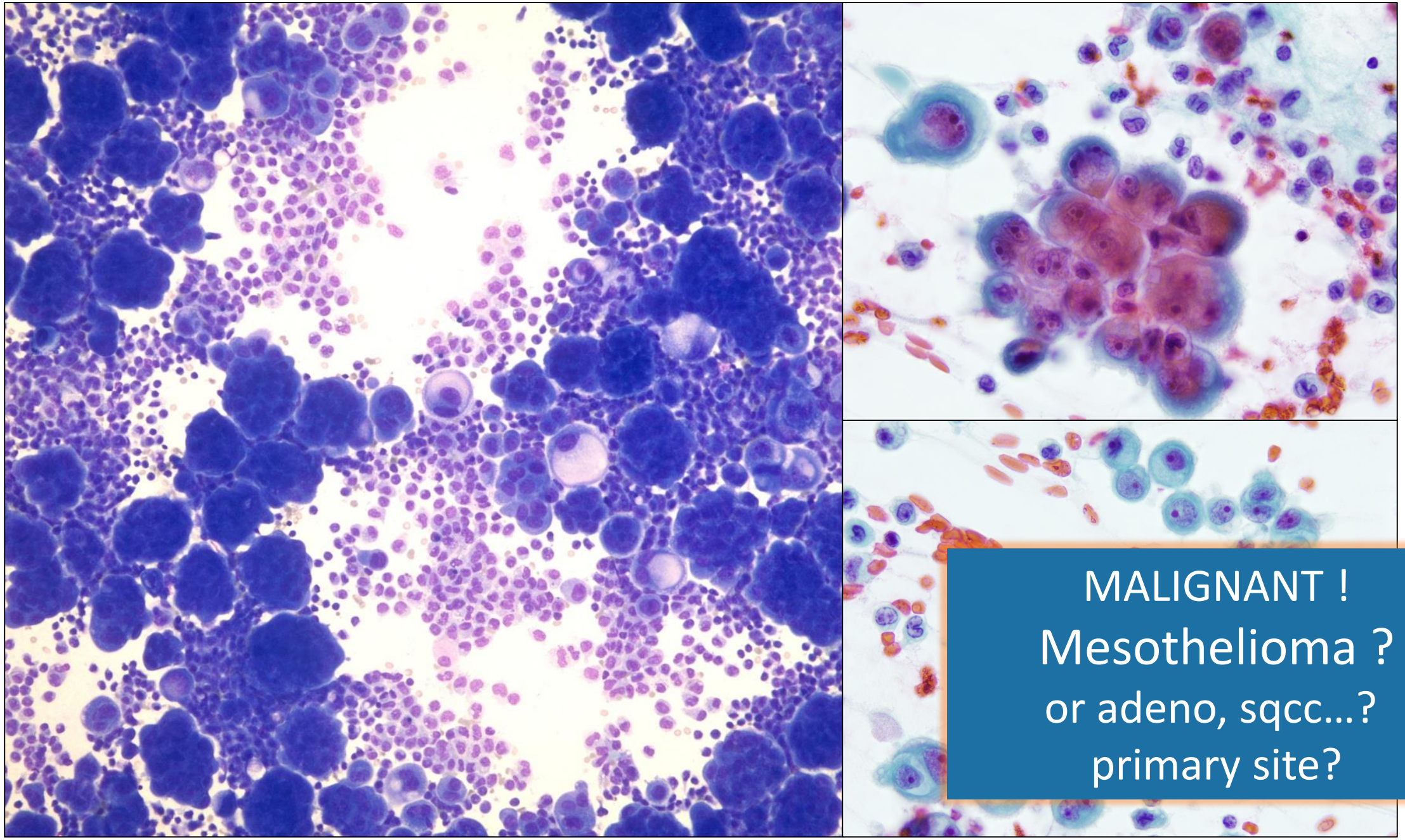

MALIGNANT !

Mesothelioma ?

or adeno, sqcc…?

primary site?

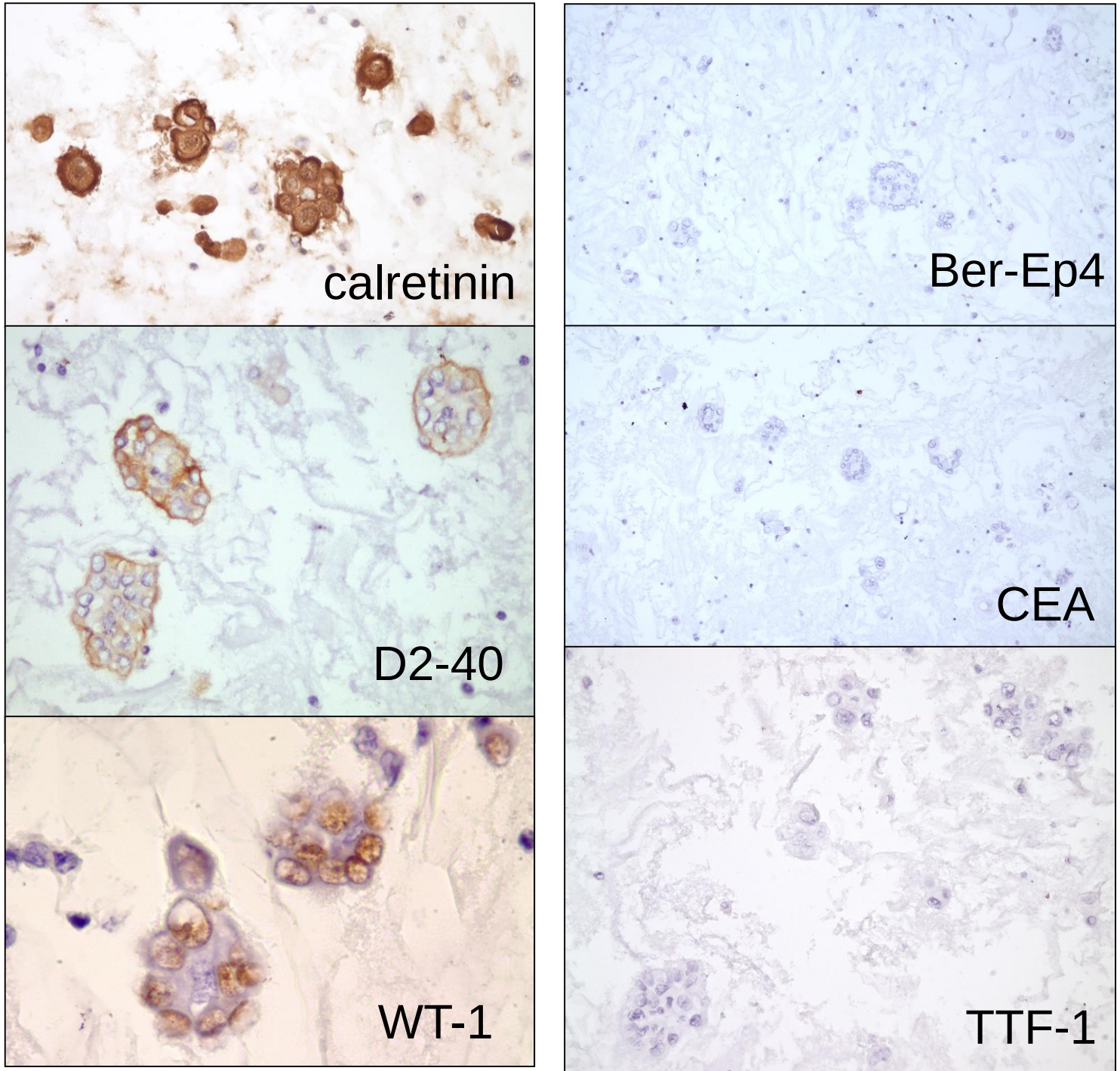

IHC

STATE OF THE ART: CONCISE REVIEW

IASLC

The 2015 World Health Organization Classification of Tumors of the Pleura: Advances since the 2004 Classification

CrossMark

Francoise Galateau-Salle, MD,[a,b] Andrew Churg, MD,[c] Victor Roggli, MD,[d] William D. Travis, MD,[e,*] on behalf of the World Health Organization Committee for Tumors of the Pleura

[a]*Department of Pathology, Centre Hospitalier Universitaire Caen, Caen, France*
[b]*Department of Biopathology, Centre Leon Berard, Lyon, France*
[c]*Department of Pathology, Vancouver General Hospital, Vancouver, British Columbia, Canada*
[d]*Department of Pathology, Duke University Medical Center, Durham, NC, USA*
[e]*Department of Pathology, Memorial Sloan Kettering Cancer Center, New York, NY, USA*

Journal of Thoracic Oncology Vol. 11 No. 2: 142-154, 2016

Table 2. Immunohistochemistry of Epithelioid Malignant Mesothelioma

Mesothelial Markers

Markers	Sensitivity	Specificity versus Lung Adenocarcinoma
Calretinin	> 90%	90%-95%
CK5/6	75%-100%	80%-90%
WT1	70%-95%	~100%
D2-40	90%-100%	85%

Adenocarcinoma (Positive Epithelial Markers)

Markers	Sensitivity	Specificity versus Malignant Mesothelioma
MOC31	95%-100%	85%-98%
BerEP4	95%-100%	74%-87%
BG8 (Lewis Y)	90%-100%	93%-97%
B72.3	25%-85%	> 95%
Monoclonal carcinoembryonic antigen	80%-100%	> 95%

Organ Specific - Lung

Markers	Sensitivity	Specificity versus Malignant Mesothelioma
TTF1 (8G7G3/1)	~80%	High
Napsin A	~80%	High

Organ Specific - Breast

Markers	Sensitivity	Specificity versus Malignant Mesothelioma
Estrogen receptor α	NA	NA
Progesterone receptor	NA	NA
GCDFP15	30%-40%	High
Mammaglobin	50%-85%	High

Organ Specific - Renal

Markers	Sensitivity	Specificity versus Malignant Mesothelioma
PAX8	70%-100%	Unknown
PAX2	80%	Unknown
RCC	≤ 85%	75%-90%
CD15 (LeuM1)	60%[a]	High

Adapted with permission from Travis et al.[1]

Malignant mesothelioma vs. metastatic adenocarcinoma

Marker	Target cell	Sensitivity	Specificity	Recommended
Calretinin	Mesothelium	Excellent	Good	Yes
WT-1	Mesothelium	Excellent	Variable	Depends on differential
D2-40/podoplanin	Mesothelium	Excellent	Good	Yes
Ber-EP4	Adenocarcinoma	Excellent	Good	Yes
MOC-31	Adenocarcinoma	Excellent	Good	Yes
B72-3	Adenocarcinoma	Good	Excellent	Yes
BG-8	Adenocarcinoma	Good	Good	Yes
CEA	Adenocarcinoma	Variable	Excellent	Depends on differential
Claudin-4	Adenocarcinoma	Excellent	Excellent	Yes

Modified from: Serous effusions, Ed. Davidson B, Firat P, Michael C, Springer, New York, 2012 – revised version for 2. edition

Malignant mesothelioma vs. metastatic adenocarcinoma

Marker	Target cell	Sensitivity	Specificity	Recommended
TTF-1	Lung adenocarcinoma	Good	Excellent	Yes
Napsin A	Lung adenocrcinoma	Good	Excellent	Yes
Mammaglobin	Breast carcinoma	Good	Excellent	Yes
ER	Breast/Gyn carcinoma	Good	Excellent	Yes
PAX 8	Serous carcinoma	Excellent	Excellent	Yes
PAX 2	Serous carcinoma	Moderate	Excellent	Yes
Cdx-2	Gastrointestinal	Good	Excellent	Yes
p40	Squamous carcinoma	Excellent	Excellent	Yes

Modified from: Serous effusions, Ed. Davidson B, Firat P, Michael C, Springer, New York, 2012 – revised version for 2. edition

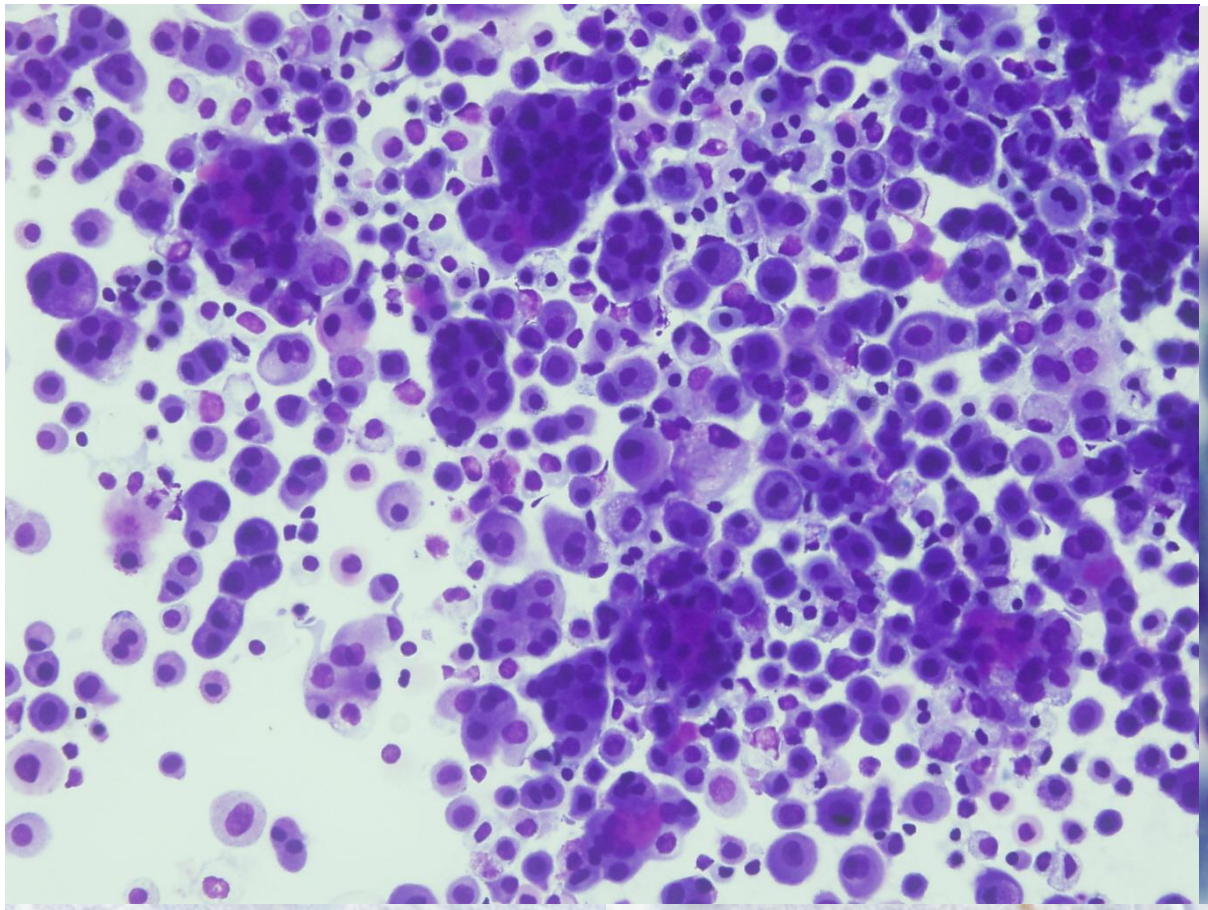

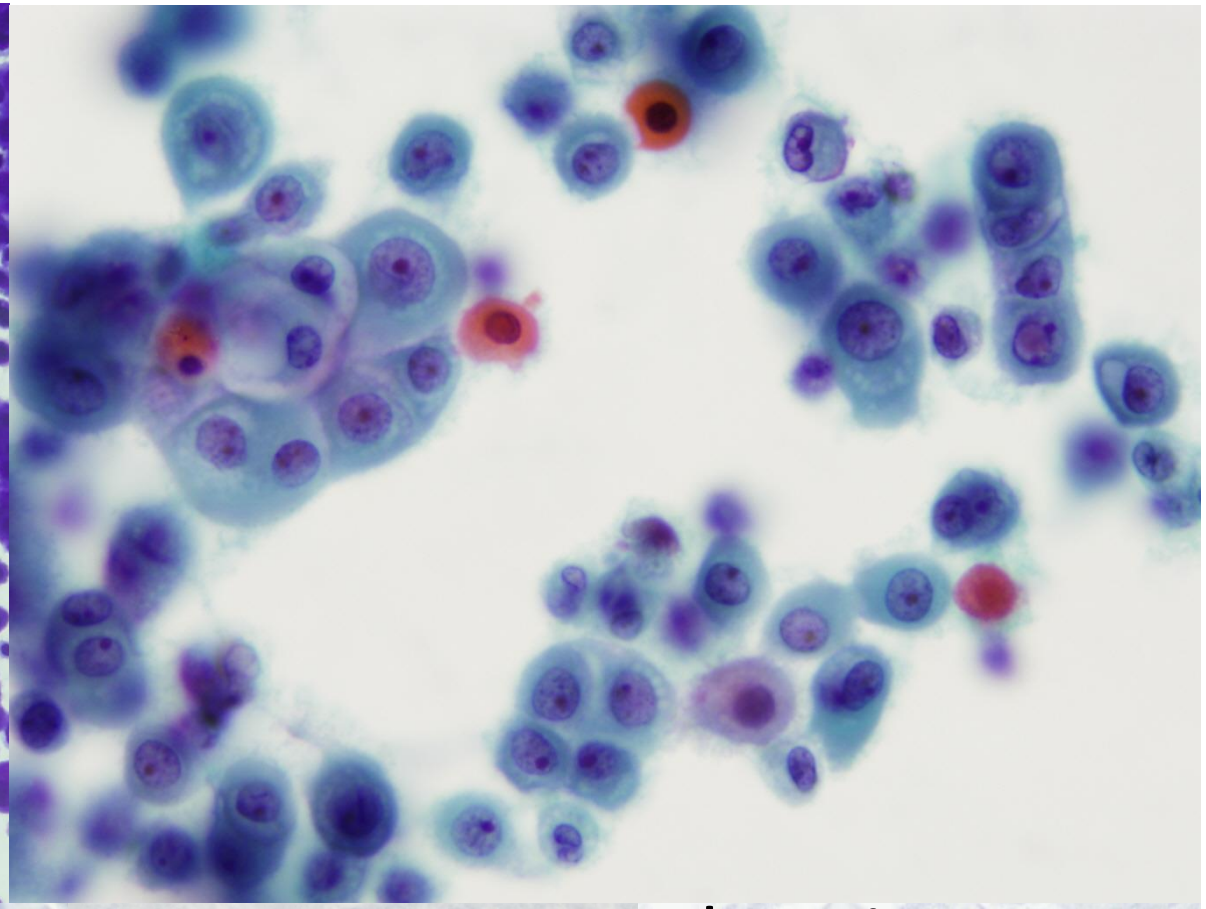

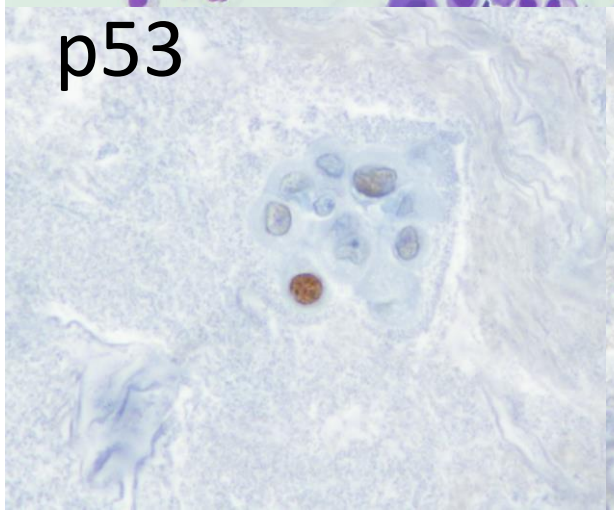
p53

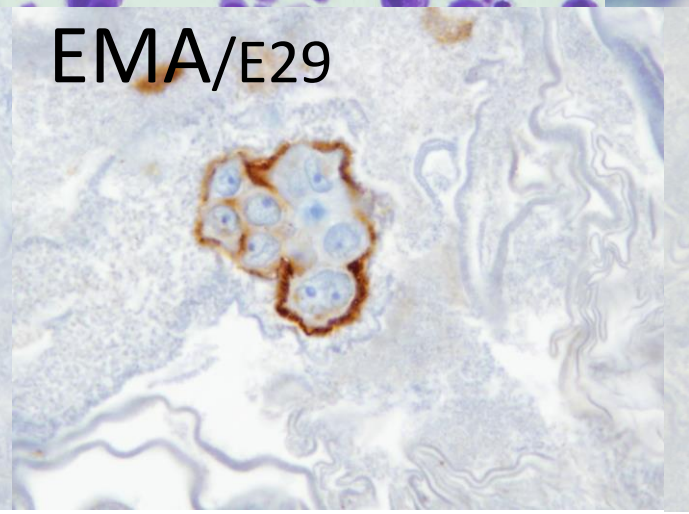
EMA/E29


Glut-1

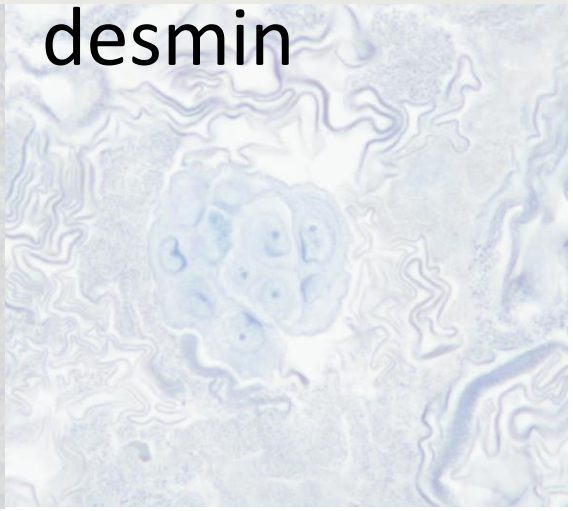
desmin

STATE OF THE ART: CONCISE REVIEW

IASLC

The 2015 World Health Organization Classification of Tumors of the Pleura: Advances since the 2004 Classification

CrossMark

Francoise Galateau-Salle, MD,[a,b] Andrew Churg, MD,[c] Victor Roggli, MD,[d] William D. Travis, MD,[e,*] on behalf of the World Health Organization Committee for Tumors of the Pleura

[a]*Department of Pathology, Centre Hospitalier Universitaire Caen, Caen, France*
[b]*Department of Biopathology, Centre Leon Berard, Lyon, France*
[c]*Department of Pathology, Vancouver General Hospital, Vancouver, British Columbia, Canada*
[d]*Department of Pathology, Duke University Medical Center, Durham, NC, USA*
[e]*Department of Pathology, Memorial Sloan Kettering Cancer Center, New York, NY, USA*

‘ …. p53, EMA, Glut-1, IMP-3, desmin- all of them show overlap between benign and malignant, and at best they provide statistical differences in large series but are of little value in individual cases…. ’

Journal of Thoracic Oncology Vol. 11 No. 2: 142-154, 2016

New Markers for Separating Benign From Malignant Mesothelial Proliferations

Are We There Yet?

Andrew Churg, MD; Brandon S. Sheffield, MD; Francoise Galateau-Salle, MD

(Arch Pathol Lab Med. 2016;140:318–321)

- Deletion of the 9p21 region / loss of p16 (CDKN2A) and its splice variant p14, p15 (CDKN2B), and methylthioadenosine phosphorylase (MTAP)
- BRCA1-associated protein 1 (BAP1) mutations (biallelic mutations result in loss of immunhistochemical staining)

‘ .. homozygous loss of p16 by FISH or loss of BAP1 by immunhistochemistry is never seen in benign

High specificity

‘ .. both markers are deleted/lost in a proportion omas’

Low sensitivity

‘ .. crucial to confirm, that the process in question is mesothelial before proceeding to BAP1 testing and/or p16 FISH ’

Fluorescence *In Situ* Hybridization in the Definitive Diagnosis of Malignant Mesothelioma in Effusion Cytology

Spasenija Savic, MD; Noreli Franco, PhD; Bruno Grilli; Audrey de Vito Barascud; Michelle Herzog; Beata Bode, MD; Heinz Loosli, MD; Peter Spieler, MD; René Schönegg, MD; Inti Zlobec, PhD; Douglas P. Clark, MD; James G. Herman, MD; and Lukas Bubendorf, MD

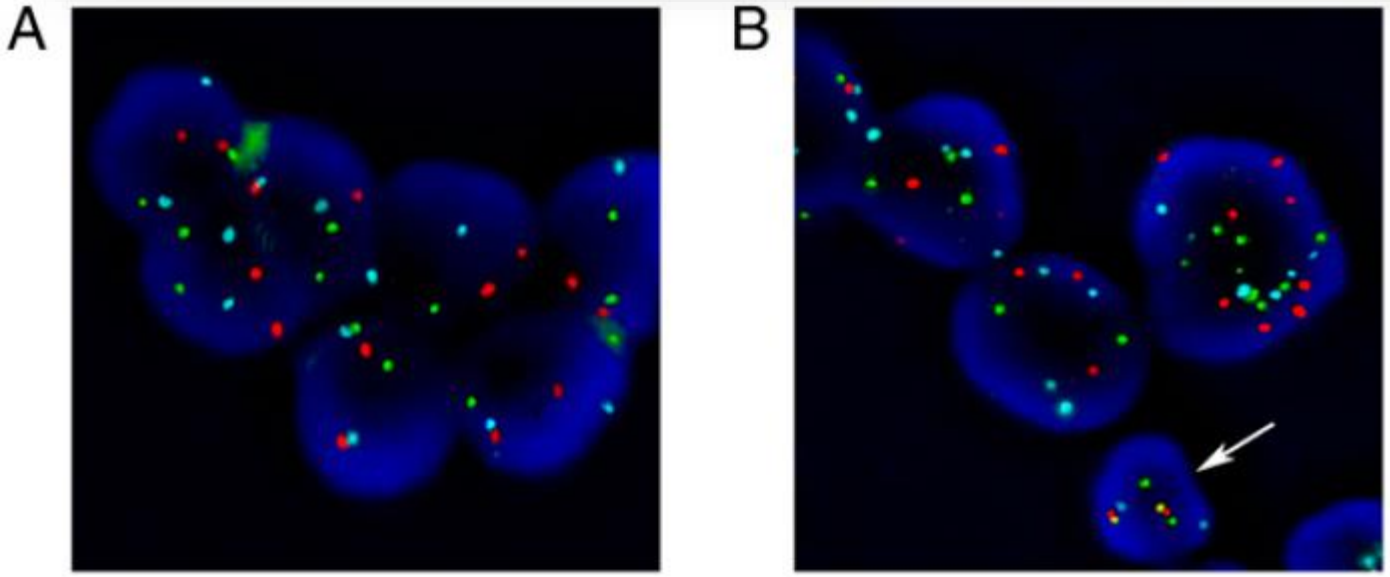

Sensitivity, specificity, and positive and negative predictive values for detection of MM by FISH were 79%, 100%, 100%, and 72%,

CHEST / 138 / 1 / JULY, 2010

The Diagnostic Utility of *p16* FISH and GLUT-1 Immunohistochemical Analysis in Mesothelial Proliferations

Sara E. Monaco, MD,[1] Yongli Shuai, MS,[2] Mona Bansal, MD,[1] Alyssa M. Krasinskas, MD,[1] and Sanja Dacic, MD, PhD[1]

Cyto+Bx (TMA)
Homozygote deletion

Table 2
Summary of GLUT-1 Immunohistochemical Results and *p16* FISH Results in 154 Cases of Reactive, Atypical, and Malignant Mesothelial Proliferations*

			Malignant Mesothelioma		
	Benign/Reactive (n = 70)	Atypical (n = 16)	Total (n = 68)	Pleura (n = 27)	Peritoneum (n = 41)
GLUT-1 immunohistochemical analysis					
0	65 (93)	13 (81)	41 (60)	12 (44)	29 (71)
1+	5 (7)	1 (6)	17 (25)	11 (41)	6 (15)
2+	0 (0)	0 (0)	6 (9)	3 (11)	3 (7)
3+	0 (0)	2 (13)	4 (6)	1 (4)	3 (7)
p16 FISH					
Negative for deletion	70 (100)	9 (56)	28 (41)	8 (30)	20 (49)
Positive for deletion	0 (0)	7 (44)	40 (59)	19 (70)	21 (51)

FISH, fluorescence in situ hybridization.

GLUT-1 (sensitivity, 40%; specificity, 93%).
p16 (sensitivity, 59%; specificity, 100%)

Am J Clin Pathol 2011;135:619-627

Utility of BAP1 Immunohistochemistry and p16 (CDKN2A) FISH in the Diagnosis of Malignant Mesothelioma in Effusion Cytology Specimens

Harry C. Hwang, MD, Brandon S. Sheffield, MD,†‡ Stephanie Rodriguez, HT, MB, ASCP,* Kim Thompson, ASCP, QIHC,* Christopher H. Tse, MBBS,* Allen M. Gown, MD,* and Andrew Churg, MD†‡*

- BAP1 loss alone: 10/15 (67%) biopsies and 10/ 15 (67%) cytology specimens.
- Homozygous deletion of p16 by FISH: 12/15 (80%) biopsy specimens and 8/11 (73%) cytology specimens.
- All mesothelioma biopsy/cytology pairs showed the same pattern of BAP1 or p16 retention or loss in the biopsy and cytology specimens

(Am J Surg Pathol 2016;40:120–126)

BAP1 Immunostain and *CDKN2A* (p16) FISH Analysis

Clinical Applicability for the Diagnosis of Malignant Mesothelioma in Effusions

Ann E. Walts, M.D.,[1*] Kenzo Hiroshima, M.D., Ph.D.,[2]
Stephanie M. McGregor, M.D., Ph.D.,[3] Di Wu, Ph.D.,[2]
Aliya N. Husain, M.D.,[3] and Alberto M. Marchevsky, M.D.[1]

Cut off:

- absence of nuclear immunoreactivity in >50% of the atypical mesothelial cells
- preserved immunoreactivity in internal controls (lymphocytes, histiocytes, and/ or nonatypical mesothelial cells).

Table II. Malignant Mesothelioma (MM) Effusions

	MM correctly diagnosed	*Reactive correctly diagnosed*	*Sensitivity*	*Specificity*
BAP1 IHC all cases (n = 67)	53.1% (17/32)	85.7% (30/35)	53.1%	85.7%
CDKN2A(p16) FISH (n = 38)	41.2% (7/17)	100% (21/21)	41.2%	100.0%
BAP1 IHC and *CDKN2A*(p16) FISH (n = 38)				
BAP1 IHC	41.2% (7/17)	81.0% (17/21)	41.2%	81.0%
CDKN2A(p16) FISH	41.2% (7/17)	100% (21/21)	41.2%	100.0%
BAP1 IHC or *CDKN2A*(p16) FISH	64.7% (11/17)	100% (21/21)	64.7%	100.0%
BAP1 IHC and *CDKN2A*(p16) FISH	17.6% (3/17)	81.0% (17/21)	17.6%	81.0%

Diagn. Cytopathol. 2016;44:599–606.

Reactive

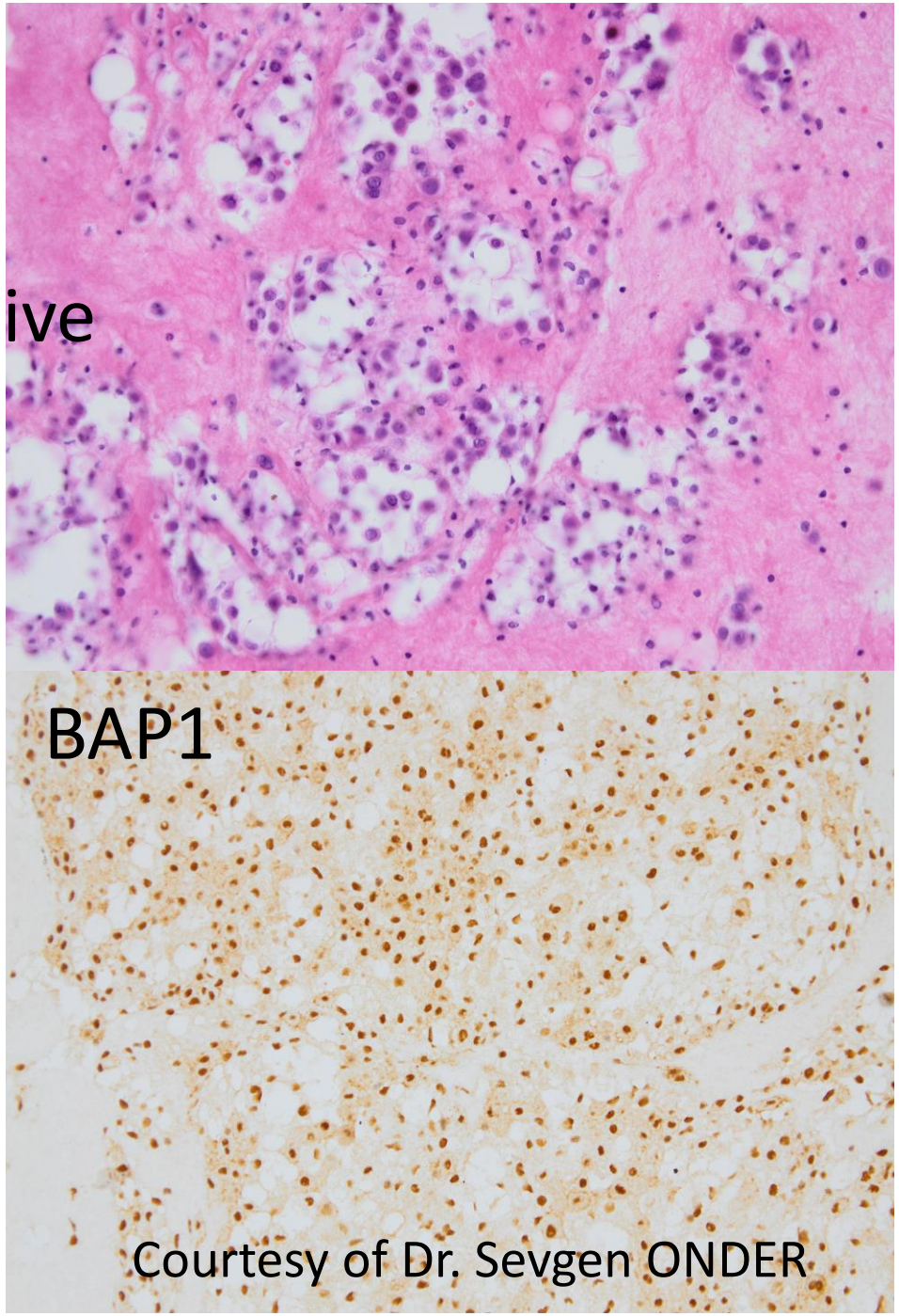

Courtesy of Dr. Sevgen ONDER

Mesothelioma

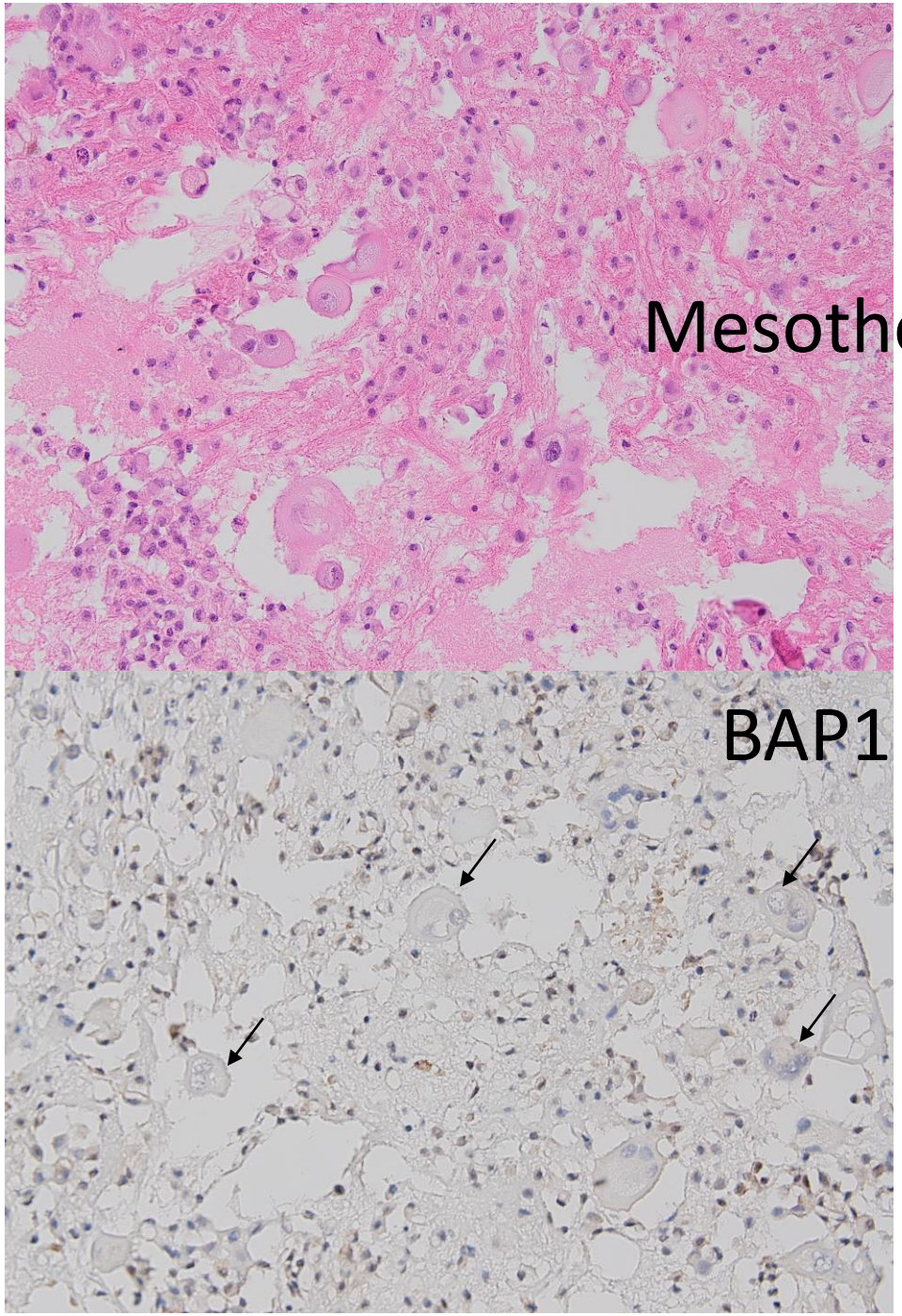

Review

ACTA CYTOLOGICA

Acta Cytologica 2015;59:2–16
DOI: 10.1159/000377697

Received: December 23, 2014
Accepted: December 29, 2014
Published online: March 24, 2015

Guidelines for the Cytopathologic Diagnosis of Epithelioid and Mixed-Type Malignant Mesothelioma

Complementary Statement from the International Mesothelioma Interest Group, Also Endorsed by the International Academy of Cytology and the Papanicolaou Society of Cytopathology

Anders Hjerpe[a] Valeria Ascoli[b] Carlos W.M. Bedrossian[c] Mathilde E. Boon[d] Jenette Creaney[e] Ben Davidson[f] Annika Dejmek[g] Katalin Dobra[a] Ambrogio Fassina[h] Andrew Field[i] Pinar Firat[j] Toshiaki Kamei[k] Tadao Kobayashi[l] Claire W. Michael[m] Sevgen Önder[n] Amanda Segal[o] Philippe Vielh[p]

[a]Division of Clinical Pathology/Cytology, Department of Laboratory Medicine, Karolinska Institutet, Karolinska University Hospital Huddinge, Huddinge, Sweden; [b]Department of Radiological, Oncological and Pathological Sciences, Sapienza University, Rome, Italy; [c]Rush University Medical College, Chicago, Ill., USA; [d]Leiden Cytology and Pathology Laboratory, Lieveren, The Netherlands; [e]National Centre for Asbestos Related Disease, School of Medicine and Pharmacology, University of Western Australia, QEII Medical Centre, Perth, W.A., Australia; [f]Department of Pathology, The Norwegian Radium Hospital, Oslo University Hospital, Oslo, Norway; [g]Department of Laboratory Medicine in Malmö, Lund University, Malmö University Hospital, Malmö, Sweden; [h]Department of Medicine, University of Padova, Padova, Italy; [i]Department of Anatomical Pathology, St Vincents Hospital, Sydney, N.S.W., Australia; [j]Istanbul University, Istanbul Faculty of Medicine, Istanbul, Turkey; [k]Division of Pathology, Yamaguchi Grand Medical Center, Hofu, and [l]Cancer Education and Research Center, Osaka University Graduate School of Medicine, Osaka, Japan; [m]Case Western Reserve University/University Hospitals Case Medical Center, Department of Pathology, Cleveland, Ohio, USA; [n]Hacettepe University, Faculty of Medicine, Department of Pathology, Ankara, Turkey; [o]Department of Tissue Pathology, PathWest Laboratory Medicine WA, QE2 Medical Centre, Perth, W.A., Australia; [p]Department of Biopathology, Gustave Roussy Comprehensive Cancer Center, Villejuif, France

General Recommendations

The cytological diagnosis of MM in effusions should fulfil one of the following criteria:

- Indisputable malignant cells on cytomorphological criteria which demonstrate a mesothelial phenotype, which should be verified by ancillary techniques;
- Cytomorphological features which are not unequivocally malignant, but ancillary techniques confirm malignancy and a mesothelial phenotype.

When evaluated in clinical practice, these two options can make the specific diagnosis of MM with a high degree of sensitivity and accuracy [5], while noting that the diagnosis of sarcomatoid MM can rarely be established by effusion cytology.

Acta Cytologica 2015;59:2–16

ABOUT LIVING - I

Living is no laughing matter:
you must live with great seriousness
like a squirrel, for example-
I mean without looking for something beyond and above living,
I mean living must be your whole occupation.

I mean, you must take living so seriously
that even at seventy, for example, you'll plant olive trees-
and not for your children, either,
but because although you fear death you don't believe it,
because living, I mean, weighs heavier.

Nazim Hikmet

Living is no laughing matter:
you must take it seriously,
so much so and to such a degree
that, for example, your hands tied behind your back,
your back to the wall,
or else in a laboratory
in your white coat and safety glasses,
you can die for people-
even for people whose faces you've never seen,
even though you know living is
the most real, the most beautiful thing.



Şukru MUNOGLU, Nesimi BUYUKBABANI

PLEA

This country shaped like the head of a mare
Coming full gallop from far off Asia
To stretch into the Mediterranean
THIS COUNTRY IS OURS.

Bloody wrists, clenched teeth, bare feet,
Land like a precious silk carpet
THIS HELL, THIS PARADISE IS OURS.

Let the doors be shut that belong to others
Let them never open again
Do away with the enslaving of man by man
THIS PLEA IS OURS.

To live! Like a tree alone and free
Like a forest in brotherhood
THIS YEARNING IS OURS.

Nazim HIKMET

Şukru MUNOGLU, Nesimi BUYUKBABANI