LES DIFFICULTÉS DU NIFT-P EN CYTOPATHOLOGIE ET L'AIDE DU MOLÉCULAIRE

Beatrix Cochand-Priollet

beatrix.cochand-priollet@aphp.fr

Hôpitaux Universitaires Paris Centre
COCHIN
BROCA
HÔTEL-DIEU

PARIS DESCARTES

The New York Times

Health

SUBSCRIBE | LOG IN

It's Not Cancer: Doctors Reclassify a Thyroid Tumor

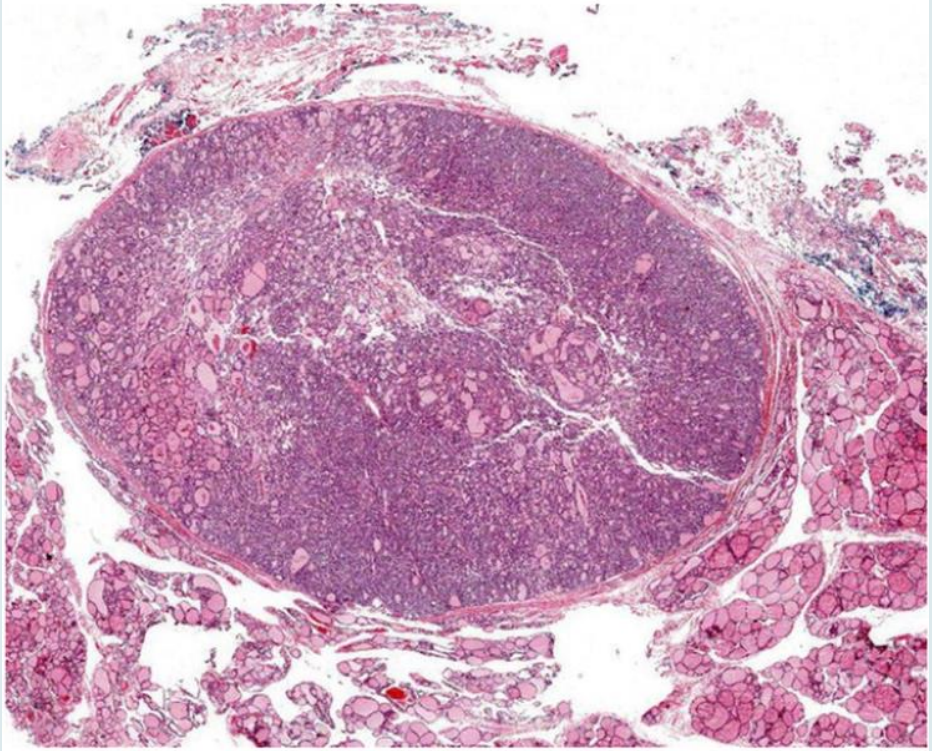

A noninvasive follicular thyroid neoplasm with papillary-like nuclear features, or Niftp, a type of tumor that was previously considered a kind of cancer, but has been downgraded by a panel of doctors.
YURI NIKIFOROV

By GINA KOLATA
APRIL 14, 2016

An international panel of doctors has decided that a type of tumor that was classified as a cancer is not a cancer at all.

ENDOCRINOLOGUES
RADIOLOGUES
PATHOLOGISTES
CYTOPATHOLOGISTES

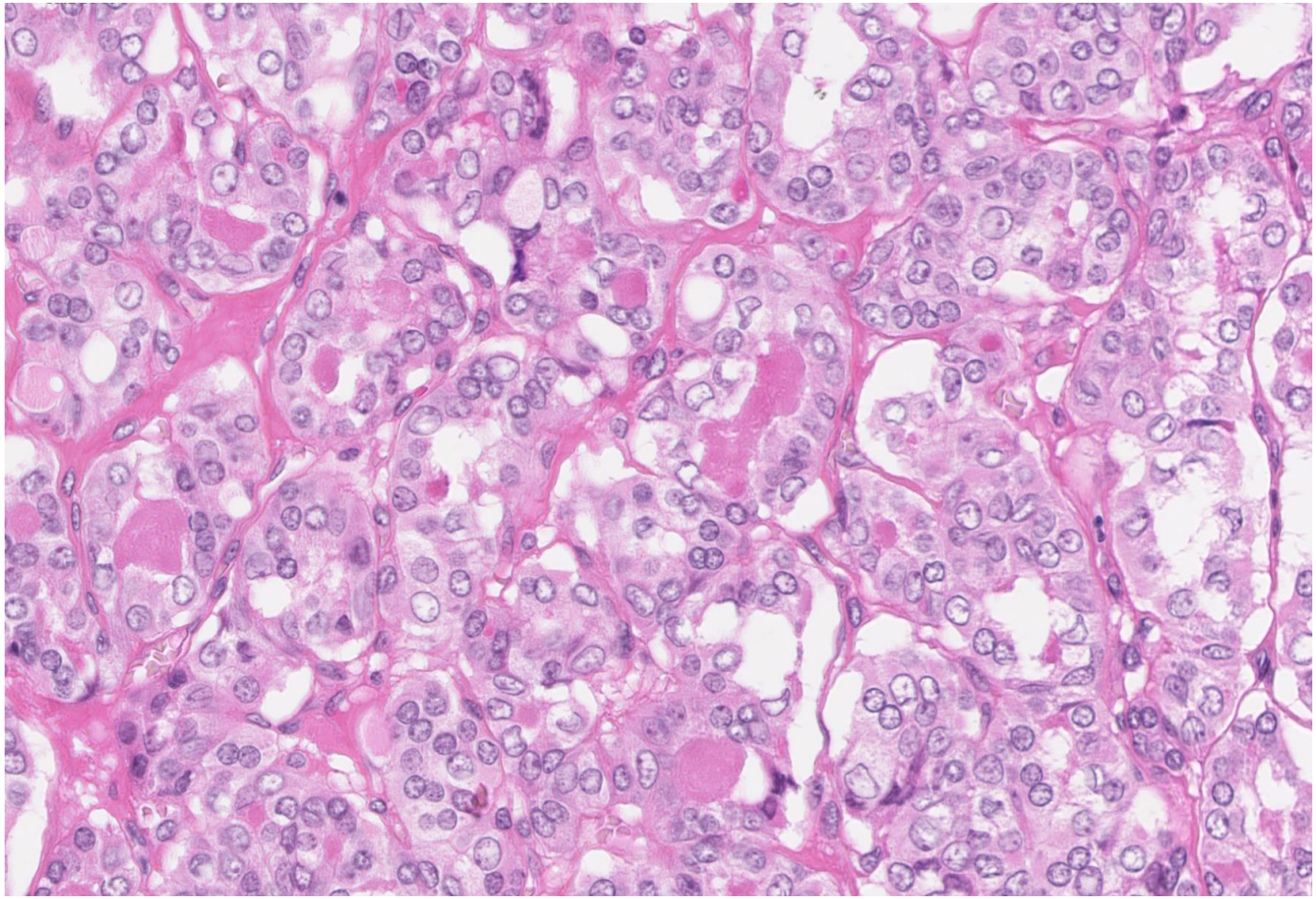

ATYPIES CYTO-NUCLÉAIRES

ARCHITECTURE VÉSICULAIRE

TABLE 2. FINE-NEEDLE ASPIRATION DIAGNOSTIC CATEGORIES

FNA diagnosis	*Total cases (%)*	*Benign diagnoses*	*Malignant diagnoses*	*NFVPTC diagnoses*	*% ROM*	*% ROM if NFVPTCs nonmalignant*	*% Absolute decrease in ROM*	*% Relative decrease in ROM*
Nondiagnostic	53 (8.1)	43	10	1	18.9	17.0	1.9	10
Benign[a]	167 (25.5)	145	22	13	13.2	5.4	7.8	59
AUS/FLUS[b]	97 (14.8)	59	38	17	39.2	21.6	17.6	45
SFN	88 (13.4)	48	40	7	45.5	37.5	8.0	18
SUS	94 (14.4)	12	82	39	87.2	45.7	41.5	48
POS	156 (23.8)	2	154	8	98.7	93.6	5.1	5
Total	655	309	346	85	52.8	39.8	13.0	25

The table includes the number of benign, malignant, and NFVPTC cases in each FNA diagnostic category, the risk of malignancy (ROM) given the current characterization of NFVPTC as carcinoma, the ROM if NFVPTC was not considered carcinoma, the resulting absolute decrease in ROM, and the resulting relative decrease in ROM.

[a]Referred for surgery because of large nodule size, compressive symptoms or suspicious clinical or sonographic findings.

[b]Referred for surgery because of persistent AUS/FLUS cytology, or suspicious clinical or sonographic findings.

KC Strickland. THYROID 2015;9

W FAQUIN, CANCER CYTOPATHOLOGY,2015

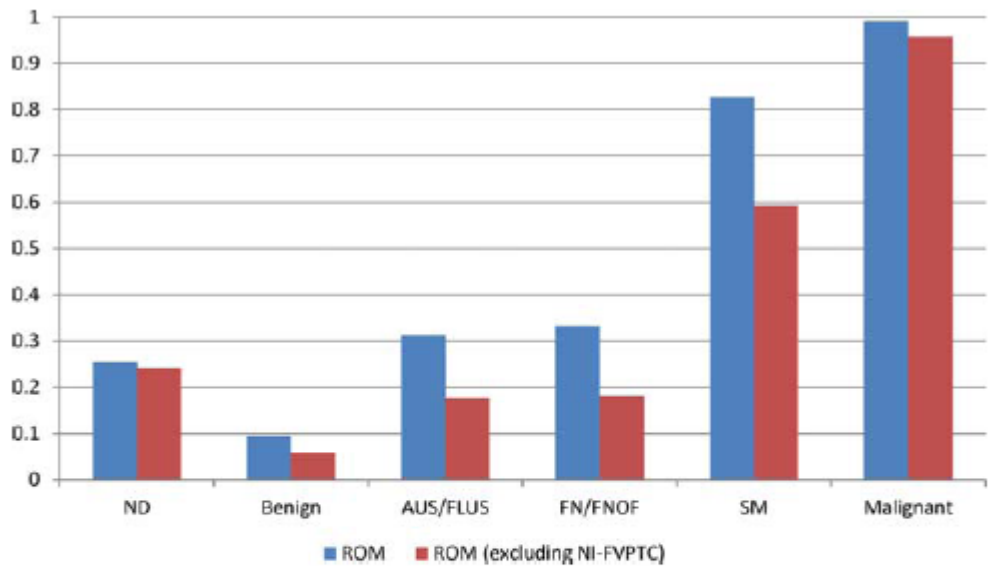

Figure 2. Impact of reclassifying NI-FVPTC on ROM for the categories of The Bethesda System for Reporting Thyroid Cytopathology. AUS/FLUS indicates atypia of undetermined significance/follicular lesion of undetermined significance; FN/FNOF, follicular neoplasm/follicular neoplasm with oncocytic features; ND, nondiagnostic; NI-FVPTC, noninvasive follicular variant of papillary thyroid carcinoma; ROM, risk of malignancy; SM, suspicious for malignancy.

Auteurs	Année	Bénin	ASI	NF	SM	Malin
KC Strickland *Thyroid*	2015	13	18	10	49	7
W Faquin *Cancer Cytopathology*	2015		31 .2	26.6	24.3	
F Maletta *Hum Path*	2016	0	15	56	27	2
T Bizzarro *Cancer Cytopathology*	2016	0	13.5	40.6	35.1	10.8
L Zhao *Cancer Cytopathology*	2017	6	28	26	18	18
HH Wu *JBCM*	2017	17	61	17	4	0
M Pusztaszeri *Cancer Cytopathology*	2017	11.3	7.9	20.6	42.9	6.3

NIFT-P /CATÉGORIE

Catégories indéterminées

Variabilité des résultats

Questions

- **Est-il encore possible de poser un diagnostic de carcinome papillaire?**
- **Est-il possible de diagnostiquer cytologiquement un NIFT-P ?**
- **Est-il possible de distinguer EFVPTC (NIFT-P) et IFVPTC ?**
- **Peut-on s'aider des techniques ancillaires ?**

- **NIFT-P: tumeur indolente à opérer**
- **Eviter la thyroïdectomie totale inutile**

Est-il encore possible de poser un diagnostic de carcinome papillaire?

Coming to Terms With NIFTP: A Provisional Approach for Cytologists

Jeffrey F. Krane, MD, PhD[1]; Erik K. Alexander, MD[2]; Edmund S. Cibas, MD[1]; and Justine A. Barletta, MD[1]

"I have an FNA from a 1.2-cm thyroid nodule that is microfollicular with some nuclear changes of papillary carcinoma; should I call it 'suspicious for a follicular neoplasm' or 'suspicious for malignancy?' Should I mention that this may be NIFTP?"

"My colleagues have decided not to use the malignant category for thyroids because of NIFTP. Can we call anything papillary carcinoma anymore?"

Questions like these have been troubling us and other cytopathologists in recent months. To promote uniform practice, we recently had extensive discussions with our departmental colleagues regarding the "NIFTP conundrum," ultimately leading to the implementation of a new laboratory policy to address the topic. The objective of this Commentary is to share our provisional approach with the cytology community as a practical starting point that others may choose to adopt in their routine practice. We do so with the hope and expectation that this initial attempt will prompt further discussion and research that will ultimately clarify how NIFTP should fit into future thyroid cytology practice.

Critères cytologiques du carcinome papillaire

SUS	Identify a *subset* of cases suspicious for PTC that have microfollicular architecture and lack intranuclear pseudoinclusions, papillae, or psammoma bodies	Note: The overall cytomorphologic features are suggestive of a follicular variant of papillary carcinoma or its recently described indolent counterpart, NIFTP; definitive distinction between these entities is not possible on cytologic material.
Malignant	Limit to cases with frequent pseudoinclusions, papillae, or psammoma bodies along with other cytologic features of PTC (explanatory note is optional)	Note: With the reclassification of some indolent thyroid tumors as NIFTP, the positive predictive value of the malignant category for thyroid FNA is expected to drop from 99% to about 94%-96%; thus, a small proportion of cases interpreted as malignant by FNA may prove to be NIFTP on histologic examination.

- **Howitt et al Am** ***J Clin Pathol 2015; 144:850-7***
- **Strickland et al** ***Thyroid 2016; 26:1466-71***

Critères cytologiques du carcinome papillaire

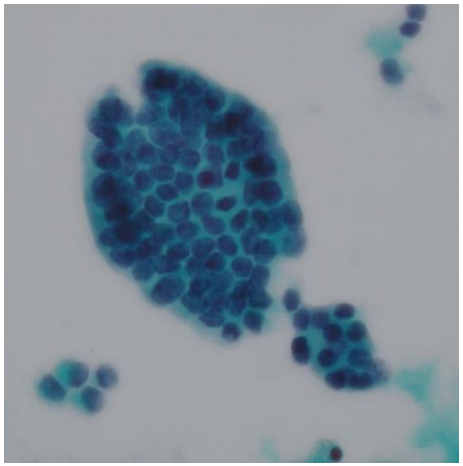

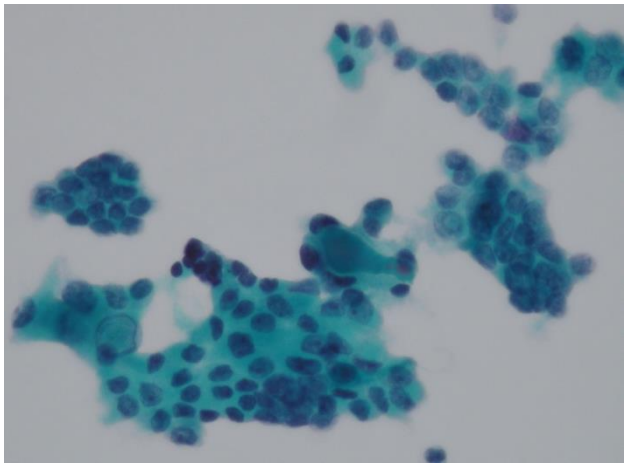

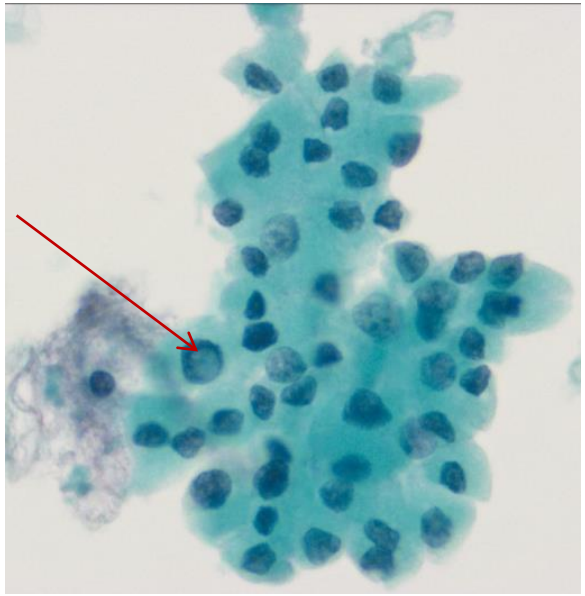

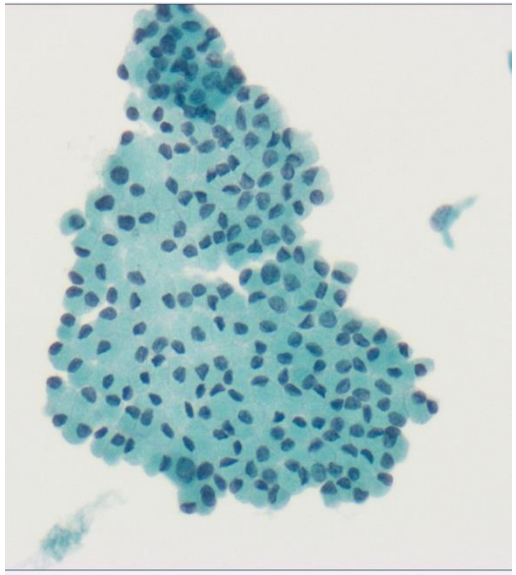

Diagnostic cytologique du NIFT-P ?

Table 2 FNAB cytology parameter assessment in NIFTPs and benign follicular lesions

	NIFTPs	Benign follicular lesions	Fisher exact test *P*
Nuclear enlargement	37/55	14/37	.0098 [a]
Nuclear membrane irregularities	47/55	1/37	.0001 [a]
Optically clear, ground glass nuclei	29/55	1/37	.0001 [a]
Nuclear molding	50/55	20/37	.0001 [a]
Microfollicular pattern only (no macrofollicles)	48/55	10/37	.1037
Colloid	7/55	8/37	.2678
Prominent nucleoli	15/55	17/37	.077
Fibrous tissue	22/55	21/37	.1384
Associated macrophages	12/55	11/37	.4642
Loosely cohesive cellularity	39/55	28/37	.6422
3D clusters of follicular cells	3/55	2/37	1
High cellularity	15/55	10/37	1

NOTE. FNAB cytological features were assessed blindly (with no knowledge of the histological diagnoses) from 55 (of 96) histologically confirmed NIFTPs and 37 benign tumors.

- ***Maletta F, Hum Pathol 2016:134-142***
- ***Strickland KC, Cancer Cytopathology 2017:1-8***

Table 3 Occurrence of the 3 most relevant FNAB cytology parameters in NIFTPs and other lesions

	NIFTPs	Benign follicular lesions	Invasive EFVPTCs
No. of cases	55	37	24
Nuclear size			
Mean	63.8	33.5	66.2
Range	0-100	0-100	0-100
P		.0004 [a]	.78 [b]
Nuclear membrane irregularities			
Mean	69.6	10.3	80
Range	0-100	0-60	30-100
P		<.0001 [a]	.08 [b]
Chromatin clearing			
Mean	53.9	10	55
Range	0-100	0-70	0-100
P		<.0001 [a]	.88 [b]

SCORES

NIFT-P vs Bénin: significatif

NIFT-P vs EFVPTC invasif: Non significatif

SCORES 0-3

Table 4 Correlation between nuclear score and categorization according to the Bethesda System in different tumor types

	Nuclear score (no. of cases)	Categorization according to Bethesda System			
		III [a]	IV [b]	V [c]	VI [d]
NIFTPs (n = 96)	Score 0-1 (22)	12	9	1	0
	Score 2-3 (74)	2	45	25	2
Benign follicular lesions (n = 37)	Score 0-1 (35)	16	19	0	0
	Score 2-3 (2)	1	1	0	0
Invasive EFVPTCs (n = 24)	Score 0-1 (2)	0	2	0	0
	Score 2-3 (22)	0	13	9	0

Table 5 Concordance of scores between FNAB cytology and histology in the whole series of lesions studied

		Histology	
		Score 0-1	Score 2-3
Cytology	Score 0-1	35	24
	Score 2-3	2	96

NOTE. The Cohen κ was 0.62 (95% confidence interval, 0.49-0.74).

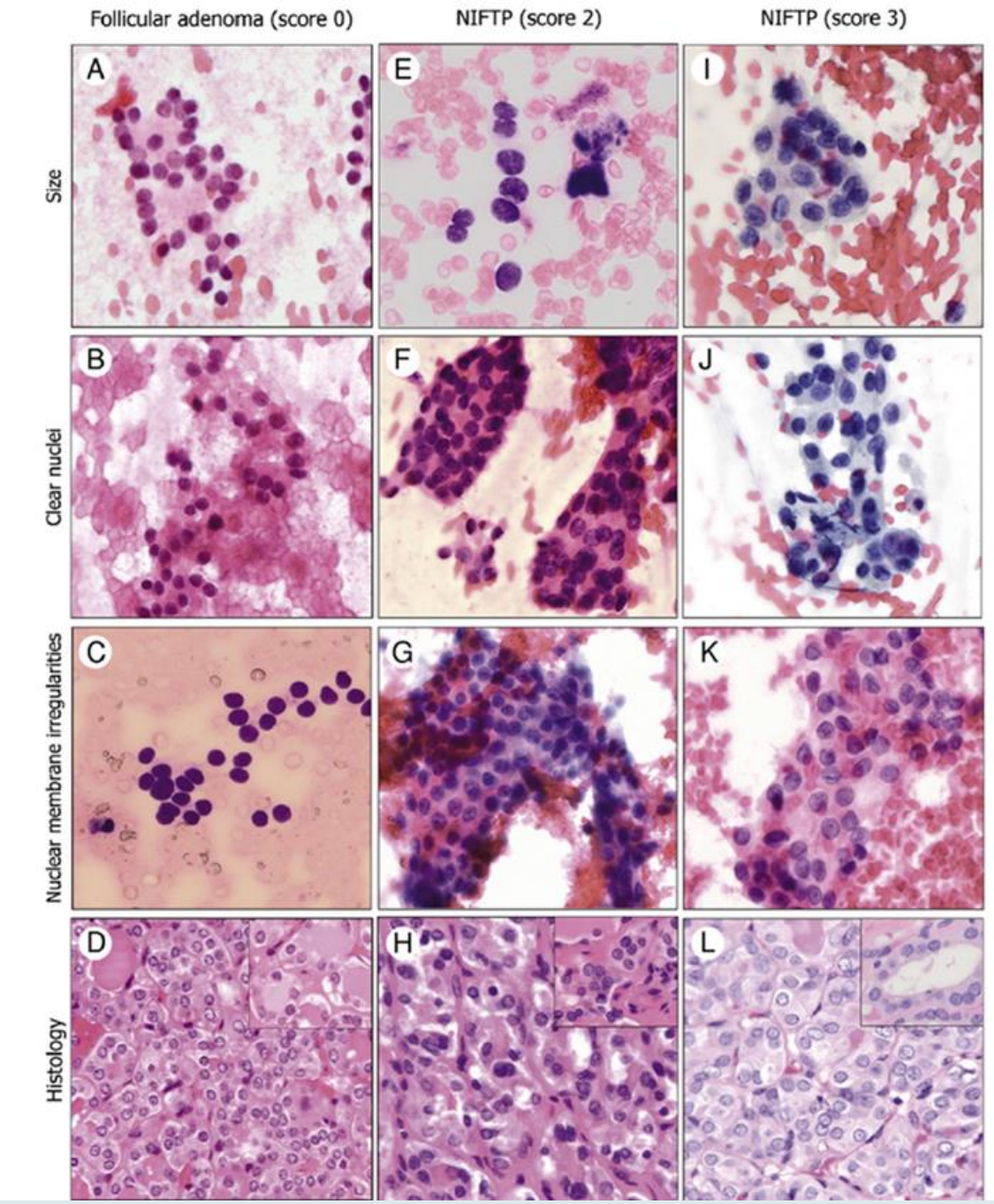

CORRÉLATION CYTOLOGIE HISTOLOGIE

Reproductible ?

Méthodologie complexe

Strickland 2017

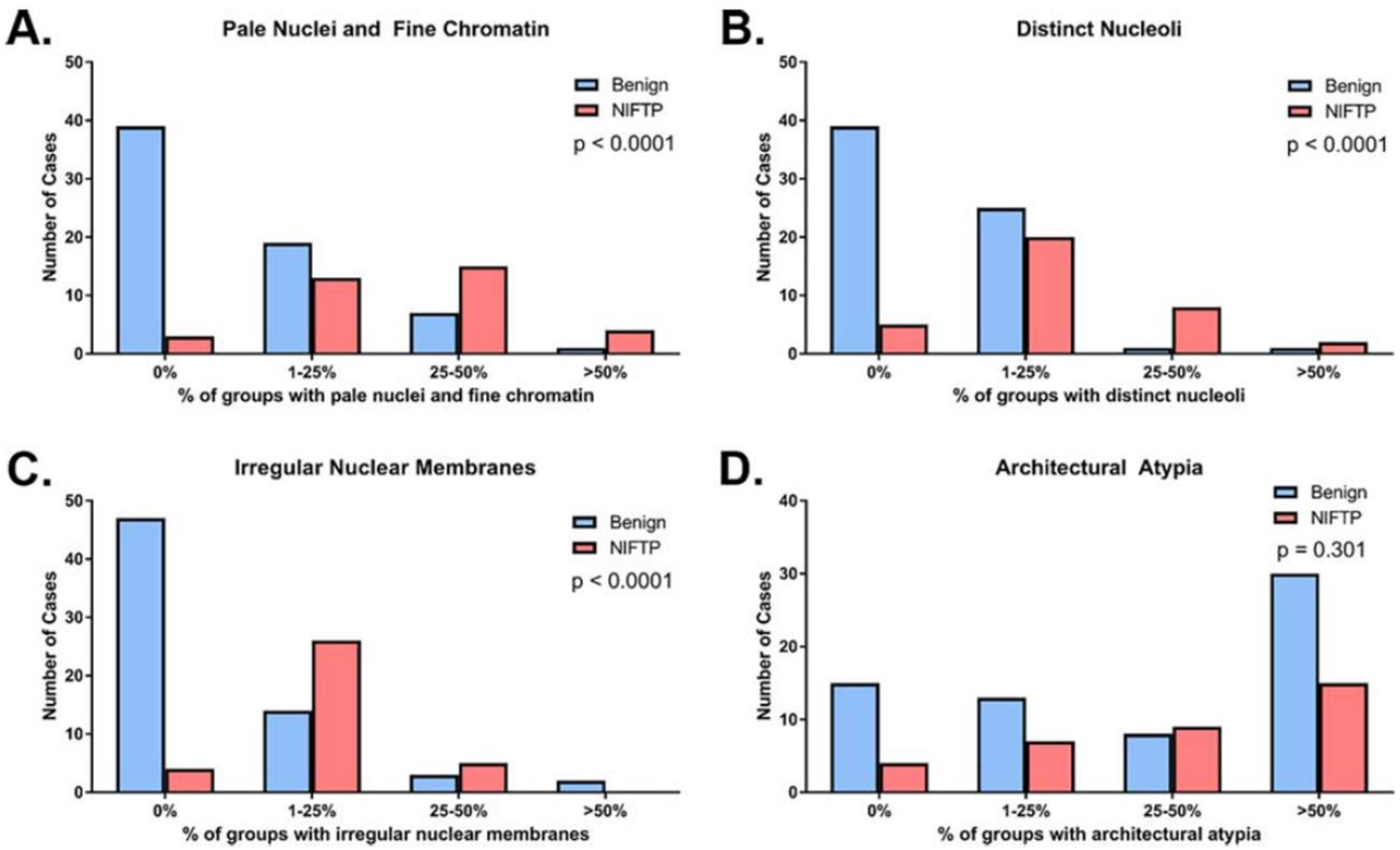

Score ≥2

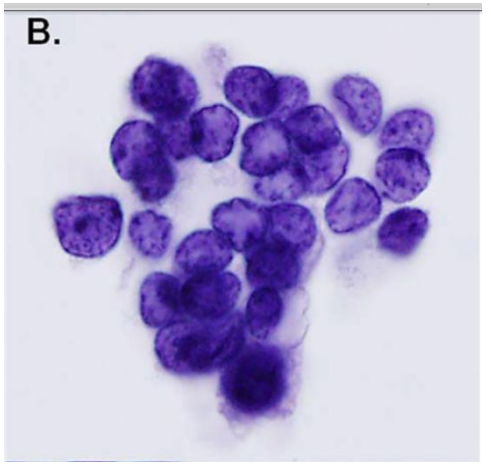

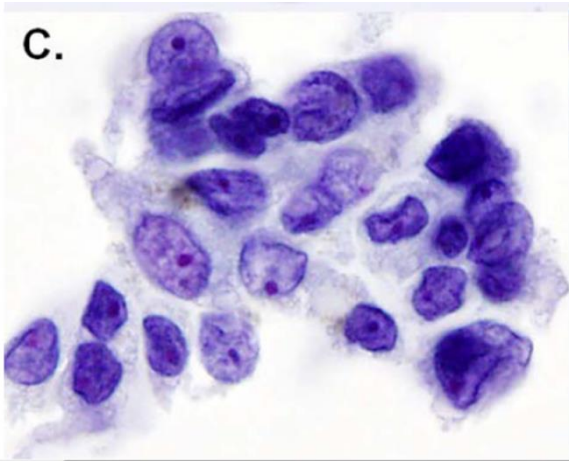

TABLE 2. Nuclear Scores of Each Category of Histologic Diagnosis

	Nuclear Score				
	0	1	2	3	Total
Benign	29 (22%)	14 (11%)	10 (8%)	13 (10%)	66 (51%)
NIFTP	2 (2%)	1 (1%)	4 (3%)	28 (22%)	35 (27%)
Follicular carcinoma	7 (5%)	1 (1%)	0 (0%)	1 (1%)	9 (7%)
IFVPTC	0 (0%)	0 (0%)	3 (2%)	6 (5%)	9 (7%)
Other PTC	0 (0%)	6 (5%)	2 (2%)	3 (2%)	11 (8%)
Total	38 (29%)	22 (17%)	19 (15%)	51 (39%)	130 (100%)

Abbreviations: IFVPTC, invasive/infiltrative follicular variant of papillary thyroid carcinoma; NIFTP, noninvasive follicular thyroid neoplasm with papillary-like nuclear features; PTC, papillary thyroid carcinoma.

NIFT-P

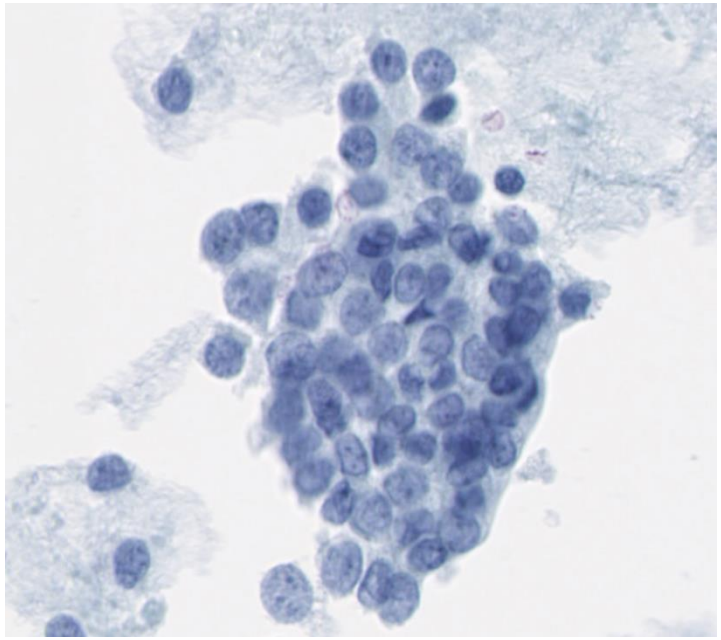

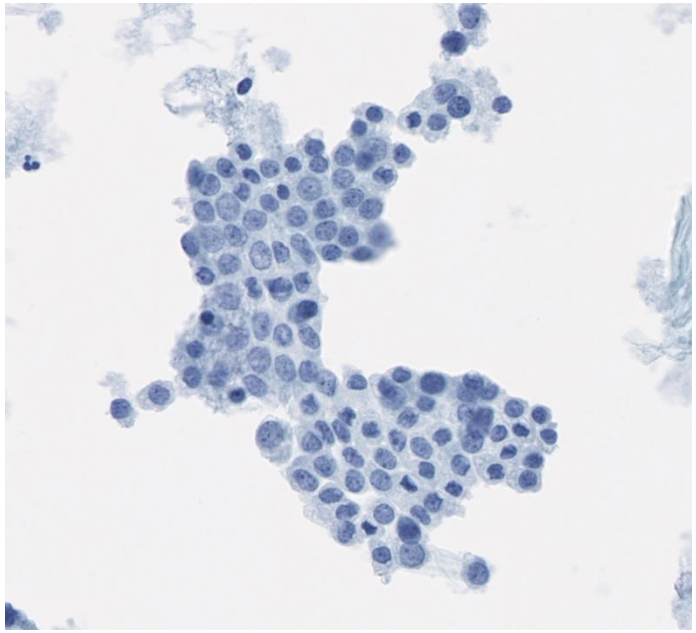

- **NIFT-P vont être classés en NF/Sus**
- **NIFT-P ne sont pas confondus avec des nodules bénins**
- **NIFT-P ne peut-être distingué de IFVPTC**
- ***Diagnostic à évoquer (ne peut être affirmé)***

TECHNIQUES ANCILLAIRES

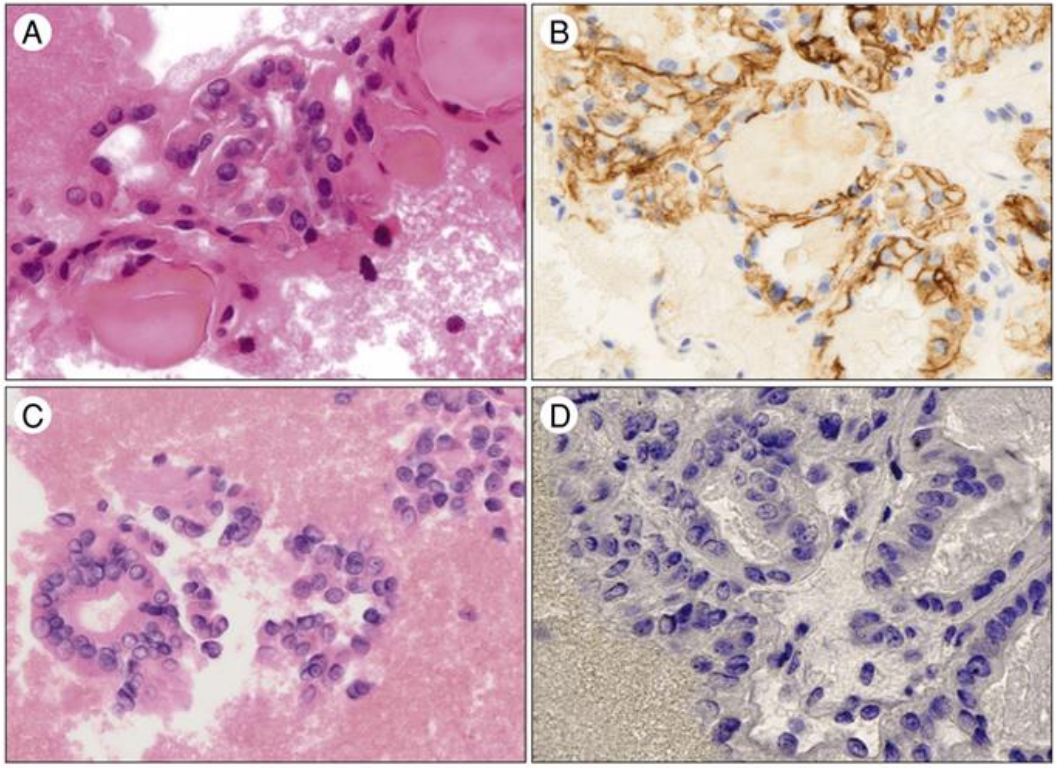

Fig. 2 CD56 immunostaining results in a case of microfollicular goiter (A and B) showing CD56 intense and diffuse membranous positivity (B) and, in a case of NIFTP (C and D), showing a complete loss of expression of CD56 in neoplastic cells. Sections are obtained from cell blocks and stained with H&E (A and C; ×400) and antibodies anti-CD56 (B and D; ×400).

CD56 : diminution ++ ou absence de marquage PTC
Marquage diffus et net dans les lésions bénignes

ICC
CD56

Les techniques ancillaires

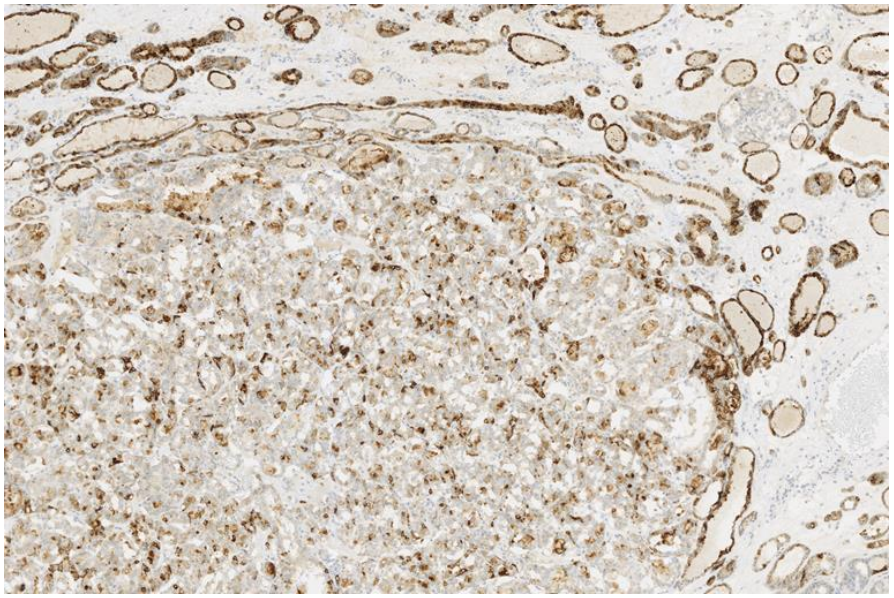

TPO
30%

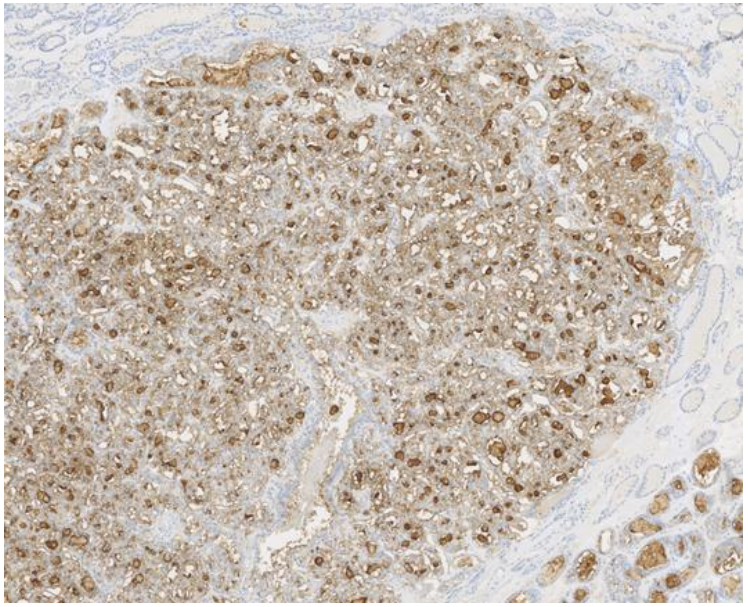

HBME1
50%

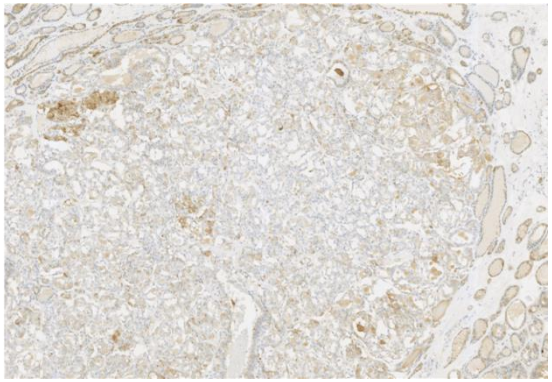

Gal 3:
2%

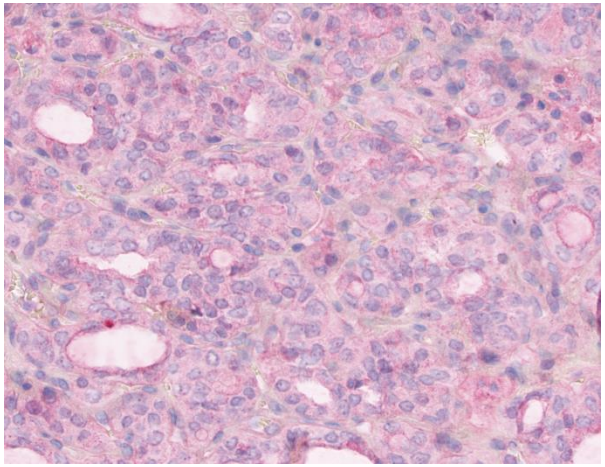

B
R
A
F

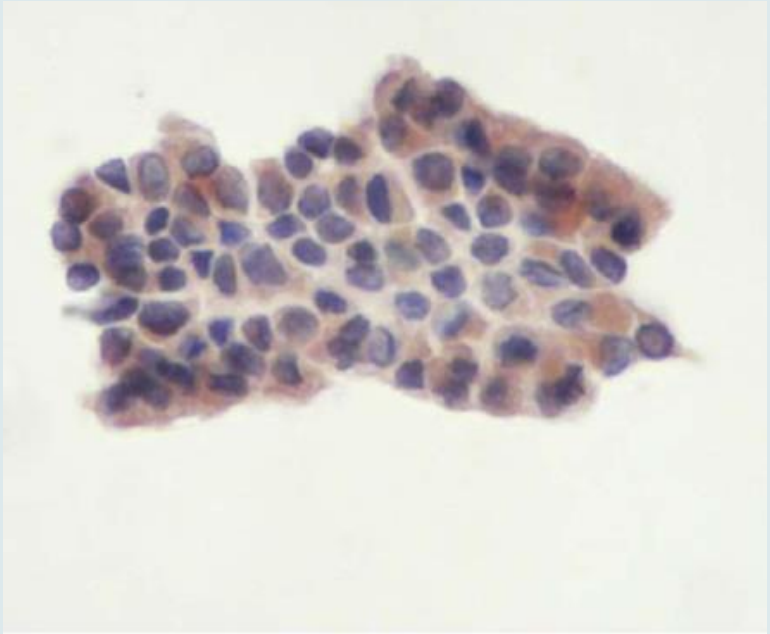

BRAF

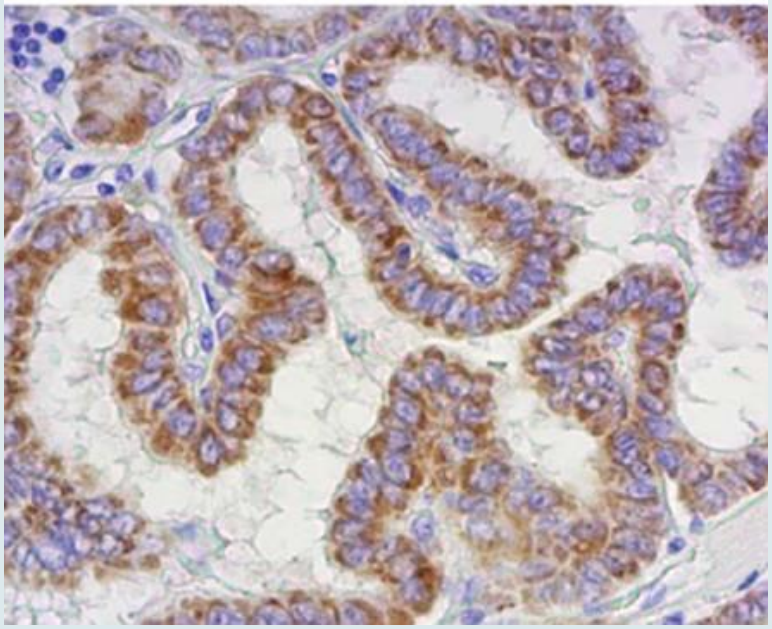

ROSSI ED ET AL
CANCER CYTOPATHOLOGY 2014

Abd Elmageed ZY

Surgery 2017

ICC utilisable

eTable 7. Summary of cases used as a validation set for three-point nuclear scoring scheme

Case Number	Nuclear Score			Total Score (Mean)	Molecular results
	Nuclear size and shape (Mean)	Membrane irregularities (Mean)	Chromatin characteristics (Mean)		
A49	0.91	1.00	0.91	2.82	*THADA* fusion
A157	0.14	0.09	0.05	0.27	NEG
A123	0.82	0.55	0.82	2.18	*PAX8/PPARG*
A124	1.00	0.64	0.95	2.59	*HRAS*
A152	0.14	0.18	0.50	0.82	NEG
A158	0.09	0.09	0.00	0.18	NEG
A145	1.00	0.86	1.00	2.86	*NRAS*
A129	0.82	0.95	0.91	2.68	*THADA* fusion
A153	0.77	0.14	0.00	0.91	NEG
A137	1.00	1.00	0.82	2.82	*PAX8/PPARG*
A138	1.00	0.91	1.00	2.91	*NRAS*
A151	0.05	0.09	0.05	0.18	NEG
A150	0.05	0.00	0.00	0.05	NEG
A140	1.00	0.73	0.77	2.50	*PAX8/PPARG*
A156	0.05	0.05	0.00	0.09	NEG
A141	0.86	0.68	0.95	2.50	*HRAS*
A155	0.18	0.50	0.09	0.77	NEG
A131	0.82	1.00	1.00	2.82	*ALK* fusion
A149	0.50	0.09	0.32	0.91	NEG
A143	1.00	0.50	1.00	2.50	*NRAS*
A154	0.23	0.23	0.09	0.55	NEG
A130	1.00	0.82	1.00	2.82	*THADA* fusion
A146	0.14	0.09	0.23	0.45	NEG
A147	0.45	0.27	0.27	1.00	NEG
A144	0.86	0.86	1.00	2.73	*NRAS*
A148	0.32	0.18	0.23	0.73	NEG

Growth Pattern	Nuclear Features of PTC	Main Oncogene			
Papillary	Yes	*BRAF*	Papillary microcarcinoma	→	Classic PTC
Follicular	Yes	*RAS*	NIFTP	→	Invasive EFVPTC
Follicular	No	*RAS*	Follicular adenoma	→	Follicular thyroid carcinoma

Nikiforov, Endocrine Practice, 2017

Mc Iver et al JCEM 2014

Endocrine Care

An Independent Study of a Gene Expression Classifier (Afirma™) in the Evaluation of Cytologically Indeterminate Thyroid Nodules

Sensibilité : 80%
Specificité: 12%
VPN:75%

2012 ATA
50% de résultats corrects pour les indéterminés

TABLE 3. Performance of the GEC Before and After Reclassification of NIFPT in the AUS and SFN Groups

AUS (Before NIFTP)			AUS (After NIFTP)		
	Histopathologic Diagnosis			Histopathologic Diagnosis	
GEC Result	Malignant	Benign	GEC Result	Malignant	Benign
Suspicious	47	65	Suspicious	27	85
Benign	0	21	Benign	0	21
Sensitivity: 100% (95% CI, 92%-100%)			Sensitivity: 100% (95% CI, 87%-100%)		
Specificity: 24% (95% CI, 16%-35%)			Specificity: 20% (95% CI, 13%-29%)		
PPV: 42% (95% CI, 39%-45%)			PPV: 24% (95% CI, 22%-26%)		
NPV: 100%			NPV: 100%		
Prevalence of malignancy: 35% (95% CI, 27%-44%)			Prevalence of malignancy: 20% (95% CI, 14%-28%)		

SFN (Before NIFTP)			SFN (After NIFTP)		
	Histopathologic Diagnosis			Histopathologic Diagnosis	
GEC Result	Malignant	Benign	GEC Result	Malignant	Benign
Suspicious	9	30	Suspicious	5	34
Benign	1	2	Benign	1	2
Sensitivity: 90% (95% CI, 56%-100%)			Sensitivity: 83% (95% CI, 36%-100%)		
Specificity: 6% (95% CI, 1%-21%)			Specificity: 6% (95% CI, 1%-19%)		
PPV: 23% (95% CI, 19%-27%)			PPV: 13% (95% CI, 9%-18%)		
NPV: 67% (95% CI, 17%-95%)			NPV: 67% (95% CI, 17%-95%)		
Prevalence of malignancy: 24% (95% CI, 12%-39%)			Prevalence of malignancy: 14% (95% CI, 5%-29%)		

Abbreviations: 95% CI, 95% confidence interval; AUS, atypia of undetermined significance; GEC, gene expression classifier; NIFPT, noninvasive follicular thyroid neoplasm with papillary-like nuclear features; NPV, negative predictive value; PPV, positive predictive value; SFN, suspicious for a follicular neoplasm.

Hang JF Cancer Cytopathology 2017

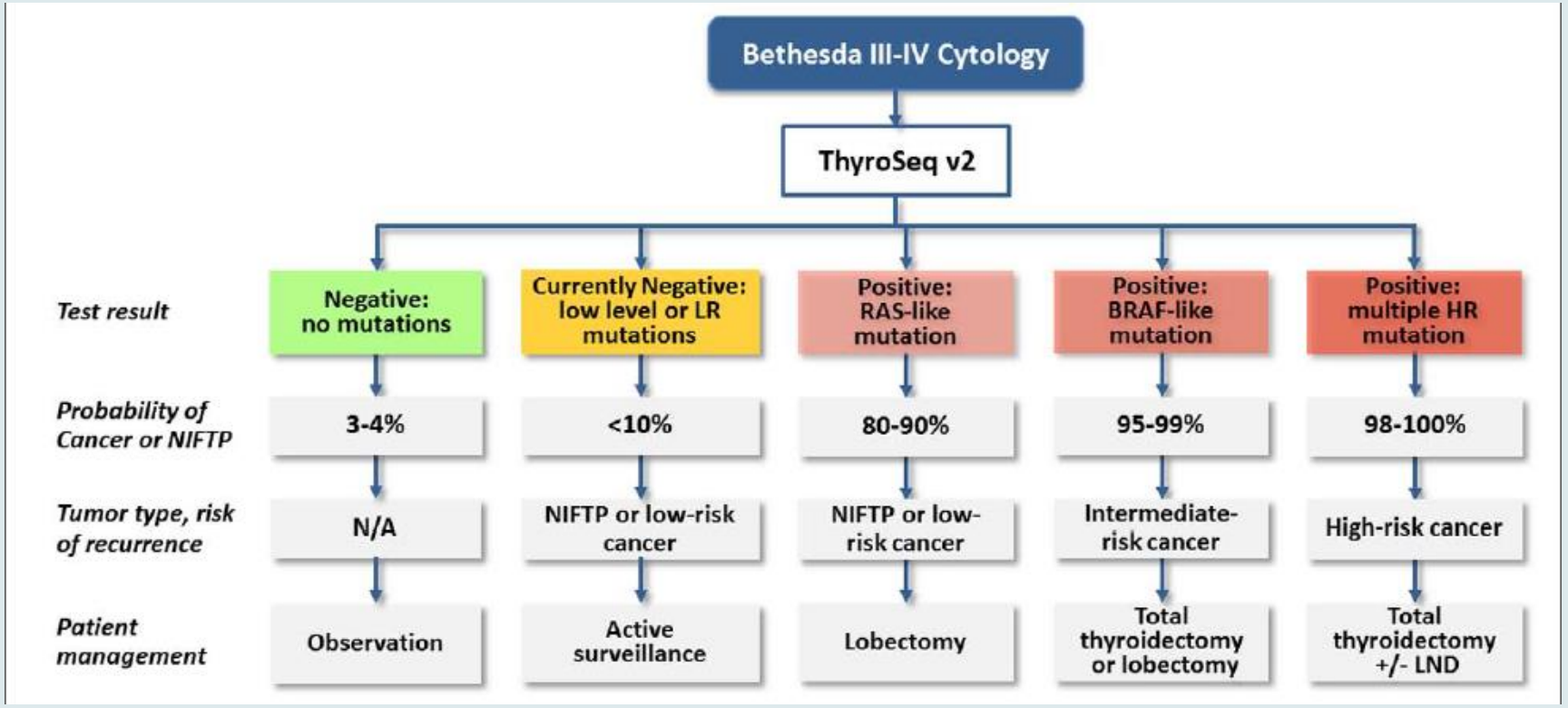

ThyroSeq v2 : panel multi-genes spécifique thyroide: BRAF; 3 RAS; 7-gene panel; TP53, TERT, RET;
Gènes de fusion(RET/PTC1, RET/PTC3, and PAX8-PPARG); Gènes d'expression de la Calcitonine (CALCA) and Parathyroid Hormone (PTH)

Questions/réponses

- **Est-il encore possible de poser un diagnostic de carcinome papillaire? OUI**
- **Est-il possible de diagnostiquer cytologiquement un NIFT-P ? Possible de l'évoquer NF/SM**
- **Est-il possible de distinguer EFVPTC (NIFT-P) et IFVPTC ? non**
- **Peut-on s'aider des techniques ancillaires ? Oui BM**

- **Eviter la thyroïdectomie totale inutile**

BETHESDA 2017

TABLE 2. THE 2017 BETHESDA SYSTEM FOR REPORTING THYROID CYTOPATHOLOGY: IMPLIED RISK OF MALIGNANCY AND RECOMMENDED CLINICAL MANAGEMENT

Diagnostic category	*Risk of malignancy if NIFTP ≠ CA (%)*	*Risk of malignancy if NIFTP = CA (%)*	*Usual management*[a]
Nondiagnostic or unsatisfactory	5–10	5–10	Repeat FNA with ultrasound guidance
Benign	0–3	0–3	Clinical and sonographic follow up
Atypia of undetermined significance or follicular lesion of undetermined significance	6–18	~10–30	Repeat FNA, molecular testing, or lobectomy
Follicular neoplasm or suspicious for a follicular neoplasm	10–40	25–40	Molecular testing, lobectomy
Suspicious for malignancy	45–60	50–75	Near-total thyroidectomy or lobectomy[b,c]
Malignant	94–96	97–99	Near-total thyroidectomy or lobectomy[c]

Les aspects cytologiques peuvent faire suspecter un carcinome papillaire d'architecture vésiculaire. en incluant le NIFT-P.

Thyroid 2017;11:1341-46

MESSAGES À RETENIR

- **NIFT-P est une révolution pour la communauté médicale et les patients**
- **Met en évidence et explique la mauvaise reproductibilité diagnostique inter-observateurs en pathologie et en cytopathologie**
- **Va permettre de recalibrer nos critères diagnostiques en histologie et en cytologie**
- **Permet de mieux comprendre la biologie moléculaire qui devient une aide au diagnostic et à la décision thérapeutique**
- **Rend nécessaire la concertation multidisciplinaire /radiologues/EU-Tirads**

May, 2016: Yokohama Symposium on the TBSRTC

-
  - Bill Faquin (USA)
  - Marc Pusztaszeri (Switzerland)
  - Esther Diana Rossi (Italy)
-
  - Manon Auger (Canada)
  - Zubair Baloch (USA)
  - Justin Bishop (USA)
  - Massimo Bongiovanni (Switzerland)
  - Ashish Chandra (UK)
  - Beatrix Cochand-Priollet (France)
  - Guido Fadda (Italy)
  - M. Hirokawa (Japan)
  - Soonwon Hong (Korea)
  - Kennichi Kakudo (Japan)
  - Jeffrey Krane (USA)
  - Ritu Nayar (USA)
  - Sareh Parangi (USA)
  - Fernando Schmidt (Luxembourg)